

Pilonidal sinus minimal excision with primary closure: 9 years' experience

Ehab M. Oraby, Mokhtar A. Bahbah

Department of General Surgery, Benha Faculty of Medicine, Benha, Egypt

Correspondence to Ehab M. Oraby, MD, Department of General Surgery, Benha Faculty of Medicine, Benha University, Fareed Nada Street, Benha, 44755, Egypt. Tel: +20 100 378 3425; fax: +20 100 322 5509; e-mail: ehab.arabi@fmed.bu.edu.eg, ehaboraby2000@gmail.com, ehaborabyy@gmail.com

Received: 5 July 2021

Accepted: 24 July 2021

Published: xx xx 2020

The Egyptian Journal of Surgery 2021, 40:1251–1256

Introduction

Pilonidal sinus (PNS) disease is distributed in young adults who are supposed to be healthy with maximum productivity. Wide local excision creates a tissue gap, while the concept of minimal excision preserves healthy tissues with minimal tissue gap.

Objectives

The aim of the study was to evaluate the efficiency of minimal excision technique after 9 years of experience.

Patients and methods

This retrospective study involved 205 consecutive patients with sacrococcygeal PNS. All patients were treated surgically with minimal excision and primary closure. Follow-up included wound seroma, infection, or disruption, in addition to sick leave and PNS recurrence.

Results

PNS minimal excision was performed on 205 patients. The mean operative time was 33 min. The hospital stay ranged from 7 to 12 h. Healing time was 12–22 days. Time to remove the drain 4–7 days. Seroma developed in 4.39%, simple wound infection 6.8%, significant wound infection 2.9%, and recurrence in 1.46%. Patients with recurrence shared the criteria of being obese with deep clefts and poor hygiene.

Conclusion

Minimal excision and primary closure is a safe and easy operative procedure, applicable to primary, recurrent, and complex branched cases with good results in wound healing and low recurrence rate.

Keywords:

less is more, minimal excision, pilonidal sinus, primary closure

Egyptian J Surgery 40:1251–1256
© 2021 The Egyptian Journal of Surgery
1110-1121

Introduction

Two centuries ago, Mayo described this disease for the first time with thoughts of congenital origin [1]. Then after about 50 years, Hodges carved out the term 'pilonidal sinus' (PNS) from Latin words with different thoughts of being acquired pathology [2].

PNS disease is getting its importance from its pattern of distribution in young adults with negative disabling impact on the category of people supposed to be healthy with maximum productivity [1–3].

Surgeons' society believe that disease with much controversy in treatment, is still lacking the ideal treatment. This ideal solution should be simple, no prolonged hospitalization, has low recurrence rate, less pain, does not need prolonged professional wound care, and rapid return to usual daily activity [4].

Over two centuries, surgeons handled this disease with different strategies varying from simple procedures such as shaving and personal hygiene passing

through sophisticated techniques such as flap reconstruction and recently endoscopic and laser ablation [1–3,5].

Wide local excision creates a tissue gap that needs a reconstruction to obtain tension-free wound closure. On the other hand, the concept of minimal excision was built on preservation of healthy tissues with minimal tissue gap [4].

Over the last 9 years, the authors practised the procedure of minimal excision of PNS on plenty of cases. In the early phase, this technique was limited to primary simple cases of PNS. With accumulation of experience, the authors refined the technique with wider application over recurrent and more complex cases (Fig. 1).

This is an open access journal, and articles are distributed under the terms of the Creative Commons Attribution-NonCommercial-ShareAlike 4.0 License, which allows others to remix, tweak, and build upon the work non-commercially, as long as appropriate credit is given and the new creations are licensed under the identical terms.

Patients and methods

This retrospective study was conducted at the Department of General Surgery, Benha University Hospital, after obtaining approval from the local ethical committee and after fully informed written consent signed by the patient. This study was carried out on 205 consecutive patients: 173 patients with primary disease and 32 cases with recurrent sacrococcygeal PNS from June 2012 to March 2021.

Patient data (age, sex, and complaint) were recorded. Criteria of sinus pits (number, site, midline, or lateral), hospital stay, and postoperative outcome also were noted.

Mean age at presentation was 21.3 years (16–39 years). There were 161 male and 44 female patients.

All patients had midline pits, and only 19 patients had additional lateral sinus pits reflecting the branched criteria of the PNS tract. The technique of minimal excision was applied for all cases.

Technique

Preoperative prophylactic antibiotic (Ceftriaxone 1-g vial) was given routinely to all cases. Prone jackknife position was selected for exposure of sacrococcygeal area. Furthermore, natal cleft was opened by using traction plaster to pull the buttocks apart. Field preparation was accomplished by hair clipping and then skin sterilization by Povidone iodine 10% antiseptic solution.

In early cases of this series, perilesional adrenaline injection was used to blanch the surrounding tissues, which offers easy identification of the sinus tract. This step has no longer been used after gaining experience in perilesional meticulous dissection.

Careful palpation in the sacrococcygeal area is an important step to detect any induration, especially with branched tracks to get ready for tracking these branches.

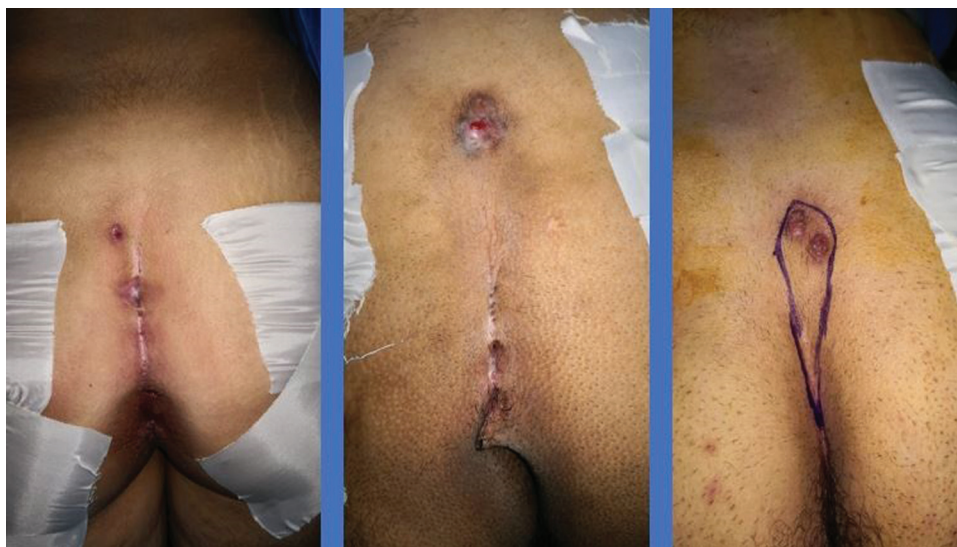The authors believe that methylene blue injection into the sinus tract may be a misleading step as it can diffuse out of the tract wall and stain healthy tissues. Instead, we depended on glistening color of the tract wall.

Surgical incision has a special design (Figs 2 and 3). The uppermost point was sited 2 cm above the uppermost pit. The lowermost point was sited 0.5 cm below the lowermost pit. Any lateral pit was enclosed within a V-cut incision. Narrow elliptical incision was created passing through previous points and curving 0.5 cm away from midline.

The concept of minimal excision is not only a bidimensional concept. It involves also the third dimension, wound depth. In this technique, the wound was not deepened more than 1–1.5 cm and then progressing medially to do dissection just outside the fibrotic wall of the tract (Fig. 4).

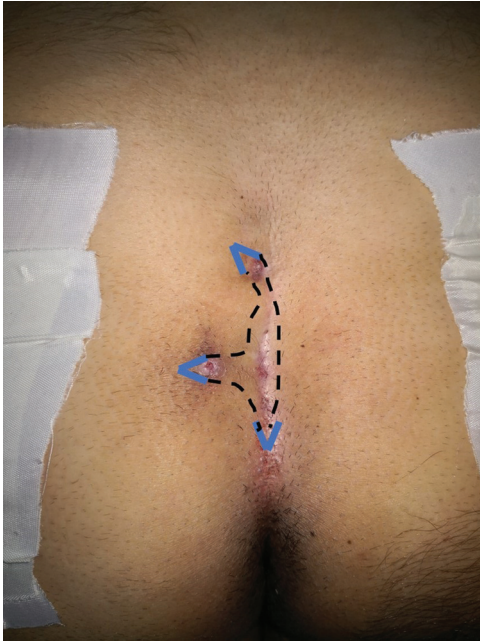
After tract excision, wound irrigation and hemostasis were done, and then traction plaster was released. The wound edges came together without tension.

Figure 1



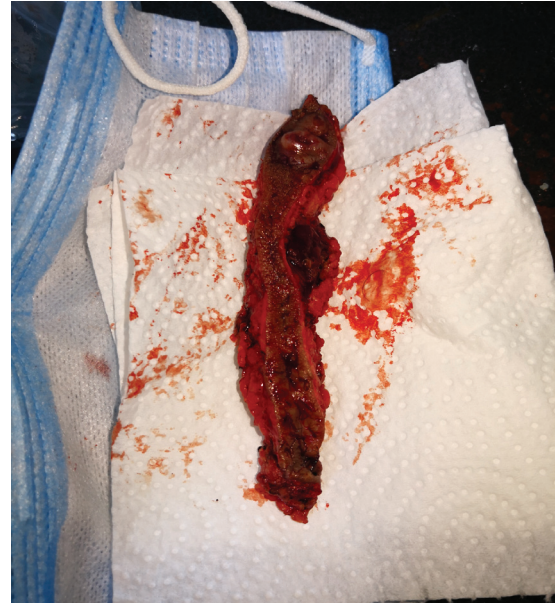Varieties of PNS (original). PNS, pilonidal sinus.

Figure 2



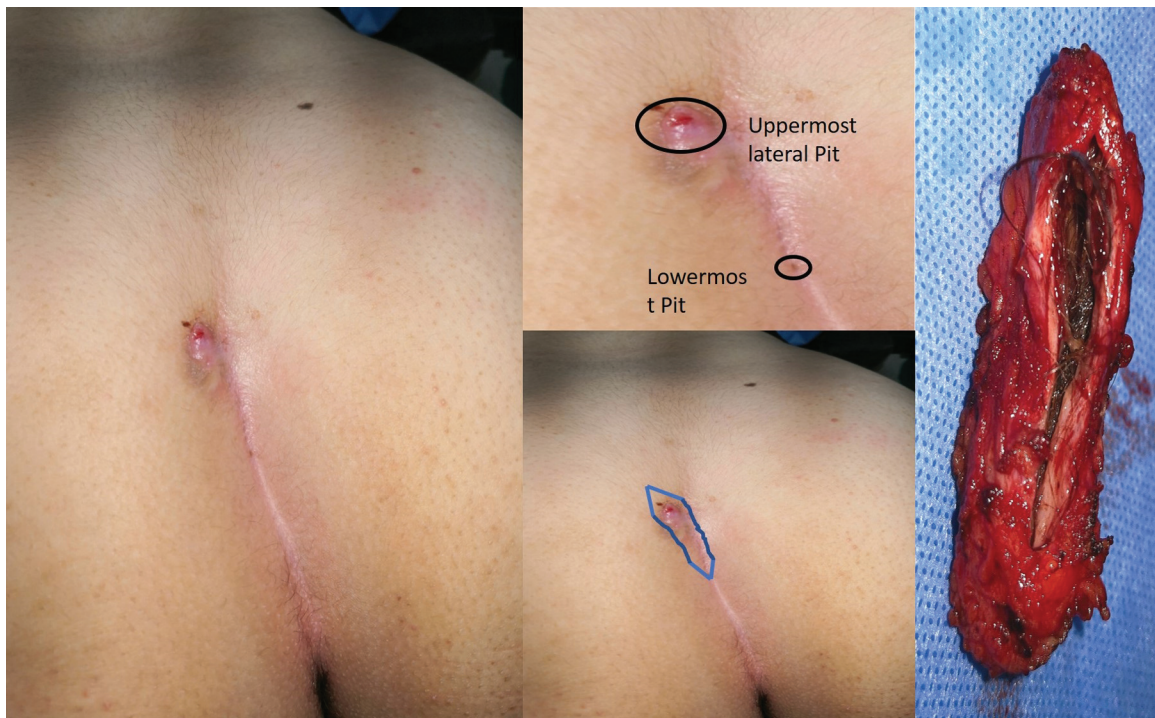
Incision line (original).

Figure 4



Minimally excised PNS track (original). PNS, pilonidal sinus.

Figure 3



Design of incision line (original).

Undermining of the wound edges was done creating a thick flap starting from the wound floor and passing laterally for about 2 cm. After insertion of subcutaneous suction drain, 2–3 deep Vicryl stitches were taken between subcutaneous fat on both sides and fixed to

the wound floor to close the dead space. Skin closure was completed by 3/0 interrupted prolene stitches.

Postoperative predischarge instructions to avoid prolonged sitting and riding a bicycle for 6 weeks,

and to improve local hygiene and regular hair shaving, clipping, or using depilatory creams.

The patient was discharged 6–8 h after the operation. Follow-up visits were scheduled at third, seventh, and 14th days, and then 1, 3, and 6 months postoperatively.

The wound was routinely exposed after 72 h to combat anaerobic environment. Patients with heavy buttocks need a reversed plaster trick to pull the buttocks away from the cleft wound.

In the follow-up visits, wound seroma, wound infection and/or disruption, pain, off work time, and sinus recurrence were noted.

Results

Minimal excision of PNS was performed on 205 patients, 161 men and 44 women. The mean age was 21.3 years (16–39 years) (Table 1).

In this study, 143 (69.7%) patients complained of pain, 75 (36.5%) patients with intermittent discharge, and 14 (6.8%) patients with previous pilonidal abscess and drainage.

The mean operative time was 33 min (range, 23–42 min). The duration of hospital stay ranged from 7 to 12 h. Healing time was 12–22 days. Time to remove the drain 4–7 days. Five (2.4%) cases developed wound seroma after drain removal, which was treated with repeated needle aspiration. Fourteen (6.8%) patients developed simple wound infection, treated with repeated dressing. Six (2.9%) patients presented with significant wound infection and

Table 1 Demographic data (original)

Variables	n (%)
Sex	
Male	161 (78.5)
Female	44 (21.5)
Age	
Range	16–39
Mean±SD	21.3±8.3
BMI	
Range	24.1–44.1
Mean±SD	30.2±5.1
Symptoms	
Pain	143 (69.7)
Discharge	75 (36.5)
Abscess	14 (6.8)
Primary PNS	173 (84.4)
Recurrent PNS	32 (15.6)

PNS, pilonidal sinus.

wound disruption. The wound was curetted and left open to heal by secondary intention. One case with simple stitch infection was treated with removal of infected stitch. Infection subsided, but this patient showed a visible pit, which failed to heal, except after curettage. In this series, we had three (1.4%) cases with recurrent PNS. Patients with recurrence shared the criteria of being obese with deep clefts and poor hygiene (Table 2).

Discussion

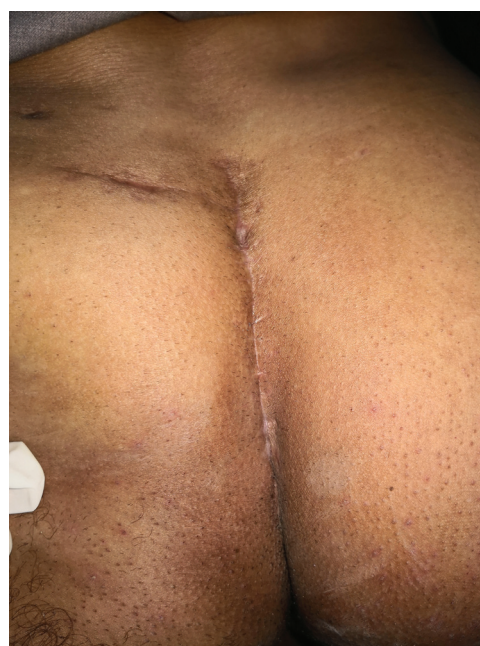The poet Robert Browning wrote 'less is more' in his poem 'The Faultless Painter,' which was published in 1855 [6]. This phrase became a concept that was expanded to cover many participants.

The minimalist concept in surgery raised the era of minimal invasive surgery. Soll *et al.* [7] used this proverb for the first time to describe their novel sinusectomy technique in treating PNS.

Table 2 Postoperative data (original)

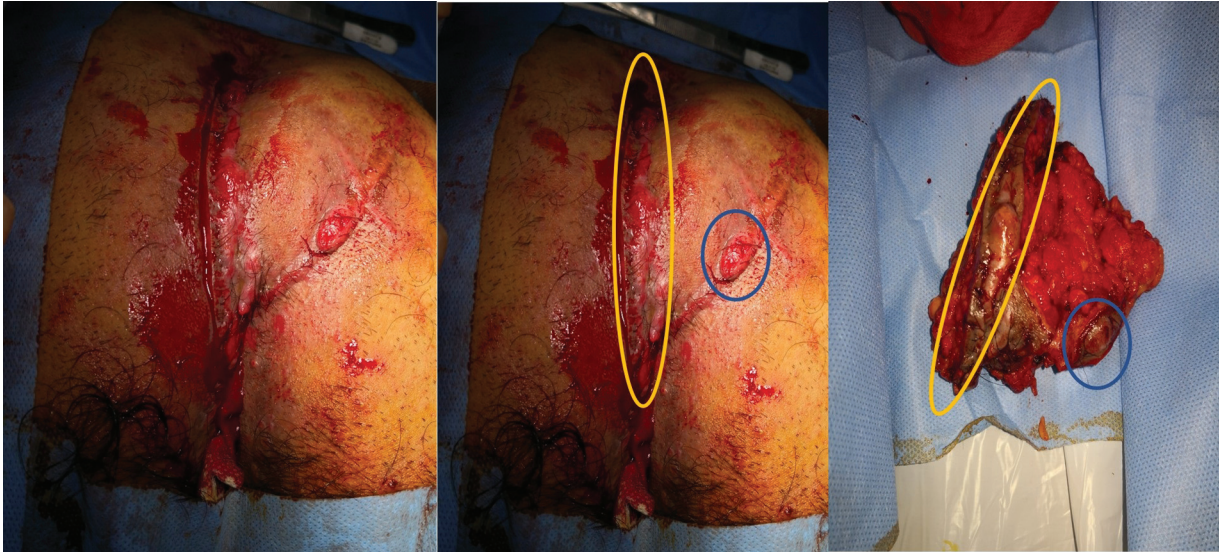Operative time	33 min (23–42)
Hospital stay	8.1 h (7–12)
Healing time	14.3 days (12–22)
Drain removal	4.3 days (4–7)
Wound seroma	9 patients (4.39)
Simple infection	14 cases (6.8)
Significant infection	6 cases (2.9)
Disruption	6 cases (2.9)
Recurrence	3 cases (1.46)

Figure 5



Healed wound with primary intention (original).

Figure 6



Recurrent PNS after rhomboid-flap reconstruction (original). PNS, pilonidal sinus.

In this study, the authors applied this concept from a different perspective. Plenty of cases along 9 years, configured refinement of the previously described technique [4].

Omission of the step of perilesional adrenaline injection had no impact on the track delineation with meticulous dissection and judicious use of diathermy to provide a bloodless field.

Lateral wound margins found to be of limited mobility due to the underlying subcutaneous fibrofatty tissues, so undermining of thicker lateral flaps for about 2 cm can abolish any tension during wound closure. Tension-free wound closure improves wound healing and decreases pain.

Early cases in this series developed seroma in 10% of cases [4]. In these cases, the authors did not use a subcutaneous drain. Modification of this step involved adding 2–3 deep stitches to close the dead space and inserting a SC suction drain. After this modification, a seroma was collected in 4.39% of cases after drain removal. These cases were treated by repeated wide-pore needle aspiration. Primary wound healing occurred in 90.2% of cases (Fig. 5). While minor wound complications such as superficial infection occurred in 6.8%. Significant wound infection and disruption in 2.9%. Recurrence occurred in 1.46% of cases.

A recent systematic meta-analysis included 13 studies ($n=1145$) of limited excision after deroofting technique

and showed that the technique is effective with a recurrence rate of 4.47% [8].

The other three techniques were designed to minimally excise the PNS disease. Lord and Millar/Gips technique, Bascom technique, and Soll technique published recurrence rates of 25, 24–29, and 7%, respectively [9].

Hussein [10] reported the results of his study that involved minimal excision with simple primary closure. The study declared that hospital stay was 3 days, healing time 14 ± 2.2 days, time off work 16.42 ± 4.45 days, wound infection 17%, wound seroma 9%, and recurrence rate 12%.

In this study, the authors expanded the technique to involve 32 cases with recurrent PNS. These cases showed no difference, except with a little bit tough tissues and more fibrosis, but the authors did not detect differences in wound healing and other complications.

One case of recurrent PNS was reported after rhomboid-flap reconstruction in the first operation (Fig. 6). Minimal excision principle was applicable in this case, but the authors found it better to leave the wound open after excision due to dense contamination and poor patient hygiene.

Conclusion

Minimal excision of PNS after technique refinement, brings us closer to get a simple procedure with little pain, rapid recovery, and rapid return to work with

comparable good results. It helps us to get closer to ideal treatment.

Financial support and sponsorship

Nil.

Conflicts of interest

There are no conflicts of interest.

References

- 1 Kober MM, Alapati U, Khachemoune A. Treatment options for pilonidal sinus. *Cutis* 2018; 102:E23–E29.
- 2 Mahmood F, Hussain A, Akingboye A. Pilonidal sinus disease: review of current practice and prospects for endoscopic treatment. *Ann Med Surg* 2020; 57:212–217.
- 3 Aly Khalil A, Elshawy M, Elbarbary M, Elghamrini Y, *et al.* Closed technique with suction drain versus partial closure technique in midline repair of pilonidal sinus: a comparative study. *Open Access Surg* 2021; 14:21–27.
- 4 Elgohary H, Oraby E. Pilonidal sinus: minimal excision and primary closure under local anesthesia. *Egypt J Surg* 2015; 34:287.
- 5 Velotti N, Manigrasso M, Di Lauro K, Araimo E, Calculli F, Vertaldi S, *et al.* Minimally invasive pilonidal sinus treatment: a narrative review. *Open Med* 2019; 14:532–536.
- 6 'Less is more' – origin, meaning and explanation – ImportantIndia.com Available at: <https://importantindia.com/23849/less-is-more/>. (Accessed on January, 2021).
- 7 Soll C, Hahnloser D, Dindo D, Clavien P, Hetzer F, *et al.* A novel approach for treatment of sacrococcygeal pilonidal sinus: less is more. *Int J Colorectal Dis* 2008; 23:177–180.
- 8 Lim J, Shabbir J. Pilonidal sinus disease-a literature review. *World J Surg Surg Res* 2019; 2:1117.
- 9 Andersson RE. Less invasive pilonidal sinus surgical procedures. *Coloproctology* 2019; 41:117–120.
- 10 Hussein AA. The outcome of opened method versus closed method of chronic Pilonidal Sinus (PNS) AT- Baquba Teaching Hospital. *Int J Adv Res Biol Sci* 2018; 5:46–53.