

## OPTIMIZATION OF ONE STAGE REPAIR OF HYPOSPADIAS.

By

A. Moatamed, M.D\*, I.E. Dawoud, M.D\*, A. M. Ali\*, M.D, T. Badrawy, M.D\*\*, H. Sharaf Eldin\*\*, M. D M.Y. El Gindy, M.D\* and I. Eraky, M.D\*\*\*.

Departments of General surgery\*, Pediatric surgery Unit\*\*, Urology and Nephrology centre\*\*\*, Faculty of Medicine, Mansoura University, Egypt.

*Even in the most experienced hands, hypospadias repair in one stage is a challenging issue. The aim of the study was to optimize one stage repair for all types of hypospadias and to report on short-and mid-term results. It was done on 112 patients with different types of hypospadias, their ages was ranged between 2 - 14 years with a mean age of 3.7 years. For distal, mid, and proximal penile types, urethra was reconstructed using Duplay tube, intervening layer from the Dartos fascia. For the peno-scrotal type, the urethra was created using onlay island flap from the prepuce and covered by a layer from the tunica vaginalis. Suprapubic and urethral drainage were used in proximal-penile and peno- scrotal varieties while urethral drainage only was used in distal, and mid, penile types. The incidence of fistula formation was as follows: 0% in distal penile, 3.5% in mid-penile, 9% in proximal penile and 17% in peno-scrotal type. Due to low incidence of complications of one stage repair for all types of hypospadias we recommend it, provided selection of the proper technique for the proper anomaly*

*keywords : Hypospadias-one stage repair- optimization.*

### INTRODUCTION

The incidence of hypospadias is about 1 in 125 live male births with increasing incidence. Elements of hypospadias anatomy are: meatal dystopia, skin deficiency, penile curvature (chordae). due to deficient corpus spongiosum, skin deficiency, dartos fascia deficiency, a true fibrous chordae with tethering of the ventral shaft or deficiency of the corpora cavernosa on the concave side of the penis.<sup>(1)</sup> Undescended testis and inguinal hernia are the most common associated anomalies while urinary tract anomalies are infrequent. <sup>(2)</sup>,

The aim of hypospadias treatment is reconstruction of a straight penis with a meatus at its tip, uniform calibre urethra, a forward directed stream, a symmetry between the glans and shaft and lasty normal coitus with accepted cosmetic appearance. <sup>(3)</sup>

Although over 200 types of repairs are in use for treatment, a small number can be used as a single stage repair for all types of hypospadias. Repair of hypospadias in one stage, whatever the type, is a challenging issue,

despite of, there is a recent shift to it over the past 10 years.<sup>(4)</sup> The staged repair has the following disadvantages: Operating in a scarred tissue, more anaesthesia and the saline erection test at the root of the penis after degloving solves the problem of chordoe. Despite this diversity of operative techniques. Hypospadiology is still not without new evolutions, new insights and controversies <sup>(5)</sup>.

#### Aim of the study

Was to optimize one stage repair for all types of hypospadias as regard the complications rate, and to report on short (one year) and mid-term (six year) cosmetic and functional results.

### PATIENTS AND METHODS

The study was performed on 112 patients were subjected to one stage repair of hypospadias at departments of General surgery, Pediatric surgery unit and Urology and Nephrology center, faculty of medicine, Mansoura univeristy in the peroid between march 1994 and August 2000 their ages ranged from (2 years-14 years) with

amean age of 3.7 year. Their age distriuation was as follows:

<i>Age group (years)</i>	<i>Distal penile</i>	<i>Mid- penile</i>	<i>Proximal penile</i>	<i>Peno- scrotal</i>
2-3	5	5	10	10
3-5	10	12	12	9
5-10	11	10	8	4
> 10	5	1	0	0
Total number	31	28	30	23

The hypospadias was distal - penile in 31, mid- penile in 28, proximal penile in 30 and peno- scrotal in 23, chordae was found in 37 patients (33 %). It was in the ventral direction. Previous trial of repair were performed in 8 patients (4%). Follow- up peroid ranged from 12 month to 72 month with a mean peroid of (30) months. Family history for hypospadias was positive in three patients (3%), while cryptorchidism was present in 6 patients (8%). Careful assesement for any illness was done. No parenteral or local testosterone was given. General anaesthesia and caudal regional analgesia were used A 3/0 silk traction suture on atraumatic needle was placed in the dorsol mid-line glans (Fig.1).

The penis was degloved completly to its base on the top of Buck's fascia (Fig. 2). Artificial erection test was done by injection of saline (1-2 ml) into one of the corpora cavernosa while tornquit was applied to observe any chordae (Fig. 3). (orthoplasty).

The abnormal meatus was dilated to adequate size by a Nelaton catheter number 8 cheriere, A vertical incision was made to about 1cm porximal to the abnormal meatus and extented dorso-laterally incriminating enough parameteal skin after insertion of a silicon catheter number (8) cheriere (Duplay tube), was tied. Another Nelaton catheter number (8) cheriere, at the base of the penis as a tornquit (Fig.4). To be untied every 15 minutes. Creation of the neourethra was done using 7/0 vicryl inverting interrupted stitiches. Optical loupes with a magnification of 2.5 - 3 times were used.(Fig.5).

In the peno-scrotal type, the urethral plate was detached just distally to the meatus, the urethra was mobilized and the deficient urethra was reconstructed from the dorso-lateral foreskin and rotated as desired. A cone-shaped glans flaps were created for reconstruction of the distal urethra.

The urethra was covered by a layer (intervening layer) either a dorsal subcutaneous flap (Fig.6). In distal, mid and proximal penile types or a tunica vaginalis blanket wrap in peno-scrotal type.

In the dorsal subcutaneous flap, the dorsal prepuce was unfolded with dissection of the underlying dartos to the base of the penis avoiding vascular compromise to the shaft skin during proximal dissection. The Dartos was incised in the midline in Byar's fashion, the flaps were brought ventrally and stiched over the neourethra using 7/0 vicryl interrupted stitiches (Fig.7).

In tunica vaginalis blanket wrap, the penis was degloved, the testis was delivered and the tunica vaginalis was oriented on its pedicle and sutured with 7/0 vicryl interrupted stitiches along the lateral margin of the dorsal neurovascular bundle to avoid overlapped suturus covering about three-quarters of the shaft penis. We used a low current electrocautery.

Skin coverage of the penile shaft was made by sliding forward the penile skin, removal of the excess dorsal foreskin and closure of the coronal margin in a fashion of circumcision in distal, mid- penile types, while in proximal and peno-scrotal types, skin coverage was done by approximation of the dorsal foreskin as a single flap to the ventral shaft skin in the ventral midline without tension avoiding asymmetry and torsion of the penis by glans orientation during closure of the coronal margin. (Fig 8).

The ventral glans was then reconstructed by creation of two glans "wings" which were mobilized off the ventral tips of the corpora and closely sutured over urethraplasty in layers without compromising of the urethral lumen then reconstruction of the mucosal collar with ventral midline subcoronal skin.

In distal and mid, penile types, transurethral drainage was done using silicon catheter number 8 chieriere which was cutted flush with the external urinary meatus acting as splint to be removed on the seventh post-operative day. While in proximal penile and peno-scrotal types, suprapubic and urethral drainage were used. The urethral catheter was removed on the seventh post-operative day while the suprapubic one was removed on the fourteen post-operative day. (Fig 9).

A 5 cm cépe bandage roll was applied lightly "sandwich" dressing on the repair and was placed on the abdominal wall for compression. Antibiotics, anti-inflammatory, Fucidin cream and oral analgesic were used. The dressing was removed 72 hours post-operatively.

## RESULTS

During the period between March 1994 and August 2000, 112 cases of hypospadias were studied. Follow up period ranged from 12 months to 72 months. With a mean period of 30 months.

No urethrocutaneous fistula occurred in distal penile type, while occurred in one patient (3.5%) in mid-penile. in three patients (9%) in proximal penile. and in four patients (17%) in peno-scrotal Hypospadias repair of the fistula was done 6 months later in two layers with transurethral drainage. (Table 1) The total incidence of fistula was in eight patients (7%).

**Table (1) Incidence of urethro- cutaneous fistula:-**

Type of hypospadias	Incidence of fistula
Distal penile (n= 31)	0%
Mid - penile (n= 28)	1 patient (3.5 %)
Proximal - penile (n= 30)	3 patients (9%)
Peno - scrotal (n= 23)	4 patients (17%)
Total = 112	8 patients(7%)

Incidence of meatal stenosis was as follows: two patients (8.6%) in peno-scrotal type. For correction of the meatal stenosis, glans flaps were elevated with excision of the underlying scar and skin flaps were interdigitated.

Urethral stricture occurred in two patient (8.6%) in peno-scrotal type. They were managed by visual internal urethrotomy.

Recision of the meatus occurred in one patient (4.3%) in peno-scrotal type. Glans dehiscence occurred in the same patient. Meatal advancement and glanduloplasty were done.

Urethral diverticulum occurred in one patient (4.3%) in peno-scrotal type, for whom urethral diverticulectomy was done. No cases of flap necrosis or chordae recurrence were seen. (Table 2)

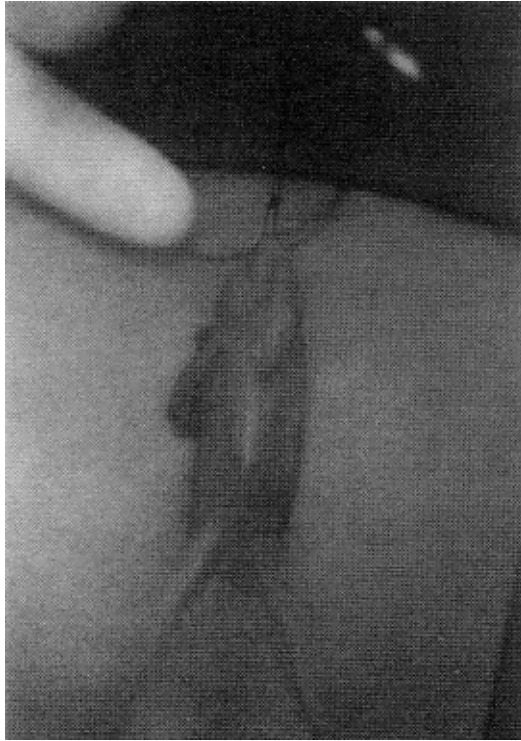**Table (2): Other complications in peno- scrotal type.**

Complication	Incidence/23
Meatal stenosis	2 (8.6%)
Urethral stricture	2 (8.6%)
Recision of the meatus	1 (4.3%)
Urethral diverticulum	1 (4.3%)
Flap necrosis	0
Chordae recurrence	0
Total	6 (26.08%)

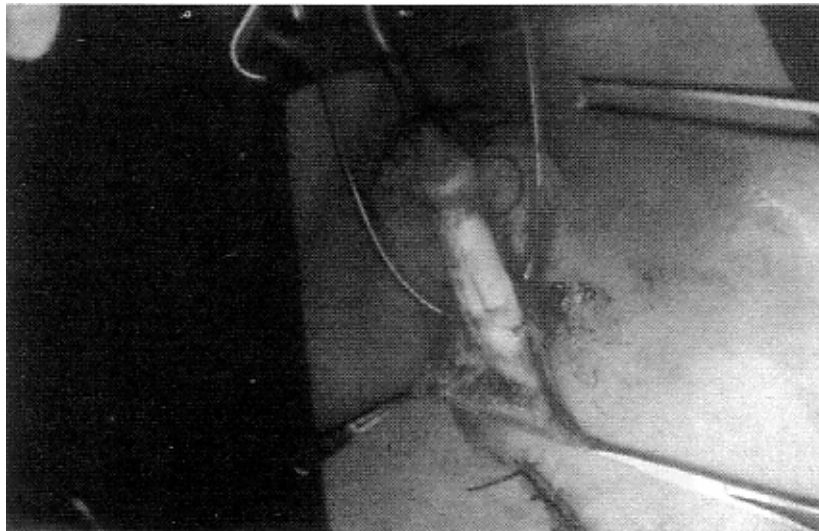
Excellent functional and cosmetic results (subjective) were obtained in distal, mid, and proximal penile types during the period of follow-up (minimum 12 month), in peno - scrotal types, results were good in 16 patients (70%), moderate in 3 patients (13%) and bad in other four patients (17%). (Table 3).

**Table (3): Cosmetic and functional results in peno-scrotal hypospadias**

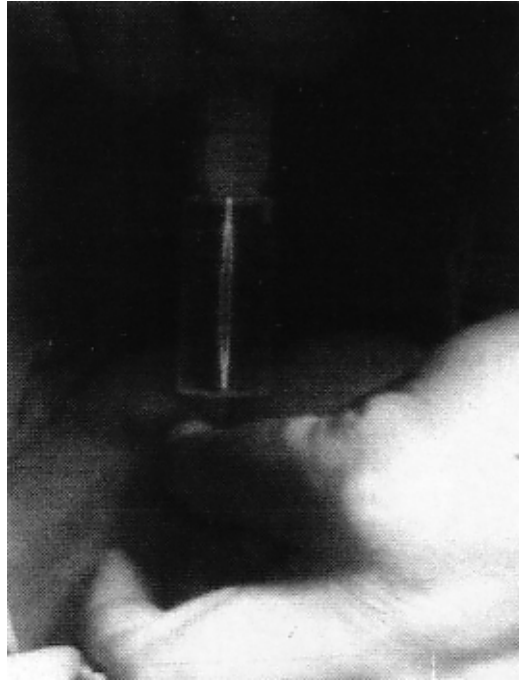
Result	Incidence/23
Good	70% 16 Patient
Moderate	13% 3 patients
Bad	17% 4 patients



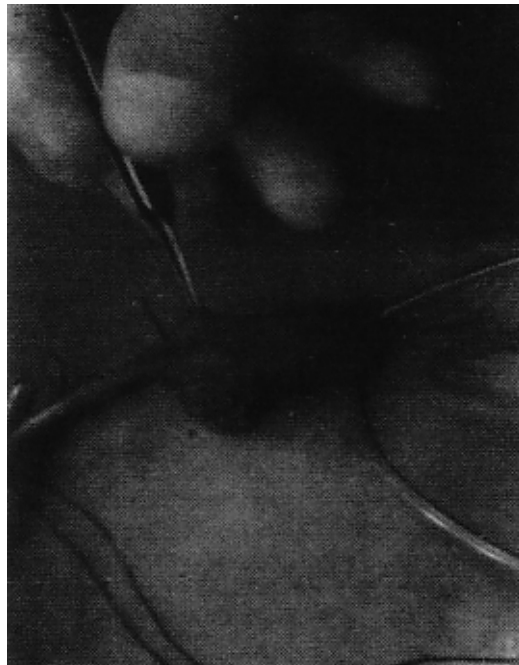
*Fig. (1): Traction suture in the dorsal mid-line glans.*



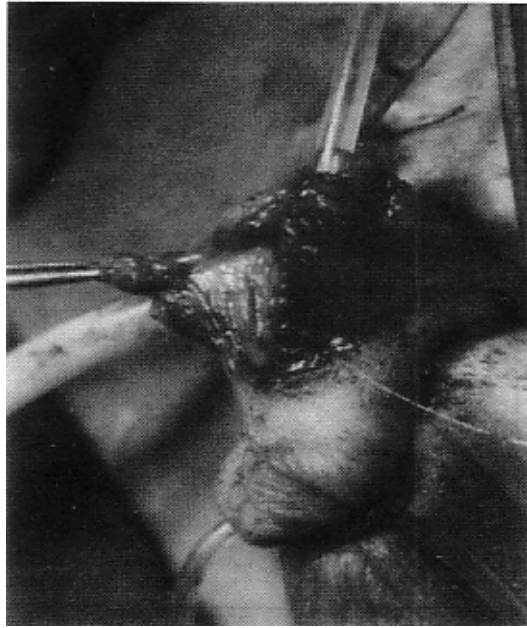
*Fig. (2) : Degloving of the penis completely down to its base.*



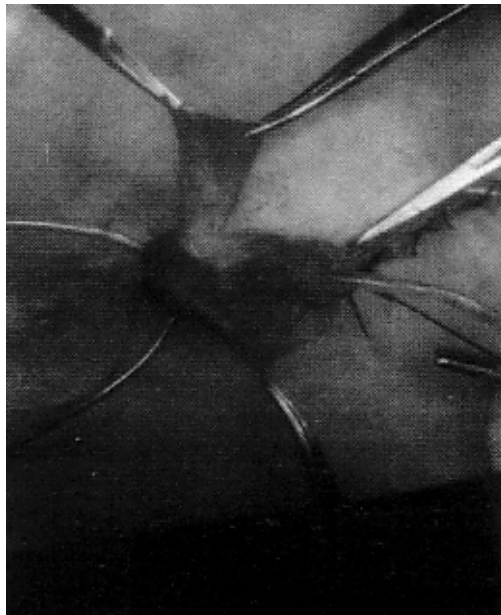
*Fig. (3) : Artificial erection test.*



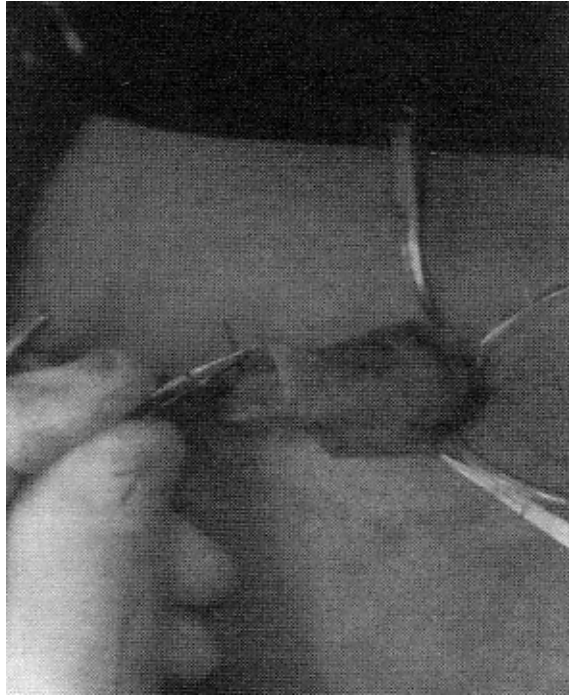
*Fig. (4) : Atornquit at the base of the penis using 8 chriere Nelaton catheter.*



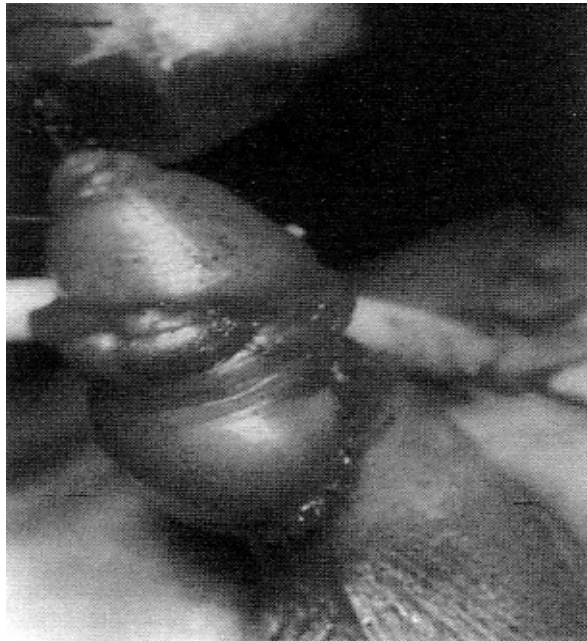*Fig. (5) : Magnification using loup 2.5 – 3 times.*



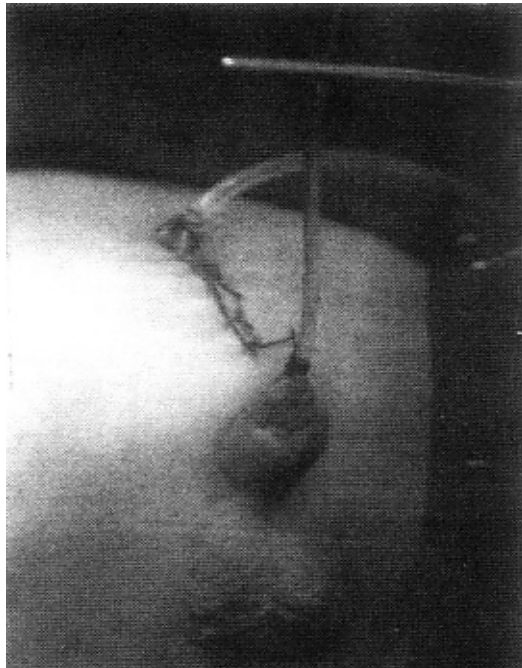
*Fig. (6) : Dartos flap.*



*Fig. (7) :Suturing of the flap over the neourethra (third layer)*



*Fig. (8) : Skin coverage using the dorsal foreskin.*



*Fig. (9) : Suprapubic and urethral urinary diversion.*

## DISCUSSION

There is a recent shift in the past 10 years for correction of hypospadias, whatever the type, in one stage due to simplicity of the treatment, both for the patients and the surgeon, operation in a virgin tissue, and the problem of chordae can be evaluated by saline erection test<sup>(6)</sup>. Even in the most experienced hands, hypospadias repair is associated with the development of urethrocutaneous fistula, it is the most common late complication and its incidence has been used to evaluate the effectiveness of the surgical procedure with arrange between 10% and 15% for most one stage hypospadias repair<sup>(7,8)</sup>, several surgical techniques has been used to decrease this complication. Skin incisions are made with a fine knife, tissues are handled gently using tiny skin hooks, fine traction sutures, watertight anastomoses are made and inverted towards the lumen when possible are overlying suture lines are avoided and the use of magnification.<sup>(9,10)</sup> Two stage operation that burried the hypospadias repair on the scrotum to attain a low fistula rate, deepithelization of one side of the shaft skin and using pants-over-vest closure to achieve an extremely low fistula rate.<sup>(11, 12,13)</sup>

Also the subcutaneous dartos flap can be readily obtained from the immediate operative field to cover the neourethra without sacrificing the penile skin especially when a paucity of penile skin is present. The dartos flap is vascularized which allows for added blood supply

immediately adjacent to the neourethra.<sup>(14)</sup>

It also provides the repair with non-crossing suture lines which is associated with a reduction in the rate of fistula formation. We used this flap in our series up to the proximal penile type with a rate of fistula formation as follows: 0% in distal penile, 3.5% in mid-penile and 9% in proximal penile type. However, some authors reported no fistula formation.<sup>(15)</sup>

In the peno-scrotal type, we utilized the tunica vaginalis blanket wrap as intervening layer on the lateral margin of the neurovascular bundle with a rate of fistula formation (17%). Some authors reported a rate of 20% without tunica vaginalis blanket wrap while (9%) with the use of the wrap and the routine microscope.<sup>(16)</sup>

The main blood supply to the hypospadiac urethra is via a branch of internal pudendal artery which runs proximally through the spongiosum, so urethral mobilization causes no nutritional problems<sup>(17,18)</sup>. The flap was harvested from the dorso-lateral foreskin which is rich in elastic fibres and smooth muscles than the ventral penile skin which can be rotated as desired<sup>(19)</sup>. We utilized lateral using of the glans (splay glans) in construction of the distal urethra creating cone-shaped glans, sharp tipped meatus and a projectile non-sprayed urinary stream<sup>(20)</sup>

Meatal stenosis "distal" occurred in two patients (8.6%)



with peno-scrotal hypospadias . However , the development of lateral glandular wings later in the study improved this complication .Some authors reported a rate of 1.3 % <sup>(21)</sup> we used trans-urethral drainage in distal , mid penile types and suprapubic drainage was added in proximal-penile and peno-scrotal type for watertight repair, immobilized suture lines, reduction in tissue reaction and patient comfort <sup>(22)</sup>

Excellent functional and cosmetic results were obtained in distal , mid, and proximal penile types , while in peno-scrotal type , the results were bad in (17%) .during the follow up period .

On conclusion , due to low incidence of complications of one stage repair for all types of hypospadias by using (third intervening layer either from the dartos fascia or tunica vaginalis to cover the neourethra , by sticking to the basic surgical principles , and the use of magnification) and due to excellent cosmetic and functional results , we recommend one stage repair for all types of hypospadias tailoring the technique for the proper type of the anomaly.

## REFERENCES

- Weidner I. S. Moller H, Jensen T.K and Shakkebaek : Risk factors for cryptorchidism and hypospadias J.Urol 1999 161(5) : 1606- 1609.
- Schaeffer C.S and King L.R: Anomalies of the male genitalia in Geardiade plastic, maxilo- facial and reconstructive surgery 1997 ch. 77 williams and wilkins Awaverly company Baltimore, London p. 844.
- Albert N,: Etiologic classification of severe hypospadias : Implication for prognosis and management J.Ped. Surg 1997 (131): 381 - 392
- Sorber M. Short- and mid-term outcome of one stage Hypospadias corrections. Eu. J Urol. 1997 32(4) : 475 - g.
- Horten L E and Devine C J: Simulated erection of the penis with saline injection: a diagnostic maneuver : plastic - Reconstr- surg. 1997 59, 670
- Redman JF: Tornquit as haemostatic aid in repair of hypospadias urology 1986 : 28 , 241.
- Kuyanagi E.D, Nonomura K, Kokizaki H : Experience with one stage repair of severe proximal hypospadias : operative technique and result Eur. Urol 1993 24 : 106- 110
- Kuyanagi T, Matsuno T, Nonomura K, Sakakibara N : complete repair of severe peno-scrotal hypospadias in one stage: Experience with urethral mobilization, wing flap-lipping urethroplasty and glanulomeatoplasty J. Urol 1993: 130 : 1150 - 4.
- Waeksman J. hypospadias repair : Update and controversies - part 2 , use of microscope Dialogues in pediatrics urology 1990 13 : 2
- Horotn C E and Devine C J and Graham JK : Fistulas of the penile urethra plastic Reconstr. Surg 1980 66; 407
- Retik AB: Primary and re-operative repair with the Snodgrass technique - world. J. Urol 1998: 16(3): 186 - 191
- Lau J.TK and Ong G.B: Double- breasted technique for the repair of urethral fistulas after hypospadias surgery Br- J. Urol . 1988; 54; 111
- Perovic SV: Anew approach in hypospadias repair world J. Urol 1998; 16(3): 192- 4
- Retik AB, MAndell J, Bouer S.B and Atala A: Meatel based hypospadias repair with the use dorsal subcutaneous flap to prevent urethro cutaneous fistula J.Urol. 1994: 152: 1229
- Paharas J.G and Rusuchton H.G : penile torqou after use of tunica vaginalis blanket wrap as aid in hypospadias repair J. Urol 1999 : 161 (4) : 434- 5
- Show B W, Cartwright pc and Ungerck : Tunica vaginalis blanket wrap to prevent urethra cutaneous fistula : An-eight year expirience J. Urol 1995 153 : 472- 3.
- Grossman A.I, Coldamone A: cutaneous blood supply of the penis Plast . Reconstr-Surg. 1989: 83; 213.
- Koyanagi J, Nonamura K, Asano Y: One stage urethroplasty with parameatel foreskin flap (OUPE) : simple method universally applicable to all types of hypospadias repair (abstrac) . J.Urol . 1992 : 147 : 317 A
- Monfort G, Bretheau D, Di Benedetto V, Bankole R : posterior hypospadias repair: A new technical approach . Mobilization of the urethral plate and Duplay urethroplasty Eur. Urol. 1992, 22: 137- 141
- Smith Ep- Evaluation of serve hypospadias J.pediatr. Surg 1997 131 (3): 344- 6
- Duel BP: Management of urethral stricture after hypospadias repair.J. Urol 1998: 160 (1): 170 - 1
- Domirbilek S and Atoyurt F : One stage hypospadias repair with a stent or suprapubic diversion which is better? J.ped surg 1997: 32(12): 1711 – 1712.