

SMALL MYOCUTANEOUS MUCOSAL FLAP RECONSTRUCTION OF THE UPPER AND LOWER LIP AFTER EXCISION OF THE LOCALLY ADVANCED LIP MALIGNANCY

By

Adel. Denewer. MD. Wael Khafagy, MD , Sherif Kotb, MD. Ahmed Setit, MD. Mosaad Morshid, MD. Khalil El-Etriby, MD, Mohamed El-Shobaky MD.

Surgical Oncology Unit and General Surgery Department, Faculty of Medicine, Mansoura University, Mansoura-Egypt

Introduction: The carcinoma of the lip is always a squamous cell carcinoma, adequate excision of the malignancy was always accompanied by cure but with composite defects of skin and mucous membrane. We always need to combine reconstructive techniques to achieve the integrity of all layers.

Patients and Methods: For thirty two patients of locally advanced lip malignancy, radical excision and reconstruction were achieved. For twenty four patients near total lower lip and sometimes total lower lip were removed and reconstruction of the lower lip was done using the depressor anguli oris myocutaneous mucosal flap (DAOMMF) and tongue flap. For four patients excision of the upper lip and part of the lower lip was reconstructed with depressor anguli oris myocutaneous mucosal flap (DAOMMF) with cheek advancement. For four patients excision of the upper lip only and reconstruction was done using the same flap but sometimes with tunneling technique.

Results : Good results were achieved in 28 cases. Separation of the suture line has complicated one case, with repeated preoperative courses of radiotherapy. Partial necrosis of the flaps complicated two cases . Unaccepted hypertrophied scars with contracture deformity complicated one case only.

Conclusion: Adequate excision and primary reconstruction, gives the best results for cure and cosmeses for management of the lower and upper lip malignancy. The combined techniques of reconstruction can solve the most complicated defects.

Keywords: Lip malignancy-Reconstruction- Myocutaneous flaps.

INTRODUCTION

The lips play a key in deglutition, formation of speech, and facial expressions. Lip reconstruction offers a unique challenge to the surgeon. Few other sites require as much attention to such precise details of reconstruction in order to restore proper form and function

Surgical procedures to reconstitute the lip following tumor ablation may be classified as follows⁽¹⁾: (a) those that use remaining lip tissue, (b) those that barow tissue from the opposite lip, (c) those that use adjacent cheek tissue, and (d) those that use distant flaps.

The superiorly based Estlander flap may be modified from its original description by designing the flap so that it lies within the nasolabial fold⁽²⁾ This provides better scar camouflage of the donor site and at the same time allows easy rotation of the flap into the lower lip defect .

Similarly midline lower lip defects may be closed by full-thickness advancement flaps as described in (1960)⁽⁶⁾ These techniques require excisions of additional triangles in the nasolabial region to allow advancement of nasolabial full-thickness transposition flaps consisting of skin, subcutaneous tissues, and mucosa, or skin only, can be useful in reconstructing lip defects as large as three fourths of the width of the lip⁽⁷⁾. Matched full - thickness flaps can be created in the area of the nasolabial folds in each cheek

with a z-plasty at their base to enhance the ease of transposition. The flaps are transposed into the lip defect and sutured in three layers. Mucosa from the flaps can be advanced to create a new vermilion, or a tongue flap may be required.

Perialar crescentic advancement for upper lip cancer (Webster's technique) ⁽⁸⁾ which may be used when combined bilaterally, reconstruct up to two-third of the upper lip that involve the philtrum, providing an excellent cosmetic result. Larger defects may be reconstructed by using this technique is combined with an Abbe flap from the lower lip or a revers flap ⁽⁹⁾. Total upper lip reconstruction is rarely required but may be performed using either bilateral nasolabial of formal Gilles fan flaps supplemented with vermilion rconstruction using tongue advancement. The conventional Abbe flap ⁽¹⁰⁾ as described is used to reconstruct upper lip defects from the lower lip. Reverse Abbe flaps may be used from the upper lip to the lower lip but because of the problems of symmetry and the philtrum these are usually smaller and require more skill and the outcome is not usually as good. They are rarely used.

The aim of this study is to evaluate the use of local small myocutaneous mucosal flaps in reconstruction of lip after radical excision of malignancy.

PATIENTS AND METHODS

In this study, we have operated upon 32 patients with upper, lower, or both lip malignancy, 13 females (F) 19 males (M). The mean age was 46 years ranging from 12 to 78 years. The preoperative data and plan for reconstruction of the defects are summarized in (Table 1). In the first group of near total lower lip extirpation, (Fig. 1) with suprahyoid block dissection, in 14 cases the reconstruction was mainly directed towards the restoration of the lost lower lip, that was achieved by using the depressor anguli oris (myocutaneousmucosal) flap, DAOMCMF). This flap depending on the angular vessels (the terminal branch of the facial vessels) (fig. 2). In the second group ten patients have squamous cell carcinoma of the lower lip that need total lower lip extirpation and total lower lip restoration (Fig. 2), defects needed multiple

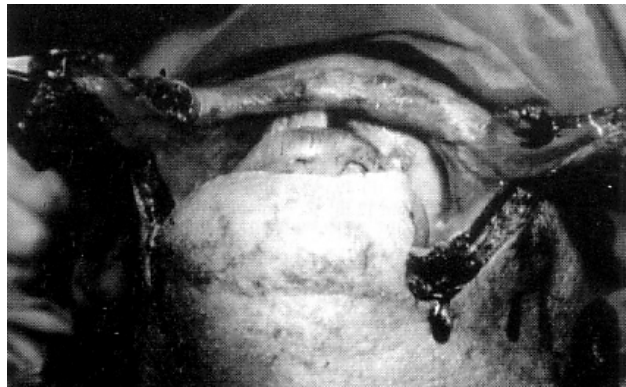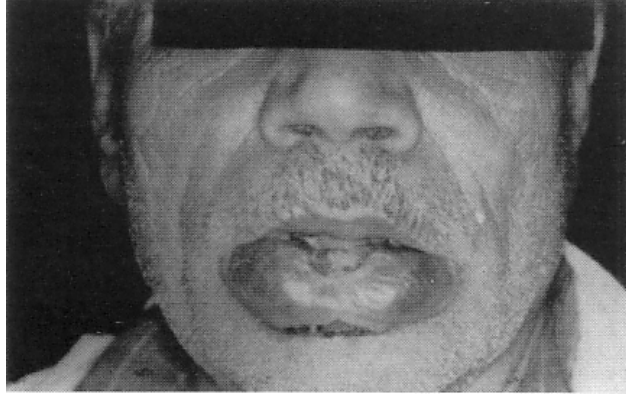composite flaps for their proper closure and integration (bilateral depressor anguli oris myocutaneousmucosal flaps and tongue flap) .In the third group of cases (four patients) the lesion was involving the upper and lower lip, the surgical defect included the upper lip, part of the lower lip and the angle of the mouth. The reconstruction was achieved with both the nasolabial flap and the depressor anguli oris myocutaneousmucosal flaps (Fig. 3). In the fourth group of patients the lesion was in the upper lip with removal of the part involved in the upper lip. Reconstruction was achieved by depressor anguli oris (myocutaneousmucosal flaps) either pedicled and tunneled island flap or peninsular flap (Figs.4, .5).

RESULTS

In 32 cases of squamous cell carcinoma of the lower lip and upper lip complete excision of the lesion with suprahyoid block dissection in 20 cases and without block dissection in 12 cases. The near total reconstruction of the lower lip was achieved by using the (DAOMCMF) in 14 cases , complete healing was achieved in all of them with good cosmetic results. In the second group of patients the total lower lip reconstruction was achieved by using bilateral (DAOMCMF) and tongue flap complete healing was achieved in 8 cases of them with good cosmetic results. In the other two cases the separated suture line was reclused in one case, but with some disfigurement. There was mild partial necrosis that was refashioned with mild and accepted microstomia in the other one. In the third group of patients, four cases of carcinoma involving both upper and lower lip, complete excision of the tumor with combined flap reconstruction of the through and through defects of the partially removed upper and lower lips using the nasolabial flap and (DAOMCMF). Complete healing was achieved in three cases of them with good cosmetic results, in the other case the partial necrosis was treated with debridement and reclosure. In the fourth group of patients the partially removed upper lip was reconstructed by (DAOMCMF) either tunneled pedicled island flap in two cases or peninsular flap in the other two cases. Healing was achieved in all of them. The cosmetic results were good and well accepted in 28 patients. The oral function could be achieved in all patients.

Table (1) :

<i>Patients (n.)</i>	<i>Extent of the lesion.</i>	<i>Defect after resection.</i>	<i>Method of reconstruction</i>
14	Lower lip	Near total lower lip	Depressor anguli oris (DAOMMF)
10	Total lower lip	Total lower lip	Depressor anguli oris (DAOMMF) on both sides + tongue flap.
4	Upper lip and lateral lower lip.	*The angle , upper lip and lateral part of the lower lip	Depressor anguli oris (DAOMMF) and extended cheek flap.
4	Upper lip only.	Upper lip.	Both DAOMMF and nasolabial flap.



*Fig (1) A. Squamous cell carcinoma of the lower lip.
B. One week post operative .*

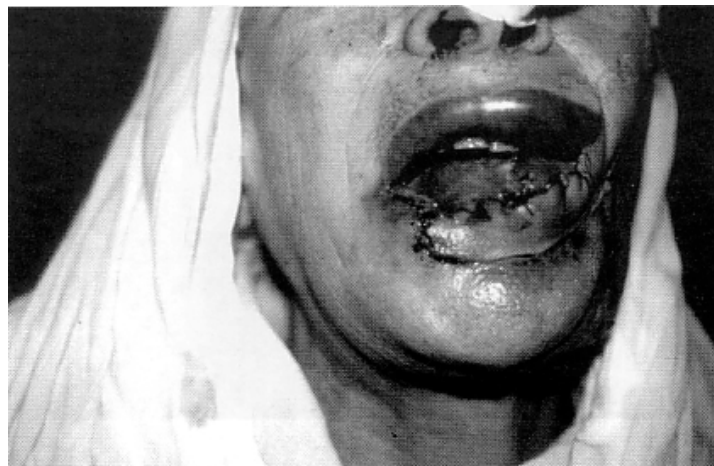
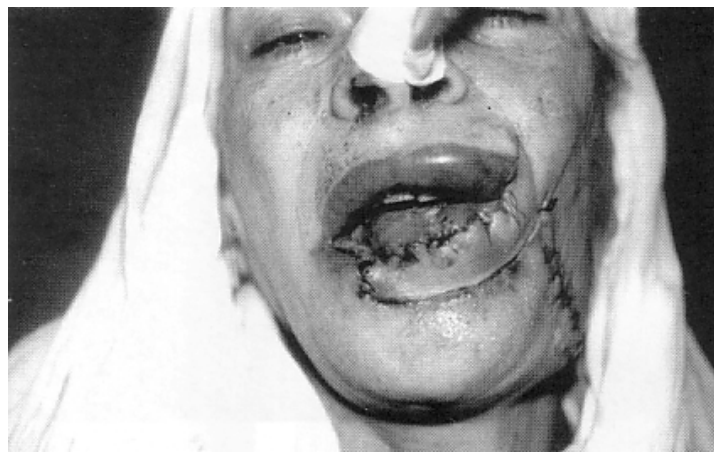
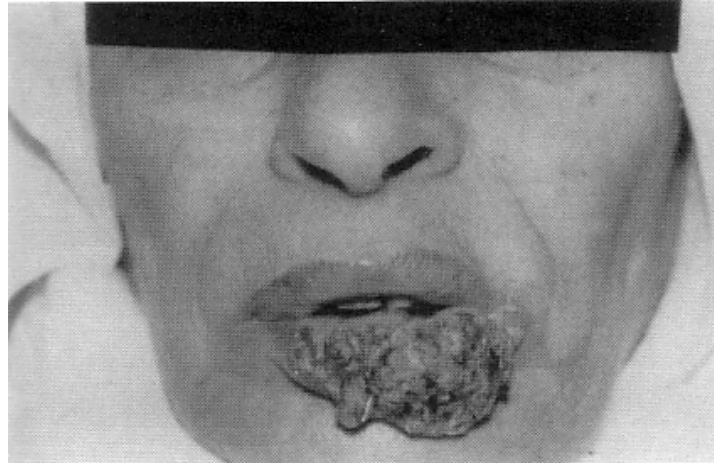Fig (2):
A. Squamous cell carcinoma of the lower lip
B. Excision and elevation of bilateral depressor anguli oris musculocutaneomucosal flap.
C. One week post operative.

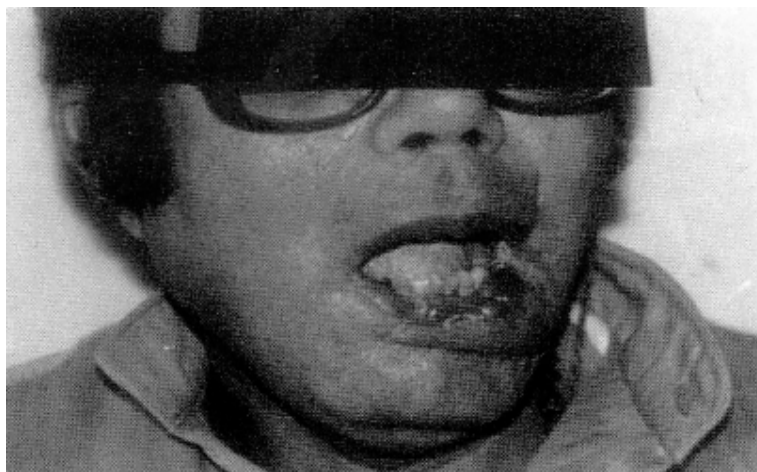
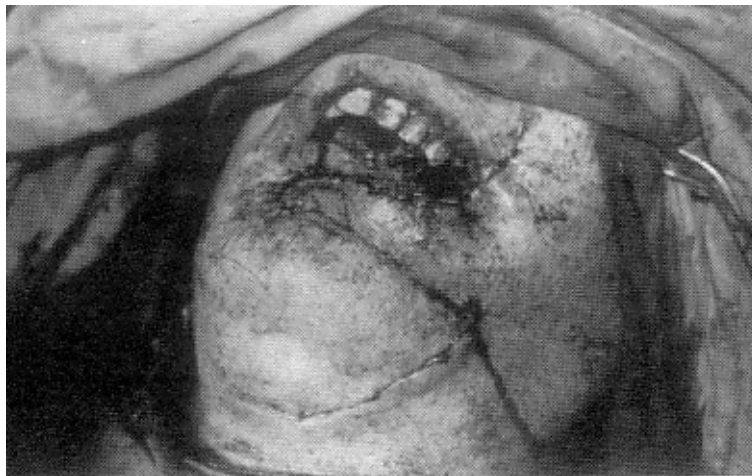
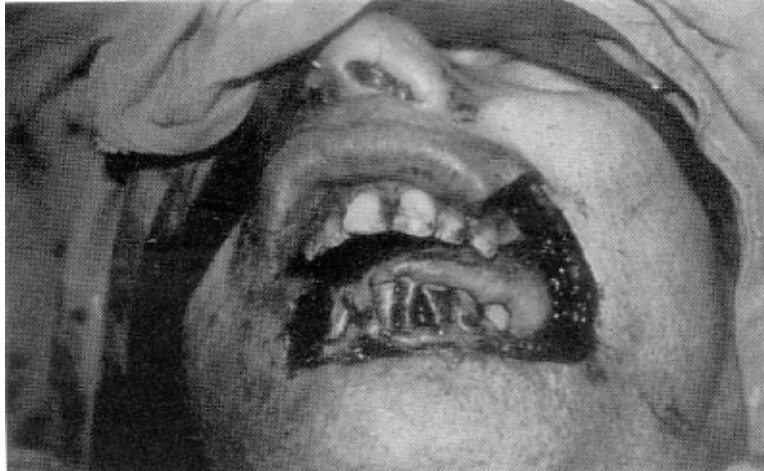
Fig (3)

A. Defect after excision of squamous cell carcinoma of the lower lip, angle and upper lip

B. Operative view after reconstruction.

C. Five month post operative .

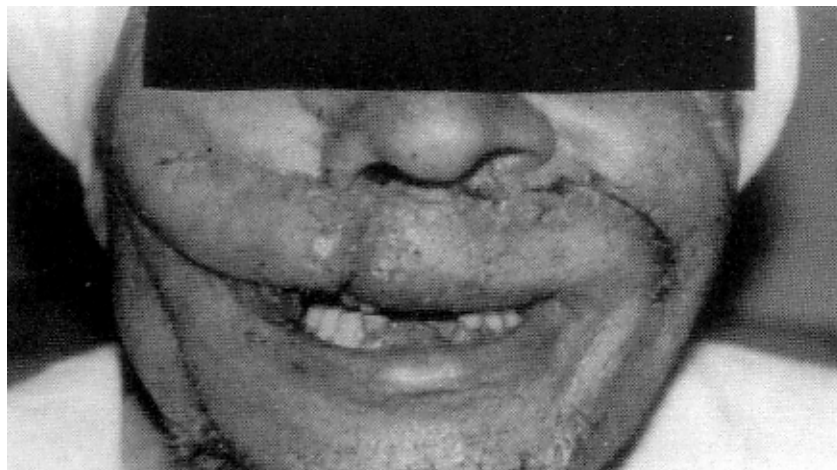
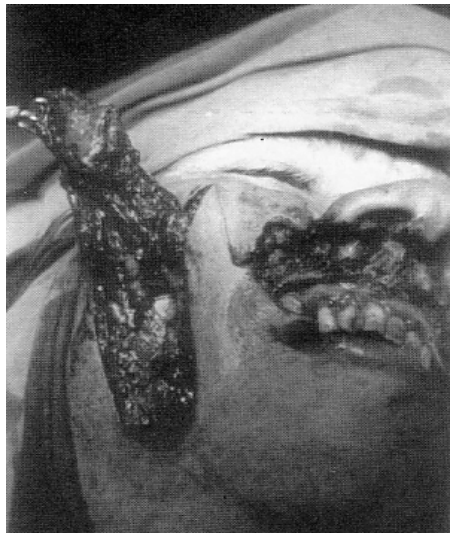
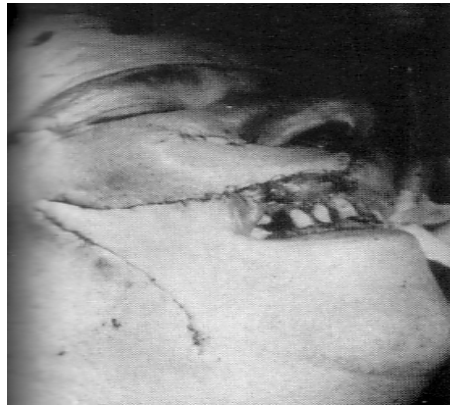
Fig (4)

A. Defect in the upper lip and floor of the nose after excision of squamous cell carcinoma of the lip with elevation of the flap.

B. Reconstructed upper lip with musculocutaneomucosal flap.

C. Three month post operative .


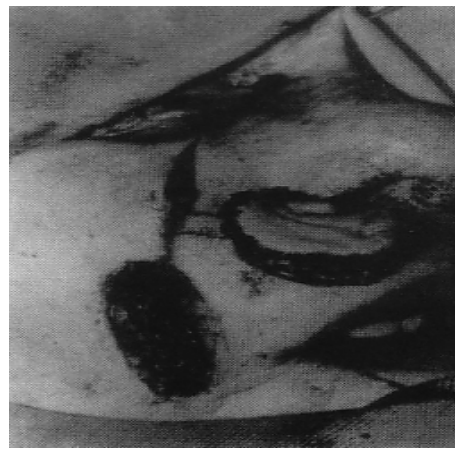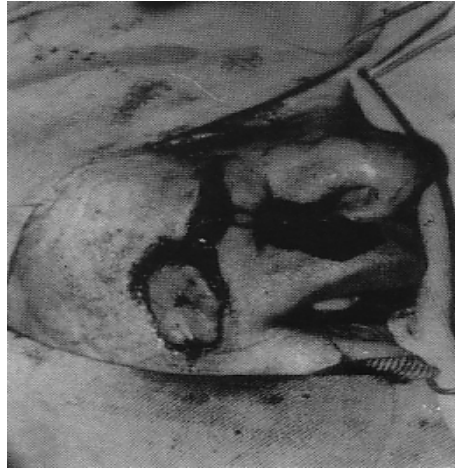


Fig (5)
A. Defect after excision of squamous cell carcinoma of the upper lip with elevation of flap
B. Transfere of the island flap (tunneled).
C. One year post operative

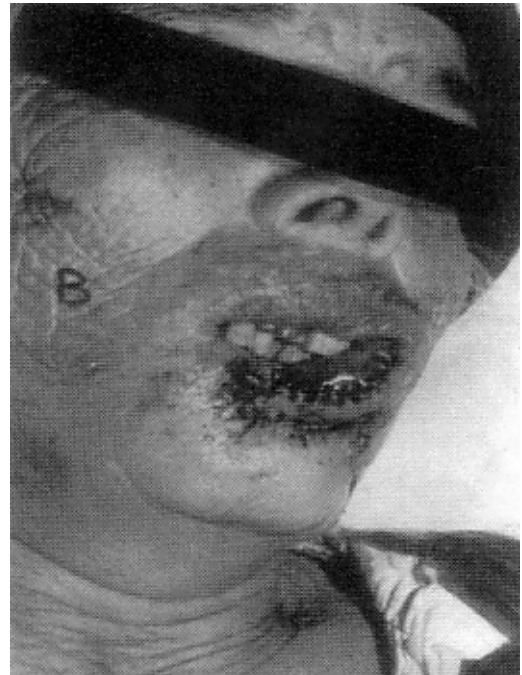
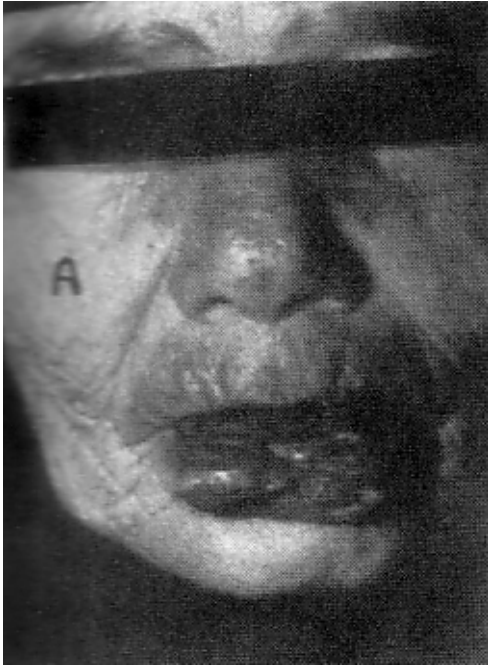
Fig (6)
*A, Squamous cell carcinoma of the lower lip,
B, One week post operative with unilateral musculocutaneous mucosal flap of depressor anguli oris*

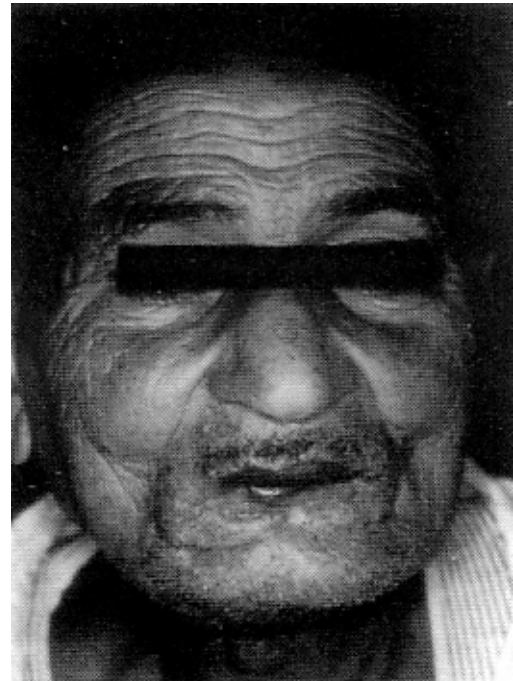
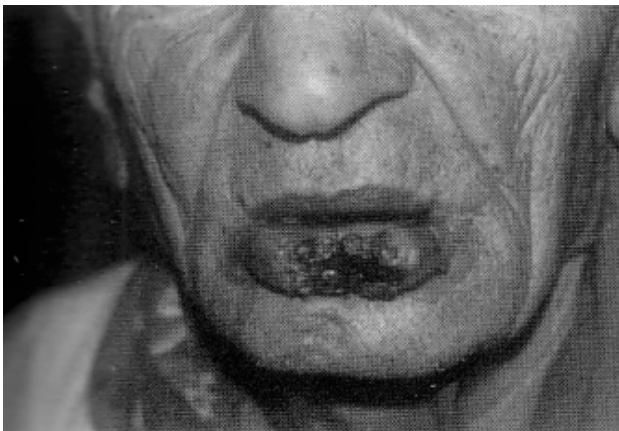

Fig (7)
*A, Squamous cell carcinoma of the lower lip
B, Six month postoperative after reconstruction of the whole lip with bilateral flap .*

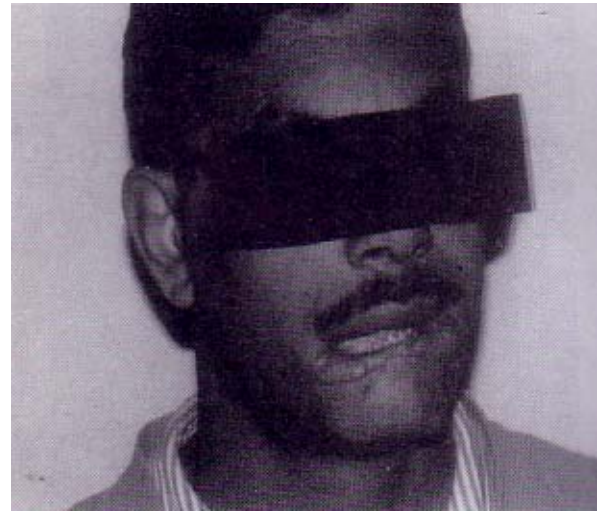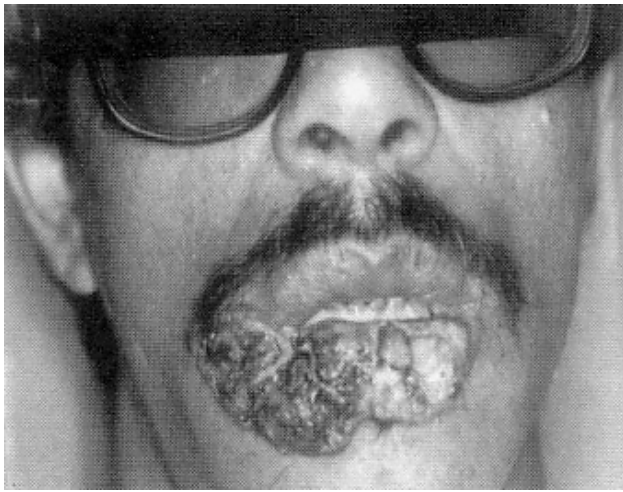


Fig (8)
A, Squamous cell carcinoma of the lower lip
B, Six month postoperative after reconstruction of the whole lip with bilateral flap .

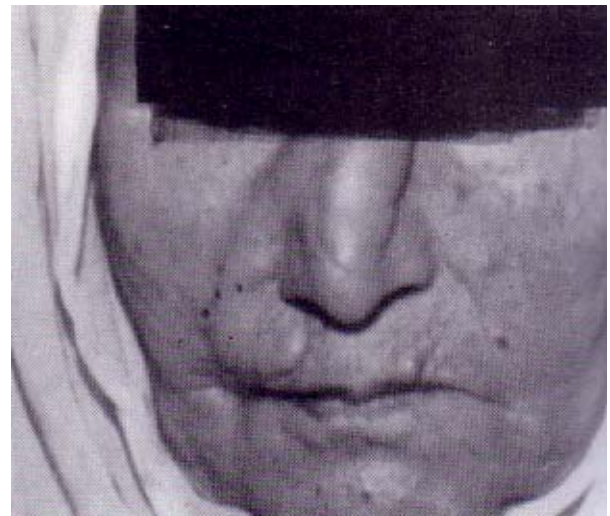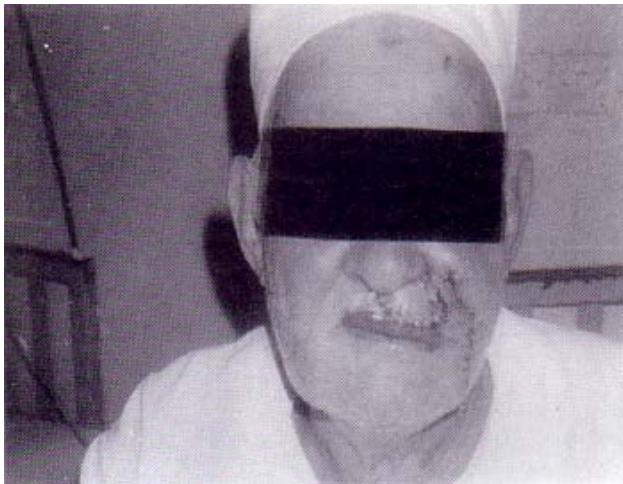


Fig (9)
A, Two weeks post operative after reconstruction of the upper lip
B, Two years post operative after reconstruction of the upper lip.

DISCUSSION

The labial malignancy as all head and neck tumors is mostly a loco-regional disease. The less aggressive surgery aiming to conserve the functions of the area is always accompanied by recurrence. Our therapeutic strategy has a curative objective, in-addition to restoration of function. Adequate surgery is considered an important prognostic factor in head and neck tumors, but was always accompanied by very difficult composite defects for reconstruction. In our study 14 patients have radical lower lip lesion extirpation and near total lower lip reconstruction (Table 1) by using the DAOMMF. The oral cavity competence was achieved in all cases by the first operation with good cosmetic appearance (Fig 6). This new small myocutaneousmucosal flap has an excellent aesthetic appearance in-addition to minimal donor site morbidity. In ⁽¹¹⁾ Pribaz used the musculomucosal flap of the facial artery to reconstruct the upper lip in seven patients and the lower lip in six patients with excellent results. Other authours ^(12&13) have used DAOMMF to reconstruct the upper lip in twenty patients ⁽¹²⁾ with satisfactory results in 19 patients and unsatisfactory in one only. The depressor anguli oris flap was used as an island flap ⁽¹³⁾ in reconstruction of large lower lip defects in 8 cases with accepted cosmetic appearance in all cases and sphincter function in six cases.

We have used Bilateral DAOMMF and tongue flap to reconstruct the totally lost lower lip in ten patients (figs.7,8) , the tongue flap proved to be an excellent mucosal flap to complete the red line closure with the bilateral DAOMMF. In this group of patients eight could achieve good cosmetic results with only one patient of suture line separation and another one developed minimal partial necrosis. The sphincter function was accepted in all cases (Fig. 9).

Reconstruction of hemilip ⁽¹⁴⁾ and total upper lip⁽¹⁵⁾ was successful in five cases of hemilip using the lower lip and in total upper lip reconstruction with bipediced DAOMMF in one patient .

We have used the DAOMMF and the nasolabial flap to reconstruct part of the upper lip, angle of the mouth and adjacent part of the lower lip.

Among these four cases three patients could achieve good oral competence and accepted cosmetic appearance with one case of minimal necrosis that was treated with debridement and recluser.

In ⁽¹⁶⁾ rustal reconstructed one hundred nine patients with melolabial defects using the subcutaneous pedicle flap, the results were concluded to be ideal. Other authours⁽¹⁷⁾, have used local island flaps to reconstruct defects in the

upper lip in 13 patients with only one flap partial necrosis and functionally and aesthetically good results. In the fourth group of patients the partially removed upper lip was reconstructed by (DAOMCMF) either tunneled pediced island flap in two cases or peninsular flap in the other two cases. Healing was achieved in all of them. In our series we could achieve good cosmetic and functional results in the four cases.

CONCLUSION

Reconstruction of the upper and lower lips by (DAOMCMF) either tunneled pediced island flap or peninsular flap proved to be successful, safe and donor site free of complications. Adequate excision and primary reconstruction, gives the best results for cure and cosmeses for management of the lower and upper lip malignancy. The combined techniques of reconstruction can solve the most complicated defects.

REFERENCES

1. Kazanjian, V.H. ad Converse, J.M. The surgical treatment of facial injuries, ed. 2, Baltimore, 1959, Williams & Wilkins.
2. Baker, S.R. and Krause, C.J. Cancer of the lip. In Suen, Y.J. and Myers, E.N. editors. Cancer of the head and neck. New York, 1981, Churchill Livingstone, Inc.
3. Burow, C.A.; Betschreibung einer neuen transplantations-methods (methode der seitlichen dreiecke) zum wiederersatz verolorengegangener theile des gesichts, Berlin, 1855, Nauck.
4. Bernard, C. Cancer de la levre inferiene opere par un procede nouveau. Bul. Men. Soc. Chir. 1983: 3:357.
5. May, H. Reconstructive and reparative surgery, ed. 2, Philadelphia, 1960; F.A. Davis Co.
6. Webster, R.C., Coffey, R.J. and Kelleher, R.E. Total and partial reconstruction of the lower lip with innervated muscle bearing flaps. Plast. Reconstr. Surg., 1960. 25:360.
7. Baker, S.R. and Krause C.J. : Pedicle flaps in reconstruction of the lip. Fac. Plast. Surg 1983. 1(1): 61.
8. Webster, J.P. Crescentic peri-alar cheek excision for upper lip flap advancement with a short history of upper lip repair, Plast. Reconstr. Surg., 1955 16:434.
9. Karapandzic, M. Reconstruction of lip defects by local arterial flaps. Br. J. Plast. Surg., 1974 27: 93.
10. Abbe, R.A. A new plastic operation for the relief of deformity due to double harelip. Med. Rec. 1889., 53:477.

11. Pribaz JJ ,Meara JG, Wright S, Smith JD, Stephens W, Breuing KH. Lip and vermilion reconstruction with the facial artery musculomucosal flap. *Plast Reconstr Surg.* 2000 Mar; 105 (3): .864-72.
12. Neto Ms, Castilho HT, ferreira LM, Hochberg J, Toledo SR. Utilization of the depressor anguli oris musculocutaneous flap for the upper lip reconstruction. *Ann Plast Surg.* 2000 Jan; 44 (1). 23-8.
13. Yotstuanagi T, Nihei Y, Yokoi K, Sawada Y. Functional reconstruction using a depressor anguli musculocutaneous flap for large lower lip defects, especially for elderly patients. *Plast Reconstr Surg.* 1999 Mar; 103(3): 850-6.
14. Gounot N, Delay E, Cresseaux P, Breton P, Freidel M. (Esthetic reconstruction of the superior hemilip using the Abbe technique modified by Burget. Apropos of 5 cases) *Ann Chir Plast Esthet.* 1998 Oct; 43(5): 534- 40.
15. Sabino Neto M, de Castilho HT, Garcia EB, Ferreira LM. Total reconstruction of upper lip and columella with bipediced island musculocutaneous flap. *Br J Plast Surg.* 1999 Jul; 52(5): 411-4.
16. Rustad TJ, Hartshorn DO, Clevens RA, Johnson TM, Barker SR. The subcutaneous pedicle flap in melolabial reconstruction. *Arch Otolaryngol Head Neck Surg.* 1998 Oct; 124(10): 1163-6.
17. Wlodarkiewicz A, Wojszwillo-Geppert E, Placek W, Roszkiewicz J. Upper lip reconstruction with local island flap after neoplasm excision. *Dermatol Surg.* 1997 Nov; 23 (11): 1075-9.