

LAPAROSCOPIC SELECTIVE VENOUS DISCONNECTION FOR VARICOCELE

By

Mohamed El-Sherif El-Sarky

Department of Surgery, Faculty of Medicine,
Cairo University, Egypt

The incidence of recurrence after surgery for varicocele ranges from 5 to 45%. The known reasons for this high recurrence are: 1) Development of collaterals in the pre-existing communicators of testicular vein (testiculo-ureteric, testiculo-colic, testiculo-renal, testiculo-testicular and others), 2) Persistence and progression of refluxing unattended venous drainage routes, e.g. external spermatic vein, and 3) Inadequate procedure (incomplete interruption or missing accessory or aberrant testicular vein).

Laparoscopy provides an ideal access to treat varicocele due to clear visualization of most of the involved venous systems (internal spermatic, external spermatic, deferential and others). The problem of recurrence is still observed with the conventional laparoscopic procedure for varicocele. Attempts at improving the current approach are thus invited.

In this work, a new laparoscopic approach for varicocele is described and its preliminary results are presented. The technique was designed to address known causes of recurrence of varicocele. It is based on the following principles: 1) Doppler guided identification of the individual veins involved in the pathology (reflux), 2) performing venous disconnection in place of simple interruption (by excising a long segment of internal spermatic vein to widen the pressure front, and ablating the veins within an area which extends across the course of the vein to eliminate communicator veins), and 3) Intraoperative assessment of completion of the procedure by Doppler testing for reflux.

Early results in 14 patients were encouraging. No Duplex-detected recurrence was observed during a follow-up period of 3 to 11 months. Conception occurred in 2 couples and 11 patients showed significant improvement in the quality of semen.

Key words: Laparoscopic varicocele – selective disconnection – intraoperative Doppler

INTRODUCTION

Varicocele is a common disease. It affects 15% of men and 41% of those who present with infertility⁽¹⁾. Recurrence after surgery for varicocele is grossly underestimated. It is more frequently assessed on clinical basis. This yields recurrence rates ranging from 5 to 20%⁽¹⁾. On the other hand, assessment on basis of Duplex scan or venography reveals much higher recurrence (or persistence) rates that range between 29 and 45%^(2,3). Recently, the sensitivity of clinical examination in detecting varicocele was reported to range from 33 to 74%⁽³⁻⁵⁾.

The main causes for the observed high recurrence after varicocele surgery are three: 1) developed collaterals within the interrupted venous drainage system, i.e. internal spermatic vein, ISV), 2) persistence and progression of uninterrupted pathological venous drainage routes, e.g. external spermatic vein, and 3) inadequate interruption of the ISV, i.e. technical fault.

Several attempts have been previously made to reduce the recurrence after varicocele surgery. A comprehensive approach to reduction of recurrence after varicocele surgery should address all known causes and include a mean to confirm completion of the procedure before its

conclusion. In this work, a new surgical approach was designed to achieve these objectives. The technique was employed in 14 patients and results are reported.

PATIENTS AND METHODS

Patients and diagnosis

The study included 14 consecutive patients who ranged in age from 21 to 38 years (Mean = 28.2 and SD= 4.8). The majority (12 patients) presented due to infertility. It was primary in 10 patients and secondary in 2 others. Two patients (unmarried) presented due to testicular pain and swelling. Varicocele was recognized in all cases during clinical examination but the diagnosis was established on basis of Duplex scan. None of the patients had associated venereal or andrological disorders. None of those who presented due to infertility suffered from evident sexual dysfunction or received hormonal therapy for testicular insufficiency or other endocrine disorders.

Duplex criteria for diagnosis of varicocele were basically: visible evidence of reflux on cough or Valsalva maneuver as well as multiplicity and large size of the veins. On basis of the Duplex examination, the disease was limited to the left side in 11 patients while 3 others had bilateral varicocele. Semen analysis revealed deteriorated parameters in all patients, particularly sperm count, motility and abnormal forms. All patients had a spermatic count less than 40,000,000/ml (range: 500,000 to 33,000,000, average: 11,460,000 \pm 10,050,000) and significantly reduced motility. The triad of: complaint (infertility, pain or swelling), venous reflux on Duplex scan and deteriorated semen quality were essential prerequisites prior to selecting a patient for the procedure.

Technique

The procedure is done under spinal anesthesia with mild sedation. It starts with the patient in the supine position and the operating table in the horizontal level. For a left varicocele, the surgeon stands on the right side of the patient, the first assistant (who holds the telescope) stands cephalad to the surgeon on the same side while the nurse stands on the left side of the patient, (Fig. 1). A second assistant (the one who positions the Doppler probe externally) stands on the left side as well (caudally, in relation to the nurse).

The first step is to do Doppler testing of the spermatic cord at the neck of the scrotum for arterial pulse and venous reflux. This is done to set a baseline prior to surgery. In this work, a manual Doppler was used and reflux was tested by listening for the characteristic audible signal when the patient coughed, (Fig. 2). The use of Duplex scan, when available in the theater, is probably a better alternative.

A small subumbilical incision (1 cm) is made and peritoneal insufflation is performed via a Veress needle to a pressure of 15 mmHg. The umbilical trocar-cannula is inserted and the telescope is introduced. During the procedure, the intra-abdominal pressure is reduced to 12 mmHg. The surgeon inspects the abdomen in general but focuses on the anatomy of the venous drainage of both testes, (Fig. 3). Two other ports are then introduced, each is midway between the umbilicus and the anterior superior iliac spine, at the lateral border of the rectus abdominis, on one side of the abdomen.

The initial steps in dissection are similar to those of the classical laparoscopic procedure for varicocele (opening a window in the parietal peritoneum over internal spermatic vessels and dissecting to identify individual vessels), (Fig. 4). The artery is identified by its visible pulsation. It is isolated to allow the inclusion of all the other vessels within the field in disconnection, (Fig. 5). An attempt is considered to spare the artery unless such a step is judged to compromise full venous ablation.

Identification of the source of reflux is assessed by a Doppler-based test: "*Reflux Detection upon Selective Compression (RDSC)*". This test is performed by applying firm pressure to the vessels in concern close to their entry to the abdomen. A blunt instrument is employed to compress the vein against firm structures of the abdominal wall (or an external object as the surgeon's hand applied externally to abdominal wall against the vein and instrument), (Fig. 6). The patient is then instructed to cough. Disappearance of the previously heard reflux signal means that the compressed vein(s) is the one involved in the pathology at the time of the operation.

The RDSC test is done first by compressing the ISV. Disappearance of the reflux points to possible isolated pathology in this route. If the reflux persists, more dissection across the axis of the ISV is done to include possible missed accessory veins then the test is repeated. If the signal continues to persist, the test is done for the ESV route alone. Compression is applied to the terminal end of the inferior epigastric vein and the patient is instructed to cough. Disappearance of reflux indicates isolated ESV pathology. If the reflux signal persists, the test is done with both ISV and ESV routes compressed simultaneously. Further persistence points to reflux in other routes, e.g. deferential.

In ISV disconnection, the dissection of the bundle of ISV route veins proceeds cephalad. This requires mobilization of the sigmoid and descending colon to expose the veins underneath, (Fig. 7). The operating table is tilted sideways 30° so that the left side of the patient is higher and into a 30° Trendelenburg position. This utilizes the weight of the left colon as an intrinsic retractor which exposes the field and facilitates dissection. As the

dissection progresses the dissected vein bundle becomes longer. It becomes necessary to keep the vein bundle elevated to facilitate its dissection from the surrounding extraperitoneal tissue and to expose communicator veins. This is achieved by introducing a prolene suture from outside the abdomen to loop around the vein bundle before exiting again to the outside providing a dynamic elevation system. This method facilitates dissection, frees 2 instruments for bimanual manipulation of structures, and obviates the need for a fourth port, (Fig. 8).

As dissection progresses cephalad, a wide margin of the "venous ablation field" is always maintained (about one inch on each side). Meanwhile, communicator veins (e.g. testiculo-colonic and testiculo-ureteric) continue to appear as they join the ISV, (Fig. 9)..They are either coagulated by diathermy or clipped before they are divided. Veins of significant size require excision of a long segment of their length to ensure disconnection.

A minimum of 10 cm of the length of the vein bundle is totally freed and elevated above the posterior abdominal wall. In the actual setting, the excised segment was always quite longer than this pre-decided minimum. The usual endpoint is met when the ISV turns deeply to join the renal vein. Clips are applied at this point and caudally at the starting point then the vein bundle between clips is excised and removed outside the abdomen, (Fig. 10).

The ESV route is managed by occluding the terminal end of the inferior epigastric vein by clips or diathermy coagulation as was previously described by Dudai et al⁽⁶⁾. In the original design of the procedure, it was planned to explore the deferential vein if reflux persisted after occlusion of the inferior epigastric but this was not encountered in any patient.

Postoperative assessment

All patients were assessed by: clinical evaluation, Duplex scan and semen analysis. The follow-up evaluation was done 3 to 11 months after surgery. Clinically; symptoms (pain, swelling), signs (varicocele, hydrocele), and conception were assessed.

RESULTS

Operative

The duration of the operation ranged between 75 and 130 minutes (the mean was 95.3 ± 44.9). The duration of the procedure inversely correlated to the order of the case in the series, i.e. steeping learning curve ($p < 0.01$).

No major difficulties were encountered during the procedure. Dealing with the artery presented a difficulty in a few cases. The rule was to identify the artery (on basis of its visible pulsations) and spare it when possible. The need to dissect a long segment of the vessels made continuous

care about the artery difficult although the artery and vein were diverging as the dissection proceeded cephalad yet the wide dissection field made maintained identification of the artery throughout the procedure difficult. One solution was to isolate the artery by a prolene thread introduced from outside the abdomen (Fig. 5).

In a few cases, the anatomical relations between the artery and veins were not favorable particularly when the veins were adherent to the artery, winding around it and frequently communicating across its length. To avoid compromising the venous ablation process, a maintained Doppler-detected arterial signal in the cord (with the same intensity) upon compression of the artery was an indication to safely include it in the ablative process. This event occurred in 3 cases in this study. A situation where compression of the suspected vessel produced cord silence or reduced signal intensity was not encountered in the course of the study.

Occasionally, the exposure of the vessels presented difficulties particularly in obese patients. This was made even worse with gradual progression cephalad due to increased bulk of tissue and depth of dissection field. Solutions were in the form of adjusting position of the patient and locations of the ports (see technique). The progressive difficulty in manipulating a long segment of the vein bundle as dissection proceeded was addressed by applying dynamic suspension of the vein bundle from outside (see technique). As the procedure involved marked extraperitoneal dissection, any degree of bleeding was observed to stain the whole field and reduce illumination. Accordingly, care was always taken to avoid such an event. No major intraoperative complications such as bleeding, bowel injury or others were encountered.

Postoperative

No major postoperative complications were observed. Delayed bowel function occurred in 2 patients. Recovery was eventless in most cases. All patients were discharged within 48 hours of the procedure.

Follow-up

Pain was relieved in all the patients who complained of it. Conception occurred in 2 cases (4 and 7 months after the procedure). Varicocele was relieved in all cases (on clinical and Duplex basis). Semen parameters significantly improved in general, particularly motility and count (range: 9,000,000 to 98,000,000, average: $49,600,000 \pm 26,310,000$). The sperm count was above 20,000,000/ml in 13 patients and reached normal range in 9 patients. In one patient improvement was not considered significant. None of the patients developed hydrocele.

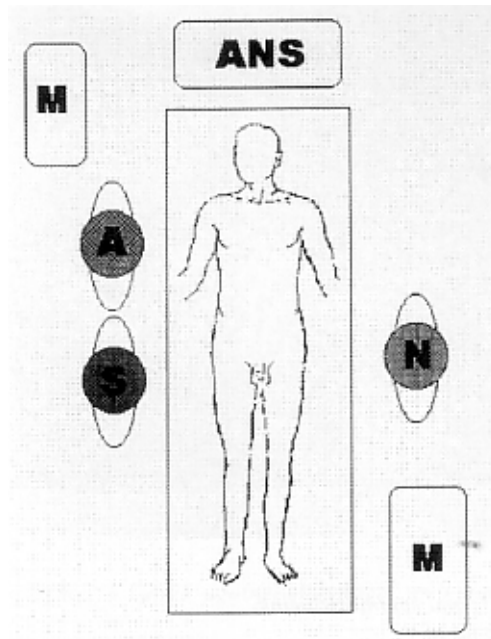


Fig. 1 : Positions in the OR (S: surgeon, A: assistant, N: nurse, M: monitor and ANS: anesthetic set)

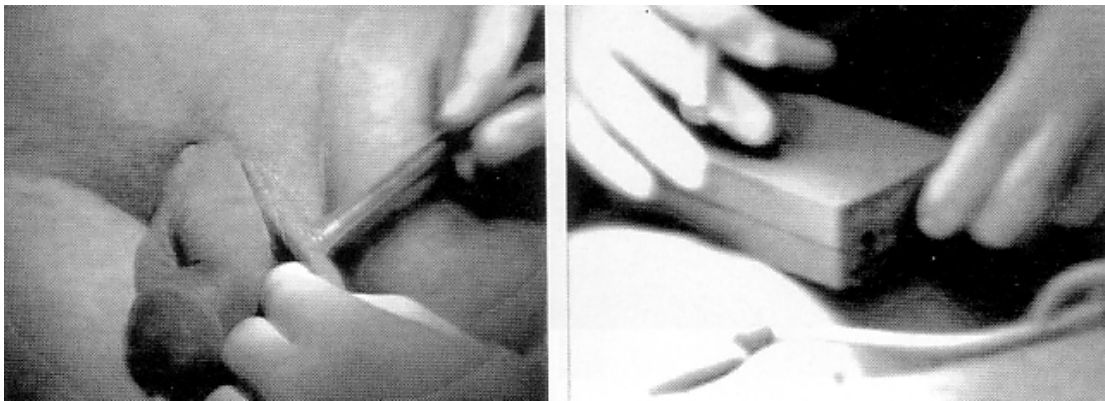


Fig. 2 : Intraoperative Doppler

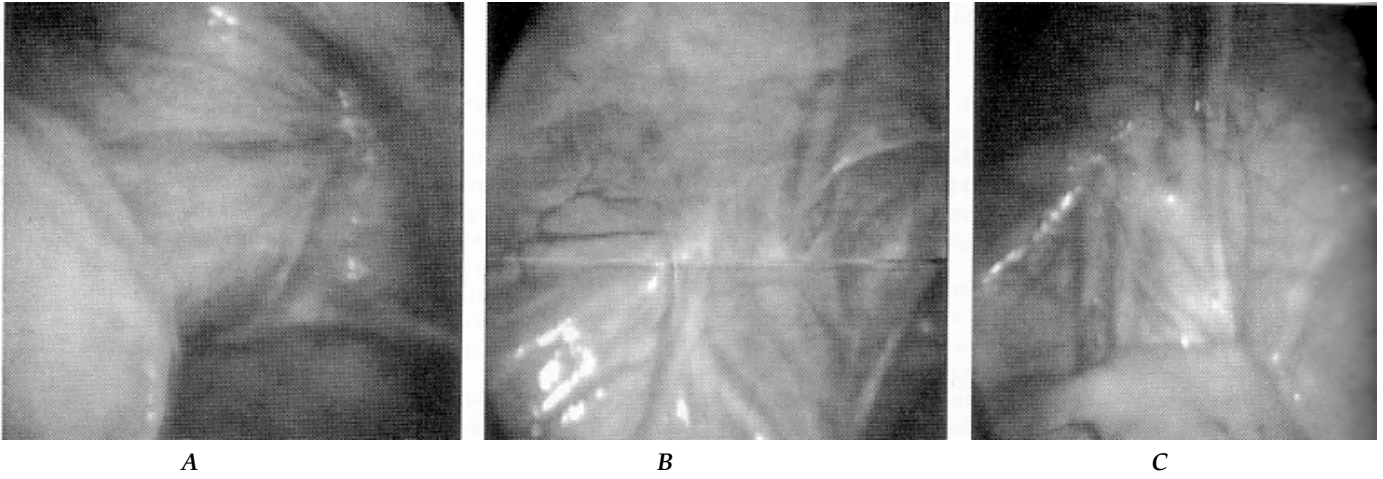


Fig. 3 : Anatomy
A : the more common pattern.
B : prominent inferior epigastric and external spermatic veins.
C : markedly dilated both systems, ISV and ESV.

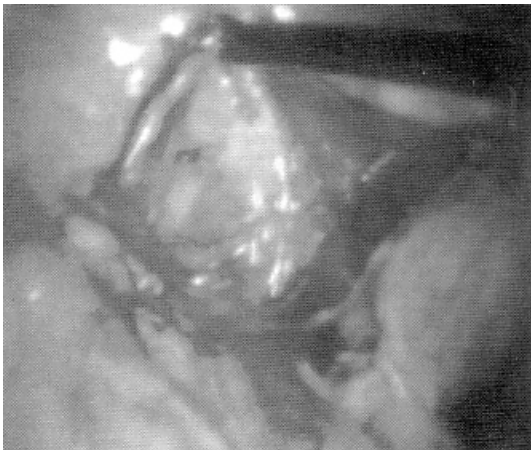

Fig. 4: Dissection and elevation of venous bundle

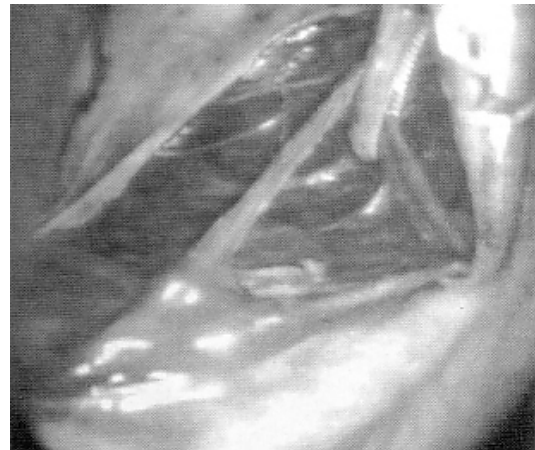

Fig. 5: Isolation of the artery (the vein is clamped, the artery is isolated by a Prolene thread).

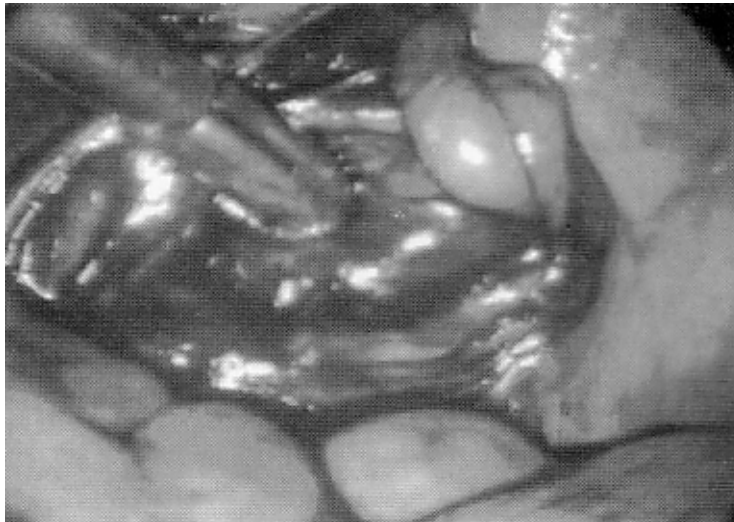
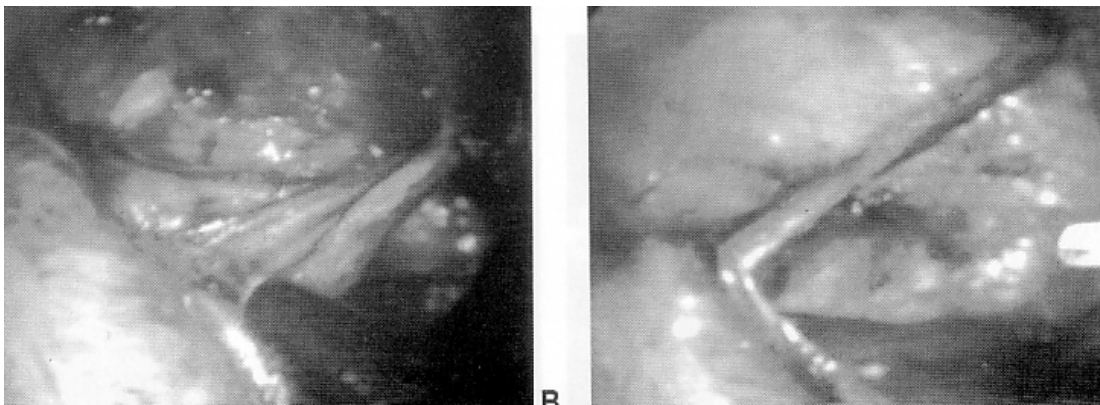


Fig. 6 : Compression of the ISV bundle against abdominal wall during the RDSC test.



A

B

Fig. 7 : Steps in cephalad dissection of the ISV bundle and mobilization of the colon to expose the vein



Fig. 8: Suspension of the ISV bundle by Prolene stitch.

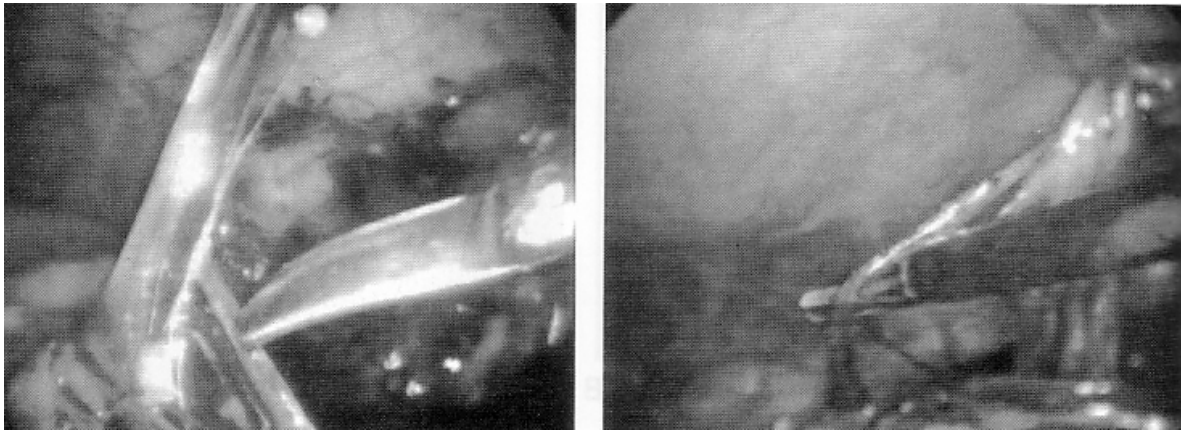


Fig. 9: Communicator veins detected during dissection and controlled by diathermy coagulation.

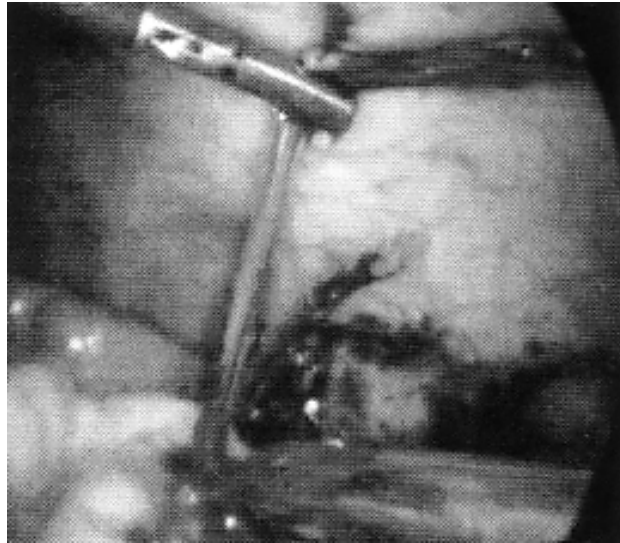


Fig. 10: Applying clip to upper end of the ISV (observe lower pole of spleen).

DISCUSSION

The exact etiology of varicocele is not settled. The proposed etiological factors that are believed to explain the majority of cases are controversial. On the other hand, those factors that are supported by solid evidences explain only a few sporadic cases. The main factor in the first group is absence or incompetence of the valves in the ISV leading to reflux and varicocele^(7,8). However, several investigators reported absence of these valves in the majority of normal men; a finding which weakens the original hypothesis⁽⁹⁾.

An example of the proposed etiological factors that explain only a few cases of varicocele is proximal venous obstruction, e.g. the nutcracker phenomena⁽⁸⁾. Obstruction in these cases may occur proximally due to compression of the renal vein by superior mesenteric artery or distally due to compression of left common iliac vein by common iliac artery.

Regardless of the exact etiological mechanism, venous reflux is a constant feature in varicocele which is observed in all clinical cases. This reflux probably becomes more frequent and more serious with time, i.e. occurs with lower increases in intra-abdominal pressure. With the progress of disease, the flow is actually reversed in the involved routes which results in testicular damage⁽¹⁰⁾.

The majority of current surgical approaches to varicocele share one basic principle: *"Interruption of pathological (incompetent, refluxing) venous drainage route of the testis (traditionally believed to be the internal spermatic vein) diverts venous drainage to competent routes"*⁽¹⁰⁾.

Two groups of factors contribute to recurrence of varicocele. The first group (recurrence factors 1 and 2, or RF1 and RF2) lead to recurrence due to incomplete elimination of the already existing refluxing venous channels at the time of surgery. The other group of factors (recurrence factors 3 and 4 or RF3 and RF4) lead to recurrence due to development of collaterals after elimination of the original source of reflux. A comprehensive surgical approach to varicocele that aims at reducing recurrence should address the four factors.

The RF1 is incomplete interruption of the ISV route. This may be due to technically ineffective interruption, an error that was reported in 27% of recurrences⁽¹¹⁾, or missing one of a double or triple ISV. The latter is probably more common than it was previously recognized. In fact, the ISV is less frequently a single vein. Morag et al⁽¹²⁾ reported that left ISV (between renal vein and internal ring) was single in only 50 out of 104 patients. A double or triple ISV was reported to cause 50% of the recurrences after surgery⁽¹¹⁾.

The RF2 is persistence of refluxing venous routes other than the ISV. Traditionally, the ISV is considered the only

route involved in the pathogenesis of varicocele. This concept has been recently challenged as other drainage routes were reported to be involved as well^(13,14). Extrafunicular veins are now recognized as potential causes of varicocele, particularly the external spermatic vein (ESV). On anatomical basis, ESV was reported by several authors to be large and prominent in 16 to 70% of patients^(1,15,16). Radiographically, Hill and Green⁽¹⁷⁾ reported refluxing ESV in more than 50% of varicocele cases with the ESV being the only refluxing vein in 60%. The ESV was also reported to account for 20% of the cases of varicocele recurrence⁽⁸⁾. More strikingly, ISV interruption in the distal nutcracker phenomenon, where the ESV is the pathological route, can be disastrous as the ISV is the competent route in these cases⁽⁸⁾.

Previously, RF1 and RF2 were approached by 2 solutions that aimed at confirming completion of interruption of the pathological routes intraoperatively. The first was intraoperative visualization of venous routes by venography or blue venography (employing Methylene blue) to confirm completion of interruption^(7,10). However, the value of venography in reducing recurrence rate was recently questioned^(18,19). One important factor in intraoperative venography is that it reflects anatomical but not functional status of venous drainage, i.e. it shows dilated veins but not the dynamically refluxing veins. The presence of either of these two criteria does not necessarily entail the presence of the other⁽²⁰⁾. The second approach was expanding the intervention to include other venous drainage routes. The ESV has been routinely included in the interruption process by some surgeons. This was done both in open surgery⁽²¹⁾ and laparoscopically⁽⁶⁾. Other surgeons included deferential veins as well when they were observed to be dilated⁽²²⁾.

In this study, the intraoperative assessment of involved veins and completeness of elimination of reflux was approached by employing Doppler testing for reflux and designing a test that allowed individual testing of potentially involved veins (the RDSC test). The RDSC test, introduced in this work, allowed mapping of the refluxing venous routes. This step was the basis for the process of selective disconnection. In other words, functional testing replaced anatomical judgement of veins and functional selection of the veins to interrupt replaced the routine interruption previously practiced. The use of spinal anesthesia was mandatory for patient's cooperation during functional testing. Spinal anesthesia was recently shown to be effective and safe in selected lower abdominal laparoscopic procedures⁽²³⁻²⁵⁾.

The transperitoneal laparoscopic access is the most suitable one for the presented procedure. Laparoscopy allows good visualization (and magnification) and selective testing, and provides access to most of the venous routes that are potentially involved in varicocele bilaterally. All the

other approaches, including the laparoscopic extraperitoneal one, have limitations in accessing one or more routes.

The second group of recurrence factors are due to development of collaterals after complete elimination of reflux. This occurs when the necessary precautions to prevent future collaterals are not intentionally taken since simple interruption is not likely to produce a complete and lasting effect. The two factors which encourage future collateralization are: persistence of ISV communicator channels (RF3) and the narrow pressure front (RF4).

The RF3 is ISV communicators. Normally, these venous channels connect the ISV with the neighboring plexuses. They include: testiculo-ureteric, testiculo-colonic, testiculo-renal, and testiculo-testicular veins. The ISV ends by dividing into 2 terminal divisions at the level of L3. The medial division joins the renal vein (on the left side) or inferior vena cava (on the right side). The lateral division joins renal capsular venous circle. This is a constant finding which has been described by many authors^(9,26,27). The connections of the ISV with ureteral and colonic plexuses, as well as the contraateral ISV have also been described as common findings^(9,28,29). These communicating veins play an important role in recurrence. Following simple interruption of the ISV, they develop into replacement (collateral) channels that restore the reversed flow to the caudal segment of ISV bypassing the site of interruption and employing neighboring plexuses (colonic, renal, ureteral or contralateral testicular) as bridges. This mechanism was reported in 18% of cases of recurrence⁽¹¹⁾. Moreover, the communicator channels were previously reported to contribute to the primary varicocele (prior to intervention) by providing a source for reversed flow in the caudal part of the ISV despite intact valves in the main vein, a condition known as "the aberrantly fed varicocele"⁽³⁰⁾.

The RF4 is the narrow pressure front associated with interruption. It encourages re-establishment of venous flow across the site of interruption. Proximity of veins with a high pressure gradient encourages their communication. In time, this results in development of major channels connecting the two groups.

The second group of recurrence factors (RF3 and RF4) have not probably been addressed before. In this work, they were approached by: 1) Clearing all the veins within an expanded "venous ablation field", and 2) Excising long segments of the ISV as well as significant communicators.

Dissection of the ISV for a long distance and exposing a wide area across its course allow visual identification of communicators and their ablation by coagulation or clips. This process was planned to include all communicating veins and discourage the development of collateral channels. During the course of this study, these communicators were observed to be constantly present, in

good number, in significant sizes, and at all levels of the ISV in all patients. Excising a long segment of the ISV and significant communicators widens the narrow pressure front as well. This discourages re-communication. This action was inspired from comparable situations in venous surgery. One example is splenopancreatic disconnection proposed by Henderson et al⁽³¹⁾ to prevent the development of pancreatic siphon after distal splenorenal shunt for portal hypertension. Another example is the necessity to excise significant segments of the tributaries of the great saphenous vein during surgery for varicose veins of the lower extremity to discourage recurrence after Trendelenburg's operation⁽³²⁾. The steps that were taken to deal with second group of factors (the venous ablation field and widening the pressure front) transformed classical interruption into a rather disconnection procedure.

During this work, an attempt was always considered to spare the artery after its identification by visible pulsation. In the same time, care was taken not to leave any venous channels intact. During this study, it was observed that in the three cases where the artery was transected, evident arterial signals were still Doppler-detected in the cord upon pressure on the artery prior to its clipping. This observation was reported earlier by Zat'ura et al⁽³³⁾. Attempts to preserve the artery were reported by many investigators to be an optional step that is not mandatory. This was supported by the finding of several investigators⁽³⁴⁻³⁸⁾ that no adverse effects were observed on testicular function or structure after testicular artery ligation. Moreover, insisting on sparing the artery has been reported to contribute to a higher recurrence rate^(6,37) due to jeopardized venous interruption. Also, Atassi et al⁽³⁹⁾ reported superiority of Palomo procedure over artery-sparing techniques in results.

In conclusion, this work presents a new approach for varicocele which addresses known causes of recurrence (or persistence) after surgery. The proposed procedure is based on Doppler-guided selective intervention, guarding against future development of collaterals by performing disconnection in place of the conventional interruption (by excising a long segment of vein to widen the pressure front and ablating all existing communicators in the field), and confirmation of completion of the procedure before its conclusion.

Early results of this new technique were impressive. It is hoped that it may contribute to improvement in the outcome of varicocele surgery.

REFERENCES

1. Beck EM, Schlegel PN, Goldstein M: Intraoperative varicocele anatomy: A macroscopic and microscopic study. *J.Urol.*, 148:1190-1194, 1992.
2. Winkelbauer FW; Ammann ME; Karnel F; Lammer J: Doppler sonography of varicocele: long-term follow-up after

venography and transcatheter sclerotherapy. *J Ultrasound Med*, 1994; 13(12):953-8.

3. Kattan S: Incidence and pattern of varicocele recurrence after laparoscopic ligation of the internal spermatic vein with preservation of the testicular artery. *Scand J Urol Nephrol*, 1998, 32(5):335-40.
4. Trum JW, Gubler FM, Laan R, van der Veen F: The value of palpation, varicoscreen contact thermography and colour Doppler ultrasound in the diagnosis of varicocele. *Hum Reprod* 1996 Jun 11:6 1232-5.
5. Preutthipan S, Nicholas OA: Comparative study between scrotal physical examination and scrotal ultrasonography in the detection of varicocele in men with infertility. *J Med Assoc Thai*, 1995, 78:3, 135-9.
6. Dudai M, Sayfan J, Mesholam J and Sperber Y: Laparoscopic simultaneous ligation of internal and external spermatic veins for varicocele. *J.Urol.*,153:704-705, 1995.
7. Gill B, Kogan SJ, Maldonado J, Reda E, Levitt SB: Significance of intraoperative venographic patterns on the postoperative recurrence and surgical incision placement of pediatric varicoceles. *J.Urol.*, 144:502-505, 1990.
8. Coolsaet BLRA: The varicocele syndrome: venography determining the optimal level for surgical management. *J. Urol.*, 124:833, 1980.
9. Wishahi MM: Detailed anatomy of the internal spermatic vein and the ovarian vein. Human cadaver study and operative spermatic venography: clinical aspects. *J Urol*, 145(4):780-4, 1991.
10. Campobasso P: Blue venography in adolescent varicolectomy: A modified surgical approach. *J.Ped.Surg.*, 32(9):1298-1301, 1997.
11. Belli L, Arrondello C, Antronaco R, Curzio D, Morosi E, Fugazzola C: Venography of postoperative recurrence of symptomatic varicocele in males. *Radiol Med (Torino)*, 1998, 95:5, 470-3.
12. Morag B, Rubinstein ZJ, Goldwasser B, Yerushalmi A and Lunnenfeld B: Percutaneous venography and occlusion in the management of spermatic varicoceles. *AJR*, 143:635-640, 1984.
13. Sayfan J and Adam YG: Intraoperative internal spermatic vein phlebography in the subfertile male with varicocele. *Fertil. Steril.*, 29:669, 1978.
14. Sayfan J, Adam YG and Soffer Y: A new entity in varicocele subfertility: the "cremasteric reflux." *Fertil. Steril.*, 33:88, 1980.
15. Goluboff ET; Chang DT; Kirsch AJ; Fisch H: Incidence of external spermatic veins in patients undergoing inguinal varicolectomy. *Urology* 1994 Dec;44(6):893-6.

16. Albayrak S; Can C; Sarica K: Extended vein ligation: a new aspect of the surgical treatment of varicocele. *Urol Int*, 51(4):220-4, 1993.
17. Hill JT and Green NA: Varicocele: a review of radiological and anatomical features in relation to surgical treatment. *Brit.J.Surg.*, 64:747, 1977.
18. Palmar LS; Cohen S; Reda EF; Gill B; Franco I; Kogan SJ; Levitt SB: Intraoperative spermatic venography reconsidered. *J Urol*, 154(1):225-7, 1995.
19. Kass E, Marcol B: Results of varicocele surgery in adolescents: a comparison of techniques. *J.Urol.*, 148:694, 1992.
20. Franco G, Iori F, de Dominicis C, Dal Forno S, Mander A, Laurenti C: Challenging the role of cremasteric reflux in the pathogenesis of varicocele using a new venographic approach. *J Urol*, 1999, 161:1, 117-21.
21. Sayfan J, Soffer Y, Orda R: Varicocele treatment: prospective randomized trial of three methods. *J.Urol.*, 148:1447, 1992.
22. Belloli G; D'Agostino S; Musi L; Campobasso P: Adolescent varicocele: operative anatomy and tricks for successful correction. *Eur J Pediatr Surg*, 1995, 5(4):219-21.
23. Vaghadia H; Viskari D; Mitchell GW; Berrill A: Selective spinal anesthesia for outpatient laparoscopy. I: characteristics of three hypobaric solutions. *Can J Anaesth*, 48(3):256-60, 2001.
24. Chilvers CR; Goodwin A; Vaghadia H; Mitchell GW: Selective spinal anesthesia for outpatient laparoscopy. V: pharmacoeconomic comparison vs general anesthesia. *Can J Anaesth*, 48(3):279-83, 2001.
25. Schmidt J; Carbajo MA; Lampert R; Zirngibl H: Laparoscopic intraperitoneal onlay polytetrafluoroethylene mesh repair (IPOM) for inguinal hernia during spinal anesthesia in patients with severe medical conditions. *Surg Laparosc Endosc Percutan Tech*, 11(1):34-7, 2001.
26. Seyferth W, Jecht E, Zeiter E: Percutaneous sclerotherapy of varicocele. *Radiology*, 139:335, 1981.
27. Walsh PC, White RI Jr: Balloon occlusion of the internal spermatic vein for the treatment of varicoceles. *JAMA*, 246:1701, 1981.
28. Narayan P, Amplatz K, Gonzalez R: Varicocele and male subfertility. *Fertil. Steril.*, 36:92, 1981.
29. Gonzalez R, Narayan P, Castaneda-Zuniga WR, Amplatz K: Transvenous embolization of the internal spermatic veins for the treatment of varicocele scroti. *Urol. Clin. N. Amer.*, 9:177, 1982.
30. Marsman JW: The aberrantly fed varicocele: frequency, venographic appearance, and results of transcatheter embolization. *AJR Am J Roentgenol*, 164(3):649-57.
31. Henderson JM; Warren WD; Millikan WJ; Galloway JR; Kawasaki S; Kutner MH: Distal splenorenal shunt with splenopancreatic disconnection. A 4-year assessment. *Ann Surg*, 210(3):332-9, 1989.
32. Flye MW: Venous Disorders. In David C. Sabiston, Jr. and H. Kim Lyerly (editors): *Textbook Of Surgery: The Biological Basis of Modern Surgical Practice*, 1997, W.B. Saunders. Philadelphia, 15th ed.
33. Za'ura F; Student V; Fiala R; Vrtal R: Personal experience with peroperative study of testicular blood flow in laparoscopic surgery of varicocele. *Rozhl Chir*, 76(9):419-420, 1997.
34. Matsuda T, Horii Y, Yoshida O: Should the testicular artery be preserved at varicocelectomy? *J.Urol.*, (5 Pt 2), 149:1357-60, 1993.
35. Ross LS, Ruppman N: Varicocele vein ligation in 565 patients under local anesthesia: a long-term review of technique, results and complications in light of proposed management by laparoscopy. *J.Urol.*, part 2, 149:1361, 1993.
36. Rauchenwald M; Colombo T; Mischinger HJ; Petritsch PH; Hubmer G: Laparoscopic ligation of spermatic vessels in varicocele. *Urologe A*, 1994;33(1):58-61.
37. Parrott TS and Hewatt L: Ligation of the testicular artery and vein in adolescent varicocele. *J.Urol.*, 152 (2 Pt 2):791-3, 1994.
38. Yamamoto M; Tsuji Y; Ohmura M; Hibi H; Miyake K: Comparison of artery-ligating and artery-preserving varicocelectomy: effect on post-operative spermatogenesis. *Andrologia* 1995 Jan-Feb;27(1):37-40.
39. Atassi O; Kass EJ; Steinert BW: Testicular growth after successful varicocele correction in adolescents: comparison of artery sparing techniques with the Palomo procedure. *J Urol*, 1995, 153(2):482-3.