

LAPAROSCOPIC EVALUATION OF THE CONTRALATERAL ASYMPTOMATIC GROIN IN PRE-SCHOOL CHILDREN WITH SELECTIVE HERNIOTOMY

By

Saleh El-Awady, Hesham Sharaf El-Din and Khaled Kandeel

Department of General Surgery , Faculty of Medicine
Mansoura University, Egypt .

The role of contralateral exploration in pediatric unilateral inguinal hernia repair remains controversial . The purposes of this study were : firstly to evaluate the laparoscopic contralateral groin to ascertain the incidence of contralateral patent processus vaginalis through the ipsilateral hernial sac at herniorraphy .

Secondly , evaluation of objective reliable method for selective herniotomy (PPV \geq 2 cm) .

Laparoscopic evaluation was successful in 65 patients out of 80 patients (81%) .

The contralateral processus was closed in 34 (52%) patients, patent but covered by peritoneal diaphragm in 14 (22%) patients and clearly patent in 17 (26%) patients. Proping of the clearly patent processus vaginalis using the C.V.P. guide wire revealed 9 patients with PPV < 2 cm while 8 patients with PPV \geq 2 cm for those patients selective herniotomy was performed .

The patients were followed up for maximum 2 years without reported hernial recurrences but single patient developed contralateral hernia . There was no complications related to insufflation , laparoscopy or C.V.P. guide wire .

In this study , the sensitivity , specificity and accuracy for laparoscopic detection of PPV were 96.8% , 100 % and 98 % respectively .Also , the sensitivity , specificity and accuracy for selective herniotomy using the C.V.P. guide wire during laparoscopy were 90% , 100% , 98.4% respectively .

So, not only laparoscopic evaluation of the contralateral side via involved hernial sac at herniorraphy should be considered in all pediatric patients at herniorraphy but also selective herniotomy for cases of PPV \geq 2cm measured objectively .

Key words : hernia - laparoscopy - processus vaginalis

INTRODUCTION

In 1955 , Rothenberg and Barnett ⁽¹⁾ introduced the concept of routine exploration of the contralateral asymptomatic side in infants and children with unilateral inguinal hernia .

Since then, there is a great controversies regarding the true incidence of contralateral patent processus vaginalis and its fate in relation to the latter development of symptomatic hernia , the reliable diagnostic method that spares the risk of injury of contralateral cord structures and lastly the policy to follow (the watch and see , the non-selective herniotomy or selective herniotomy) .

The incidence of patent contralateral processus vaginalis varies among series.

In 1984 Rescorla and Grosfeld ⁽²⁾ reported that the incidence is 88% in the neonatal period .

Sparkman ⁽³⁾ reported an incidence of 57% among children at various ages .

Jonna ⁽⁴⁾ reported an incidence of 75% in the first year of life and a rate of 58% in preschool age .

The established rate of patency of processus vaginalis in adult autopsies is 15 % to 30% ⁽⁵⁾ .

The later development of a symptomatic hernia varies among series according to targeted age group and duration of follow up :

In Surana and Puri series ⁽⁶⁾ it was 10.3% (116 patients aged 1 week to 6 months with 7 years follow up) .

In Gicen and Rubin series ⁽⁷⁾ it was 5.8% (850 patients aged 1 to 12 years and 2 years follow up) .

In Kemmotsu et al., series ⁽⁸⁾ it was 11.6% (1052 patients and 1 to 11 years follow up) .

In Mc Gregor et al ., series ⁽⁹⁾ it was 22% (11 to 32 years follow up). In Muraji et al, series ⁽¹⁰⁾ it was 5.8% (7 years follow up) while in Nazir and Saebo series⁽¹¹⁾ it was 10.6% (20 to 29 years follow up) .

Kemmotsu and his colleagues ⁽⁸⁾ also reported that contralateral hernia develops in 50% of patients within one year and 80% within two years after the initial procedure .

The contralateral side can be evaluated with many methods, open exploration was the first method and still used by some pediatric surgeons. The exploration is positive if there is patent processus vaginalis greater than 1 cm in length ⁽⁴⁾ , 1.5 cm ⁽¹²⁾ or 2 cm ⁽¹³⁾ .

Controversies against open exploration include the potential or the actual damage to the vas deference and /or testicular vessels ⁽¹⁴⁾ with the latter poor effect on testicular development and fertility . The incidence of testicular damage and malposition in Surana and Puri series ⁽⁶⁾ reached up to 10% . Another controversy is that in many cases of patent processus , the internal ring is covered by diaphragm or a veil of peritoneum that prevent later development of symptomatic hernia ⁽¹³⁾ .

Another method of exploration the contralateral side is pneumo- peritoneum (Goldstein test) , however this method is associated with high false negative results that reaches up to 80% ⁽¹⁵⁾ , a more or less similar is herniogram which also revealed high incidence of negative results ⁽⁴⁾ .

Recently laparoscopy was introduced as the method of choice in exploring the contralateral side for the following advantages : It is highly sensitive and specific with reduction of the negative exploration rate to nearly zero ,it is rapid and does not significantly increase costs if reusable instruments are used ^(16,17,18) .

Traditional laparoscopy have been criticised for the need for additional incision(s) and the unnecessary patient exposure to morbidity (when the laparoscope is placed through the umbilicus) .To avoid this , laparoscopy can be performed through the opened ipsilateral hernial sac (13 and 12) . This technique needs a small (4 mm or 2.7 mm) side viewing (30 degrees or 70 degrees) laparoscopy. The positive rate of a contralateral patent processus in Wulkan et al ⁽¹³⁾ and Geiger ⁽¹²⁾ series was 39% and 32% respectively .

There are two additional factors which can be evaluated during laparoscopy . The first one is the length of the patent processus which can be calculated by direct vision (if the long axis of the processus come to lie line with the axis of vision of the laparoscope) but it is a rough method , or by sounding of the sac ⁽¹²⁾ .

The second , is the presence of a veil (diaphragm) of peritoneum at the internal ring postnatal , that its presence prevents later development of a clinical hernia ^(13,12) .

PATIENTS AND METHODS

From March 1999 to September 2000, 80 children (aged 6 months to 6 years) presented to the pediatric surgery unit and general surgery department in Mansoura University hospital with unilateral hernia .

Technique : Operative intervention was performed under general anaesthesia with endotracheal intubation , with gastric decompression using nasogastric tube and bladder evacuation by suprapubic compression . Ipsilateral inguinal exploration was then performed . The symptomatic sac was identified and dissected to the level of the internal ring , the sac was then opened and a 5 mm reusable blunt Trocar, cannula was introduced with CO₂ insufflation to 6-10 mmHg and the patient was placed in the Trendelenberg position (Fig A) . The contralateral internal ring was examined using a 4 mm 30 degrees telescope (Fig B) . A patent processus vaginalis was diagnosed when an obvious opening through the internal ring was seen or if bubbles or fluid were seen coming out of the deep ring after external squeezing of the scrotum towards the inguinal region . The presence of a peritoneal fold (or diaphragm) overlapping the deep ring was recorded (Fig C). If the deep ring was clearly opened , the length of the processus vaginalis was determined either by direct vision if the axis telescopic vision come in line with the axis of the processus, otherwise, the central venous

pressure set (cannula , guide wire) was used by pushing under-vision the cannula into the abdominal wall near the deep ring , subsequently the guide wire is introduced and directed towards the deep ring (Fig D). The telescope and C.V.P set were then removed followed by abdominal desufflation

Ipsilateral high ligation of the hernia was then performed .Lastly the contralateral side was explored with high ligation of the processus vaginalis when the deep ring was clearly opened and the length of the processus was more than 2 cm .

Data was analysed using SPSS package system under windows .

RESULTS

Of the 80 patients who under went attempted laparoscopic evaluation , the procedure was unsuccessful in 15 (19%) patients due to narrow hernial orifices or torn , friable sac so the patients were excluded .

The epidemiologic criteria of remaining 65 patients are summerized in (Table 1)

Table (1):Descriptive data of 65 patients with unilateral hernia

Age :	Range	6 months - 6 years
	Mean	2.3 years \pm 0.6 m
	Median	2.5 years
Sex :	Male	56
	Female	9
Side	Rt	34
	Lt	31
Side & sex :	Rt ; male	29
	female	5
	Lt ; male	27
	female	4

The result of laparoscopic evaluation of contralateral side is shown in (Table 2) .

Table (2):State of contralateral deep ring.

Variable	Number	(%)
Closed	34	52
Patent processus	31	48
Clearly patent	17	26
Peritoneal diaph.	14	22

The clinico pathologic associations of the different states of deep ring are summerized in (Table 3) .

Table (3):Clinico-pathologic associations of deep ring states

	Closed		Patent proces. Vag.		Clearly patent		Covered patent	
	(No)	(%)	(No)	(%)	(No)	(%)	(No)	(%)
Sex:male	33	94.11	24	77.4	13	76.4	11	78.5
female	2	05.89	7	22.6	4	23.6	3	21.5
Side : Rt	17	50.0	18	4.8	7	41.1	10	71.4
Lt	17	50.0	14	45.2	10	58.9	4	28.6
Sex& side:								
Rt: male	17	94.44	14	82.3	6	85.7	8	80.0
female	1	5.56	3	16.7	1	14.3	2	20.0
Lt : male	15	93.75	10	71.4	7	70.0	3	75.0
female	1	6.25	4	28.6	3	30.0	1	25.0

Proping of the clearly patent processus vaginalis with C.V.P guide wire revealed ; 9 cases with PPV less than 2 cm (13.8%) and 8 cases with PPV \geq 2 cm or more in length (12.2% of all cases) for whom open ligation was performed

The extra time spents for laparoscopy \pm proping of the sac was 5 to 15 minutes .

No complications related to open herniotomy, laparoscopy or C.V.P guide wire had been detected .

The patients were followed up regularly at the outpatients clinic for symptomatic herina from a minimum of 6 months to a maximum 2 years .

There was only one case that developed symptomatic hernia (the sac was judged to be less than 2 cm) with no hernial recurrences .

The efficacy of laparoscopy in detection of PPV is shown in (Table 4).

Table (4) : Efficacy of laparoscopy for diagnosing PPV

Variable	%
Sensitivity	96.8
Specificity	100
Positive predictive value	100
Negative predictive value	97
Accuracy	98

In the other hand the efficacy of laparoscopy in detection of need for operative intervention is shown in (Table 5) (PPV \geq 2 cm) .

Table (5) : Laparoscopic efficacy to detect PPV \geq 2 cm.

Variable	%
Sensitivity	90
Specificity	100
Positive predictive value	100
Negative predictive value	98.2
Accuracy	98.4

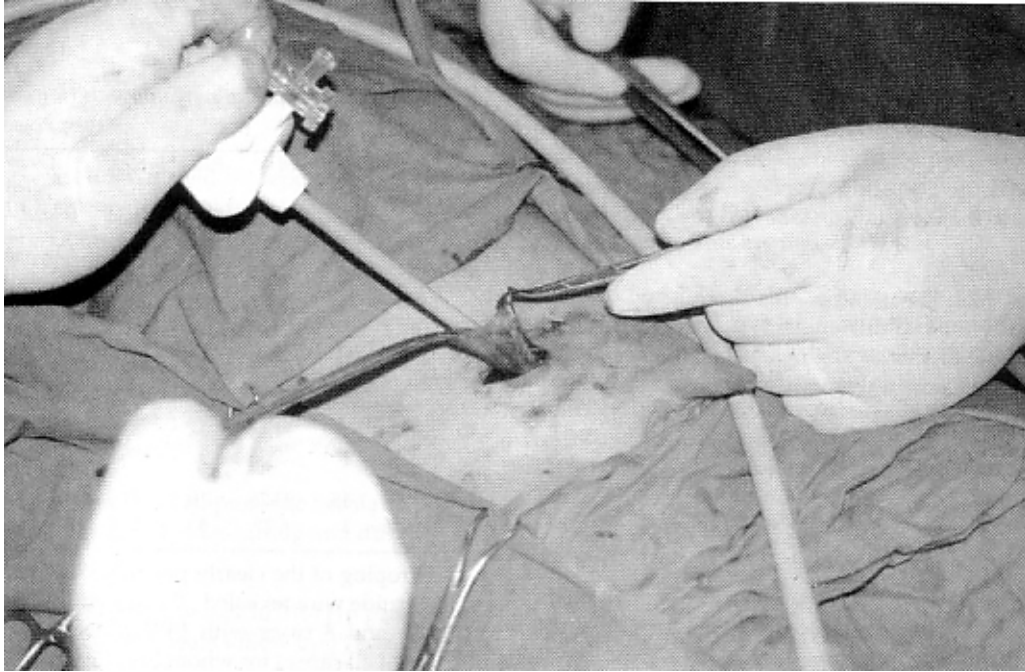


Fig (A)

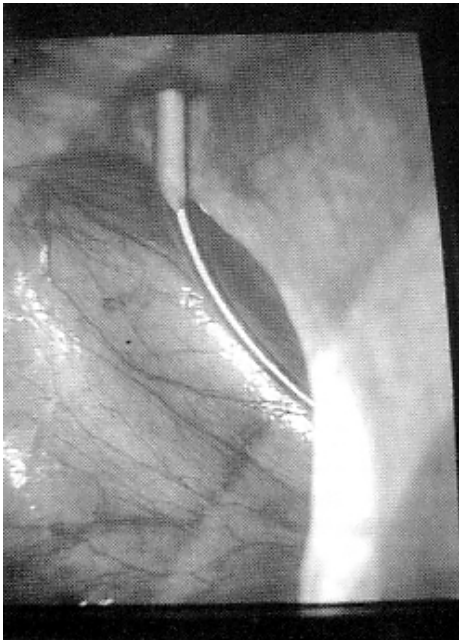


Fig (B)

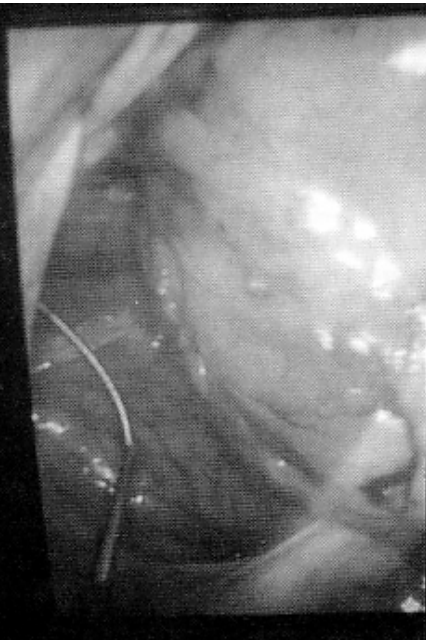

Fig (C)

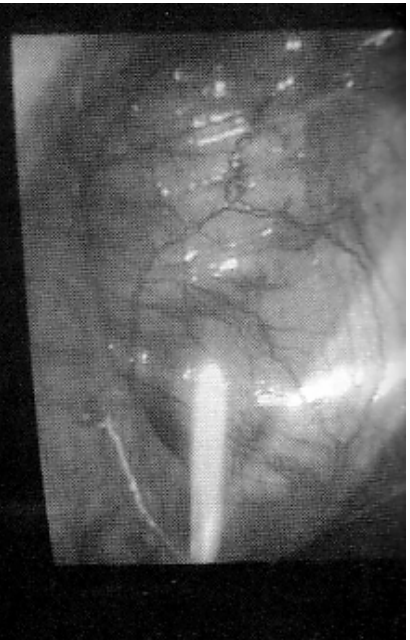


Fig (D)

DISCUSSION

Although herniotomy for inguinal hernia is the commonest operation performed in pediatric age group , decision making regarding contralateral exploration for the asymptomatic side still a matter for controversy since the fate of the processus vaginalis remains exactly , unknown⁽⁶⁾.

The introduction of laparoscopy allowed more safe and accurate assesment of the processus vaginalis ⁽¹⁹⁾ .

As in Wulkan et al ., ⁽¹³⁾ and Geiger series⁽¹²⁾, our study showed that utilization of the ipsilateral hernia for exploration was easy , simple and associated with minimal risk to the patient or to the spermatic cord structures .

Also , the added time for laparoscopy was short and moreover the added costs were minimal since the use of reusable instruments .

It has been found a patent processus vaginalis in 48% of cases (22% covered by peritoneal veil and 26% clearly patent) similar to other series utilizing laparoscopy as Geiger ⁽¹²⁾, who found an incidence of 32% that is in contrast to series utilizing open exploration as Rescorla and Grosfeld⁽²⁾ with incidence of 85%. That is low rate of patency diagnosed laparoscopically is related to the efficacy of laparoscopy in detecting the patent processus vaginalis .

Also it has been found that, about 22% of cases of patent processus vaginalis with covered peritoneal veil similar to that reported by Wulkan and his associates ⁽¹³⁾. Thus reducing unnecessary exploration of all cases of PPV .

In our study we tried to select patients for elective inguinal exploration and herniotomy on the basis of absence of overlapping peritoneal fold (which in our opinion acts as an obstacle for the development of the hernia) and length of the sac is 2 cm or more [according to criteria described by Jona ⁽⁴⁾] .

We used for measurment of the length of the sac the C.V.P. cannula and guide wire which is introduced under direct vision and was not associated with risks or morbidity.

Geiger in his series ⁽¹²⁾ utilized a silver probe , while Wulkan et al .,1996 reported the use of a small optical scope introduced through an angiocath .

The follow up period in our series was determined to be 2 years (as Kemmotsu et al ., ⁽⁸⁾ reported that 80% of the symptomatic contralateral hernia will develop within 2years of the initial procedure), although this follow up period is relatively short only one patient developed symptomatic hernia .

In this series the sensitivity , specificity and accuracy of laparoscopy to detect patent processus vaginalis were

96.8%, 100% and 98% respectively similar to that reported by Zigman et al ,⁽²⁰⁾ .

Moreover the uses of selective criteria for operative intervention reveled high rate of accuracy (98.4%) and highly specific (100%) as in Geiger series ⁽¹²⁾ .

So laparoscopic evaluation of the contralateral inguinal region at time of unilateral herniorrhaphy must gain popularity as it reduced the incidence of negative contralateral exploration , is safe and effective and moreover the selection criteria avoid a second operation for hernia with its morbidity and costs .

Hence laparoscopic evaluation of the asymptomatic groin through the involved hernial sac with the selection criteria for operative intervention should be considered in all patients undergoing repair of unilateral hernia .

REFERENCES

1. Rothenberg RE , and Barnett T: Bilateral herniotomy in infants and children . Surgery,1955; 37 : 947.
2. Rescorla FJ and Grosfeld JC: Inguinal hernia repair in the perinatal period early infancy : clinical consideration . J Ped Surgery, 1984 ;19:832.
3. Sparkman RS: Bilateral exploration in inguinal hernia in juvenile patients. Surgery,1962 ;51 : 393.
4. Jona JZ: The incidence of positive contralateral inguinal exploration among preschool children .A retrospective and prospective study . J Ped Surgery, 1996; 31:656.
5. Snyder WH: The infantile inguinal hernia. A bialteral disease? Ped Surgery In Medical Year Book vol III , Chicago, 1962; p:573.
6. Surana R and Puri P: Is contralateral exploration necessary in infants with unilateral inguinal hernia . J Ped Surgery, 1993; 28 :1026.
7. Gicen JP and Rubin SZ: Occurance of contralateral inguinal hernia following unilateral repair in a pediatric hospital . J Ped Surgery, 1989; 24:963.
8. Kemmotsu H, Oshima Y, Joe K,et al.:. The features of contralateral manifestation after the repair of the unilateral inguinal hernia. J Ped Surgery , 1998; 33: 1099.
9. McGregor DB, Halverson K and Mc Vay CB: The unilateral pediatric inguinal hernia ; should contralateral side be explored . J Ped Surgery, 1980; 15 : 313 .
10. Muraji T, Noda T, Higashimoto X, et al ., : Contralateral incidence after repair of unilateral inguinal hernia infants and children . Ped Surg Int, 1993; 8 : 455.
11. Nazir M and Saebo A: Contralateral inguinal hernia development ipsilateral recurrence following unilateral

hernial repair in infants and children. *Acta Chir Belg*, 1996; 96 : 28 .

12. Geiger JD: Selective laparoscopy probing for a contralateral patent processus vaginalis reduces the need for contralateral exploration in inconclusive cases. *J Ped Surgery*, 2000; 8: 1151
13. Wulkan M, Wiener ES, VanBalen N, et al., : Laparoscopy through the open ipsilateral sac to evaluate presence of contralateral hernia . *J Ped Surgery*, 1996; 31 : 1174.
14. Lee SL, DuBois JJ and Rishi M : Testicular damage after surgical groin exploration for elective herniorrhaphy . *J Ped Surgery*, 2000; 2 : 327.
15. Timberlake GA, Oschsner MB, and Powell RW: Diagnostic pneumoperitoneum in pediatric patient with a unilateral inguinal hernia . *Arch Surg*, 1989; 124 : 721 .
16. Lobe TE and Schropp KP: Inguinal hernias in pediatric : initial experience with laparoscopic exploration of the contralateral side .*Ped Surg Int*, 1992; 7: 332.
17. Grossman PA, Wolf SA, Hophin JW et al., : Examination of the internal ring of the children . *J Ped Surgery*, 1995; 30 : 217.
18. Chu C, Chou C, Tsu H et al., : Intraoperative laparoscopy in unilateral hernia repair to detect a contralateral patent processus vaginalis . *Ped Surg Int*, 1993; 8 : 385.
19. Fuen Fer MM, Pitts RM and Georgeson KE : Laparoscopic exploration of the contralateral groin in children. An improved technique. *J Lap Surg*, 1996; 6 51 : 4 suppl 1
20. Zigman AF, Lynch FB and Easter OW: Laparoscopic evaluation of the asymptomatic groin in children at hernioraphy. *Pediat R Endo-Surg. Innovative Techn*, 1998; 2/2 :61-64.