

## THE TIMING OF CHOLEDOCHOLITHOTOMY AND THE TYPE OF BILIARY DRAINAGE AFTER FAILED ENDOSCOPIC RETROGRADE CHOLANGIO-PANCREATOGRAPHY (ERCP) IN CALCULAR OBSTRUCTIVE JAUNDICE.

By

A. H. I. Helmy<sup>1</sup> \*, M. Abbas<sup>1</sup> \*, Y. F. Youssef<sup>1</sup>\*, H. Rizk<sup>1</sup>\*, H. El-Khyat<sup>1\*\*</sup>, S. Fakhery<sup>1\*\*</sup>, M. El-Ghannam<sup>1\*\*</sup> M El-Ansari<sup>1\*\*</sup> & M El-Serafy<sup>2\*\*</sup>, M El-Damarawy<sup>1\*\*\*</sup>.

Departments of Surgery\*, Tropical & Gastroenterology & Hepatology\*\* and Intensive Care\*\*\*, Theodor Bilhraz Research Institute<sup>1</sup>, Giza, Egypt., Kasr El Aini Hospital, Cairo University<sup>2</sup>, Egypt.

**Background:** *The intact gall bladder and biliary tree after failed ERCP is a potential risk factor for the occurrence of biliary complications. The aim of this non-randomized prospective and retrospective study was to evaluate the role of timing of common bile duct exploration and the type of biliary drainage after failed ERCP to clear the bile duct from stones and to prevent the complications.*

**Patients and Methods:** *In this study, 173 patients with calcular obstructive jaundice had ERCP for common bile duct stone extraction. They were divided into two groups. The G1E group was studied prospectively and included 133 patients with 39 failed ERCP whom were transferred for surgery within 24 hrs (immediate referral). The G2E group was studied retrospectively and included 40 patients with 14 failed ERCP, they were referred to department of surgery after 24hrs and up to 12 days (delayed referral). The surgical groups were divided according to the method of drainage into two main groups, the first group (G1S, n=39) included subgroups A & B and the second group (G2S, n=14) included subgroups C & D. The subgroup; A: G1ST (21 patients) had T-tube external drainage, B: G1SS (18 patients) had home made stent internal drainage, C: G2SO (6 patients) had stoma formation internal drainage and D: G2SS (8 patients) had ERCP stent internal drainage.*

**Results:** *Mortality rate was mainly in G2S group (C & D) with delayed referral in which 5 patients died due to Systemic inflammatory Response Syndrome (SIRS) and Multiple Organ Failure (MOF). There was no mortality in G1S group (A & B) with early surgical intervention. Internal drainage revealed more favorable results than the external one in the term of shorter operative procedure and hospital stay with less complication.*

**Conclusion:** *Immediate surgical intervention and internal biliary drainage after failed ERCP revealed more favorable results than delayed and internal ones.*

*Key words:* Cholecystectomy, Obstructive Jaundice, ERCP, CBD Exploration, biliary drainage, SIRS.

### INTRODUCTION

Choledocholithiasis is a common finding in patient with gall bladder stones (1). Bile ducts stones may remain silent to be discovered incidentally during imaging or at the time of a routine cholecystectomy for chronic calcular cholecystitis (2). Alternatively the stones may present with complications in the form of abdominal pain, jaundice cholecystitis, secondary biliary cirrhosis and portal hypertension (3). Several studies have reported that

common bile duct stones (CBD) are the most common cause of obstructive jaundice and cholangitis (1, 3, 4).. Endoscopic retrograde cholangio-pancreatography (ERCP) has become the procedure of choice to prove the diagnosis besides its capabilities of stone extraction and internal biliary drainage (4, 5, 6, 7).

The intact gall bladder and biliary tree after failed ERCP is a potential risk factor for occurrence of cholangitis

which may proceed to fatal septic shock unless the obstruction is relieved (8). The early surgical intervention for biliary drainage after failed ERCP has been mentioned to decrease morbidity and mortality (3, 8). Surgical biliary drainage could be done either externally through T-tube or internally using CBD stent or biliary enteric anastomosis (9, 10, 11, 12).

The aim of this study was to evaluate the timing of exploration of CBD and the type of biliary drainage after failure of ERCP to clear the CBD from stones.

## PATIENTS AND METHODS

This non randomized retrospective and prospective study included 173 patients suffering from obstructive jaundice due to common bile duct (CBD) stones. In all patients the CBD stones were suspected clinically in patients with upper abdominal pain, itching, change of urine and stool colour and diagnosed radiologically by abdominal ultrasound. All patients were subjected to complete clinical and laboratory evaluation including complete blood picture, liver function tests, renal function tests, blood sugar and prothrombin time and concentration (Table 1). The diagnosis of CBD stones was proved during ERCP procedure. Patients were divided into two main ERCP groups (G1E & G2E). Cases with failed ERCP stone extraction were included in the main surgical groups (G1S & G2S), (Table 1, 2 & Fig. 1, 2).

### *ERCP groups*

The ERCP was carried out in 173 patients to visualize the biliary tree, detect and extract the stones and internal drainage of the common bile duct. These cases were divided into two main groups according to the type of study whether prospective or retrospective (Table1).

The first ERCP group (G1E) included 133 patients. They were studied prospectively from January 2000 to May 2002. In this group, patients with failed ERCP procedure were referred to the surgical department within 24 hrs (immediate referral).

The second ERCP group (G2E) included 40 patients. Their records were reviewed retrospectively from January 1999 to January 2000. Patients in this group were referred to the surgical department after 24 hrs and up to 12 days post ERCP failure (delayed referral).

### *Surgical groups*

All patients referred to the surgical department were subjected to a thorough clinical examination and laboratory investigation as a pre-operative assessment for operation. Rapid aggressive resuscitation in the intensive care unit (ICU) was needed for the critically ill patients. In surgically

unfit patients with septic cholangitis a preoperative percutaneous trans-hepatic drainage (PTD) was done as a life saving procedure. Correction of coagulopathy with intra-venous vitamin K, fresh frozen plasma and blood transfusion was done. Antibiotics were continued after referral and postoperatively as required.

Patients in this group were divided into two groups according to the time of referral and to the type of study (Table2).

The first surgical group (G1S) included 39 patients. They had no CBD stent inserted during ERCP. They were referred immediately from the endoscopy unit after failure of the ERCP procedure and subjected to operation within 24 hrs post ERCP (immediate referral). It was divided into two subgroups (A and B) according to the method of biliary drainage.

- The subgroup A (G1ST) includes 21 patients. They had T-tube inserted for external biliary drainage.
- The subgroup B (G1SS) included 18 patients. They had a home made stent inserted for internal biliary drainage. Its length ranged between 15 -20 cm and its size between 10 -16 Fr. It was made using a Naso-Gastric tube or Neleton catheter with radioopaque marker. It was inserted through the incision of the CBD exploration and passed through the ampulla to be felt in the duodenum.

The second surgical group (G2S) included 14 patients who had failed ERCP procedure. They were referred after 24 hrs from failed ERCP and up to 12 days to the surgical department (delayed referral). It was divided into two subgroups (C and D) according to the method of biliary drainage.

- The subgroup C (G2SO) included 6 patients. They had no CBD stent inserted during ERCP procedure and they had stoma formation for internal biliary drainage in the form of choledochodudenostomy.
- The subgroup D (G2SS) included 8 patients. They had internal drainage using the inserted stent for biliary drainage during the ERCP procedure.

Post operatively, critically ill patients were routinely admitted to the ICU to guard against Systemic Inflammatory Response Syndrome (SIRS) and Multiple Organ Failure (MOF). After being clinically and haemodynamically stable they were referred to the in-patient surgical department.

In T-tube patients, the T-tube cholangiogram was performed using diluted urographine under cover of

antibiotic in day 7-10 postoperatively. If there was no residual stones in the CBD with free duodenal filling, the T-tube was clamped and removed on day 9 -12 post operatively. The ERCP stent used was left for 4 -12 weeks and removed endoscopically. The home made stent was usually passed spontaneously through the bowel or removed endoscopically 4 weeks post operatively, if proved by ultrasound (or plain Abdominal X-ray) to be found in place.

#### Abdominal ultrasound scan and evaluation in cholecystolithiasis and choledicolithiasis <sup>(13)</sup>:

The ultrasonographic examination has been done using a convex 3.5MHz linear transducer of Hitachi EUB 515 A with special reference to the liver size and echogenicity. Detailed sonographic examination of the gall bladder has been made with special reference to the wall thickness and the number and size of stones. The CBD has been inspected along its whole length and its diameter has been determined and the presence of stones has been observed. The diameter was measured in the AP diameter. Normally the CBD diameter does not exceed 7mm. The intrahepatic biliary radicals have been observed for any dilatation. The presence of dilatation was evaluated and whether it involves both lobes or not. Colour Doppler was used when necessary to differentiate the CBD from the portal vein and hepatic artery. The diameter of the CBD was evaluated in comparison to the pre-operative findings as well. The stent was evaluated as regards its length, its site and its extent. The intra and extra hepatic biliary dilatation were evaluated as regards the dilatation and the presence or absence of aerobilia.

#### The endoscopic retrograde cholangio-pancreatography (ERCP) <sup>(14)</sup>:

ERCP was performed using Olympus video duodenoscope TJF-240. With the patient anaesthetized using deprivan; a thorough endoscopic examination of oesophagus, stomach, and duodenum was performed and all abnormalities were recorded. Cannulation of the papilla was started with either a standard catheter or sphincterotome according to the operator choice, and pancreatic and biliary ductal systems were visualized by injection of the contrast material and documented radiographically. The following parameters had been recorded: abnormalities of papillae; localization and configuration of duct obstruction; localization of stones; endoscopic radiological pancreatography features and stages of chronic pancreatitis if present; maximum diameter of both the main pancreatic duct and the common bile duct. If visualization of both ductal systems was not successful within several minutes, a guide wire was used for cannulation. Endoscopic precut techniques using needle-knife papillotomy were also resorted to when needed. A

successful diagnostic procedure was attested when a complete pancreatogram and an extrahepatic cholangiogram were obtained. In patients with biliary stones, therapeutic sphincterotomy and insertion of a stent were done in case of failure of stone removal. Stone extraction was performed and attempted in all cases. The gastroenterologist finally had to decide between having another attempt or sending the patient to surgery if stones extraction was failed. In this study ERCP failure was defined as failure to clear the CBD from stones.

## RESULTS

### *The ERCP groups*

All patients had a varying degree of jaundice but no cholangitis. Ultrasonography was positive in only 151 (87%) out of the 173 cases proved to have CBD stones by ERCP. The demographic and other preoperative data are illustrated in (Table 1).

\*In G1E group, 94 patients had successful ERCP with stone extraction and sphincterotomy. In the remaining 39 patients, ERCP had failed to remove the stones (True failure). They were all transferred to the surgical department immediately (within 24 hrs) with no ERCP stent inserted. The cause of the true failure was mainly due to large stone impaction.

\*In G2E group, 17 patients had successful ERCP. In the remaining 23 cases who had failed ERCP in the first attempt, ERCP was repeated in another sitting and it was successful in only 9 of them (False failure). The cause of success in the second attempt was due to the proper setup and vast experience of the staff involved. The failure in the remaining 14 cases was due to large stone impaction (true failure). Those 14 failed cases were referred late (after 24 hrs) to the surgeons.

### *The surgical groups*

It included the 53 cases in which ERCP failed to extract CBD stones. They were divided into 2 groups according to the time of referral after ERCP failure.

\*The first surgical group (G1S) included 39 patients. They were referred immediately to the surgical department within 24 hrs of failed ERCP. The clinical and laboratory conditions of these patients were stable preoperatively (did not need any ICU admission). Two patients needed correction of their coagulopathy by giving more units of FFP and packed cells as there was considerable bleeding during ERCP procedures. The overall operating time was 75-135 min with a mean of  $89 \pm 16.5$  min and the hospital stay was 7-38 days with a mean of  $12.4 \pm 2.43$  days.

- In subgroup A (G1ST) with T-tube external drainage, all the 21 patients had a smooth uneventful post

operative period with no bile leakage. The T- tube cholangiogram performed and revealed two cases with residual stones. They were referred to remove the missed stones by ERCP. For the remaining 19 patients the T- tube was removed 24 hrs after cholangiography. There was a minimal bile leak after removal of the T- tube for 2 days. The mean operating time was  $83.2 \pm 9.5$  min. The mean hospital stay in this group was  $16.1 \pm 3.1$  days (Table 2). The serum  $K^+$  and  $Na^+$  was expected to be deranged due to the loss from external biliary drainage. This was corrected during post operative management.

- In subgroup B (G1SS) where patients were referred immediately, all the 18 patients had a home made stent inserted in the CBD. In this group one patient developed acute pancreatitis that needed ICU admission which resolved conservatively. The remaining 17 patients had a smooth uneventful post operative period. No post operative bile leak was noticed through the sub-hepatic drain which was removed in the 5th post operative day. The mean operating time was  $94.8 \pm 23.5$  min. The mean hospital stay was  $8.72 \pm 1.75$  days in this group (Table 2).

No operative mortalities were recorded in both subgroups A and B. Also, the serum bilirubin and total leucocytic count considerably decreased on hospital discharge in both sub groups.

\*The second surgical group (G2S), included 14 patients. They had delayed referral after 24 hrs of failed ERCP. Patients in its both subgroups had variable post operative out come. The overall operating time was 98-143 min with a mean of  $108.35 \pm 8$  min and the hospital stay was 18-38 days with a mean of  $25.3 \pm 6.8$  days.

- The subgroup C (G2SO) included 6 patients. Five out of these 6 patients in this group had developed increasing jaundice and severe cholangitis and were referred to surgical department 3-6 days after failed ERCP in a very critical situation. They were admitted to the ICU with a diagnosis of systemic inflammatory response syndrome (SIRS) for immediate intensive resuscitation including invasive monitoring, cardiovascular and hepato-renal support. Three patients of them needed a preoperative (PTD) catheter to improve their condition. Two of them had impacted Dormia basket with large stones. The mean serum bilirubin was

$18.2 \pm 6.2$  mg/dl and the mean total leucocytic count (TLC) was  $19.2 \pm 5.3 \times 10^3 / \mu\text{L}$ . The operations were done 24 - 48 hrs after ICU admission and resuscitation. The intra-operative findings were suggestive of cholangitis and severe peritoneal reaction. The Dormia basket was retrieved from the CBD after exploration and removal of stones from it. The basket was then removed by pulling it out through the mouth. The mean operating time was  $119.5 \pm 11.1$  min. The three PTD catheters were removed post operatively. The post operative course was very bad. They were re-admitted to the ICU after operation for further invasive monitoring and cardiovascular, hepatic and renal support. The mean hospital stay was  $28.7 \pm 5.5$  days. Three out of these 5 cases died postoperatively due to uncontrolled septic shock and hepato-renal failure. The remaining two patients who survived had bile leak and sever wound infection respectively. They responded to conservative management. The remaining single case in this group C was referred electively on the 7th day after ERCP failure due to functioning naso-biliary drain. The patient had an uneventful preoperative, operative and postoperative course with favorable outcome (Table 2).

- In subgroup D (G2SS), the remaining 8 cases had an endoscopic stent but ERCP failed to remove the stones. Six of these 8 patients were admitted electively on the 7th -12th day after ERCP failure. The preoperative clinical condition was the same as before the ERCP failure. The serum bilirubin levels and total leucocytic count were less than before ERCP (Table 2). Intra-operatively, the ERCP stent was found and left inside after exploration of CBD and extraction of the impacted stone. The operative findings and the post operative course was smooth with favorable outcome. Only two patients had mild wound and chest infection respectively. The mean operating time was  $97.2 \pm 4.9$  min and the mean hospital stay was  $21.9 \pm 8.1$  days. In the remaining 2 cases in this subgroup, the patients developed progressive cholangitis with increasing serum bilirubin and total leucocytic count with deterioration of general condition. The operative findings proved that the ERCP stent was blocked (kinked and/or filled with biliary mud). T-tube was inserted instead of those failed stents. They had a bad post operative course. Both of them died due to uncontrolled sepsis and hepato-renal failure.

**Table (1): The ERCP group**

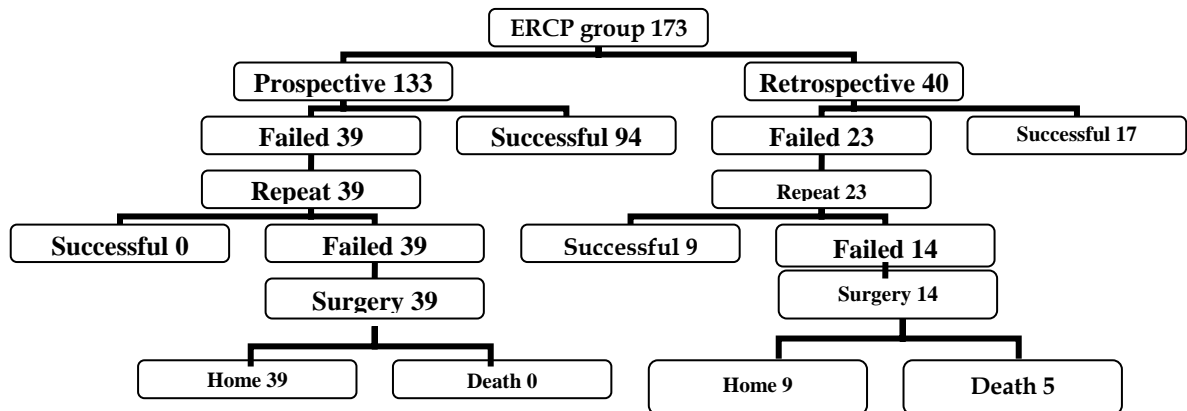
Main group	G1E	G2E
Type of the study	prospective	retrospective
No of Patient	133	40
M / F	41/92	14/26
Age (years)	32-77	36-69
U/S	133	40
Cholangitis	0	0
Leucocytic count (10 <sup>3</sup> / $\mu$ L)	7.2 $\pm$ 2.4	7.9 $\pm$ 2.9
Serum D. bilirubin (mg/dl)	7.6 $\pm$ 4.3	8.6 $\pm$ 3.9
Failed ERCP 1st attempt	39	23
Failed ERCP 2nd attempt	39 (same sitting)	14 (different sitting)
Cause of failure*	Large stones	Large stones
Time of referral	within or < 24 hrs	After or > 24 hrs, up to 12 days

\*Failure to clear the CBD from stones

**Table (2) The Surgical group**

Main group	G1S		G2S	
Time of referral	immediate < 24 hrs		delayed > 24 hrs	
Subgroup	A (G1ST)	B (G1SS)	C (G2SO)	D (G2SS)
No of Patients	21	18	6	8
M / F	7/14	5/13	2/4	3/5
Age (years)	39-64	34-75	47-69	40-66
Cholangitis	0	0	5	2
Leucocytic count (10 <sup>3</sup> / $\mu$ L)	8.4 $\pm$ 2.4	7.9 $\pm$ 1.9	19.2 $\pm$ 5.3	11.6 $\pm$ 4.7
Serum D. bilirubin (mg/dl)	8.6 $\pm$ 3.5	8.1 $\pm$ 2.9	18.2 $\pm$ 6.2	5.8 $\pm$ 3.7
Type of drainage	External	Internal	Internal	Internal, External
Method of drainage	T tube (21)	Home made stent (18)	Stoma formation (6)	ERCP Stent (6) T tube (2)
PTD	0	0	3	0
OperatingTime (min)	83.2 $\pm$ 9.5	94.8 $\pm$ 23.5	119.5 $\pm$ 11.1	97.2 $\pm$ 4.9
Hospital stay (Day)*	16.1 $\pm$ 3.1	8.72 $\pm$ 1.75	28.7 $\pm$ 5.5	21.9 $\pm$ 8.1
ICU admission	0	0	5	2
Morbidity	2	1	2	3
Mortality	0	0	3	2
Home	21	18	3	6

\*Hospital stay from time of referral (day)



**(Fig 1): The ERCP group**

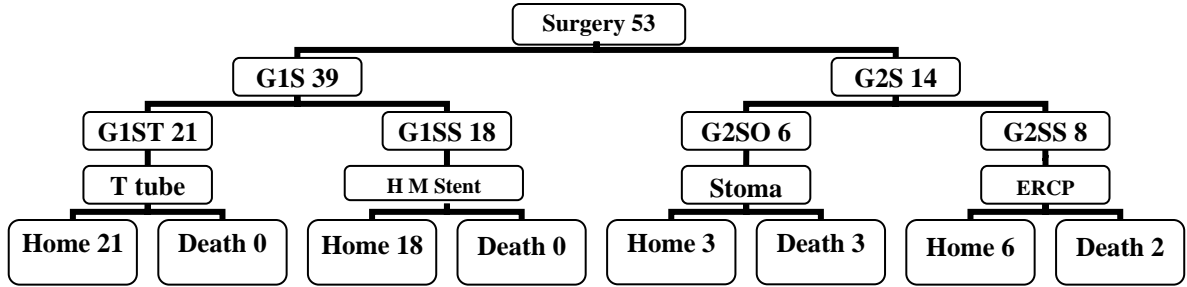
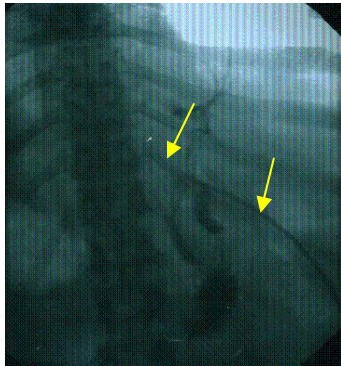
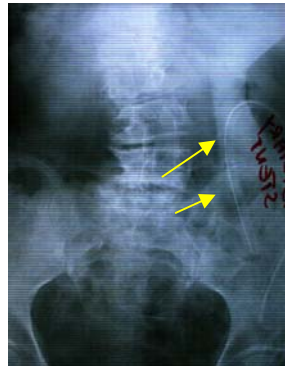


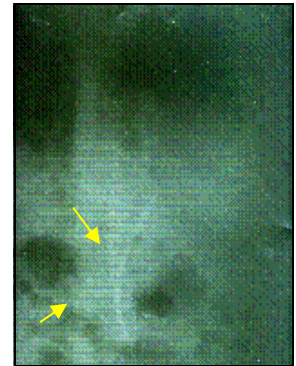
Fig (2): The Surgical group



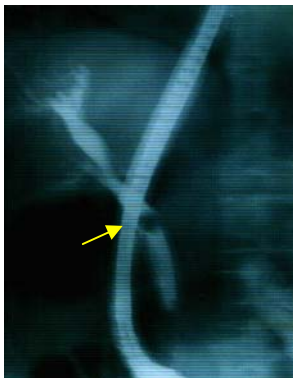
T - tube cholangiogram (mirror image)



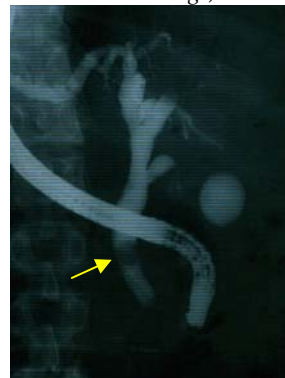Home made stent in Rt. colon (plain X-ray mirror image)



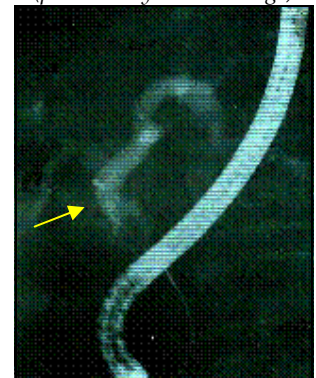
ERCP stent post CBD exploration (plain X-ray mirror image)



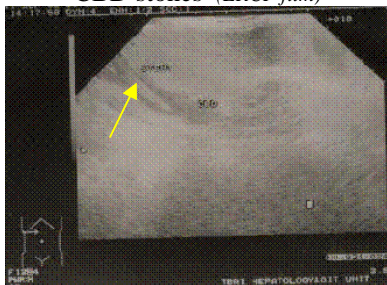
CBD stones (ERCP film)



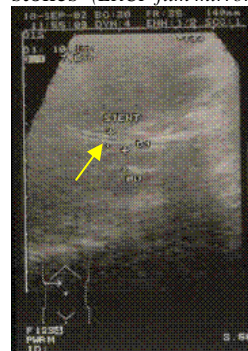
CBD stones (ERCP film mirror image)



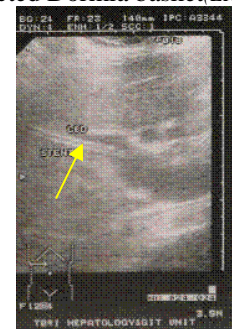
Impacted Dormia basket(ERCP film)



Home made stent in CBD (Ultra sonography)



Home made stent in Duodenum (Ultra sonography)



ERCP stent in CBD (Ultra sonography)

## DISCUSSION

ERCP has been proved to be the most reliable investigation in the diagnosis of CBD stones. It also has the therapeutic options of sphinctrotomy, CBD stone extraction and stenting (6, 7). The use of ERCP for stone extraction has considerable advantages over the operative exploration. Being a less invasive procedure, it could be more suitable for unfit patients for surgery (3, 15, 16). Also in case of missed stones after cholecystectomy, ERCP saves the patient the burden of re-laparotomy (5). Even in elective and fit patients, preoperative ERCP stone removal render them candidate for simple cholecystectomy without the morbidity of operative CBD exploration (17). The later indication is of crucial importance particularly in cases selected for laparoscopic cholecystectomy when the facilities and expertise of laparoscopic CBD exploration are not available (18, 19). Lastly, the sphinctrotomy done during ERCP offered a permanent internal biliary drainage. This procedure prevents bile stasis and CBD stone reformation without doing the more technical demanding surgical sphinctroplasty (20).

In this study the overall ERCP failure rate to clear the common bile duct from stones was 30.4%. The failure rate in the prospective G1E was 29.3% and in the retrospective G2E it was 35%. The improved results in the prospective cases were due to better instrumental facilities and proper setup, besides doing all cases by more experience operators. This ERCP failure rates were almost similar to or even less than that reported by others. They reported a failure rate ranged from 30% (20) to 41% (21). In the retrospective ERCP group (G2E) the first attempt failure was 57.5% (23 out of 40). In the second trial in a different sitting it succeeded in 9 out of 23 (39.1 %) cases (false failure). The causes of the first attempt ERCP failure in the G2E group were due to technical failure (Table 1). These causes were correctable and should be avoided. On the other hand the second ERCP attempt in cases of G1E group did not succeed in a single case (true failure). The cause of failure was due to severely impacted large stones. The success rate in the prospective group (70.6%) was definitely higher than in the retrospective group (65%). It was noticed that it is better to offer all the facilities to succeed from the first attempt of ERCP. This is obvious in the prospective group which revealed a better success rate compared to the retrospective group even after correction of the failure causes.

The results of our surgical work in this study revealed that the early surgical intervention within the first 24 hrs after ERCP failure in calculi obstructive jaundice in G1S gave more favorable results (decrease morbidity and mortality) than the delayed surgical exploration of the CBD in G2S. This concept was supported by previous results reported on clinical and experimental basis before. They reported that biliary obstruction can cause early cholangitis (22, 23), bacterial translocation and impaired mononuclear

phagocytic function (24) with rapidly progress to systemic inflammatory response syndrome and multiple organ failure (25, 26).

In the first surgical group (G1S) the patients did not need further preoperative preparation. The operative findings showed no marked inflammatory changes or adhesions due to ERCP manipulations. The operating time was considerably shorter than the G2S due to the method of drainage. Also the post operative course was smooth with a relatively short post operative hospital stay. There was no mortality reported in this group (0%) compared to 35.7% in the other group.

The management and the out come in the G2S were variable according to the patients' preoperative clinical condition and the type of surgical biliary drainage used. In this group 7/14 were in a good general condition (50%), of them 1/6 and 6/8 were in subgroup C& D respectively. They did not need any specific preoperative preparation. Irrespective to the delayed referral and the late surgical intervention they had a good favorable outcome. This could be explained by the good ERCP drainage they had preoperatively. There was no death in those patients. The worst results were obtained in the remaining 7 patients (50%), 5/6 and 2/8 in group C& D respectively. They were referred late to the surgical department in a very critical condition. They had failed ERCP stone extraction and no biliary drainage was done. They developed progressive septic cholangitis which required an intensive preoperative resuscitation in the ICU, and percutaneous transhepatic drainage (PTD) was done urgently in 3 of them. They were operated upon late. Intra-operatively, they had long surgical procedure for CBD exploration and biliary drainage. In the post operative period 5 out of 7 patients died (35.7%) of them, 3/5 and 2/2 in subgroup C & D respectively. This post-operative mortality rate was more than that reported in previous studies (9%-27 %) (27).

In the G1S group, all the 39 patients had successful both external and internal biliary drainage. Twenty one patients of them (53.8 %) had external biliary drainage using a T-tube drain. Two patients 9.5% of them had missed stones. In the remaining 18 patients (46.2%) the CBD was drained internally using the home made stent. Only one patient 5.5% developed post operative acute pancreatitis. No bile leak or fistulae formation were noticed in this group G1S. Also, no mortality was reported in this group (G1S). It was also noticed that insertion of the home made stent gave more favorable results than the T-tube in CBD drainage. The CBD home made stent patients had a simple post operative management and render them comparable to those with simple cholecystectomy. It also shortened the hospital stay for those patients. Furthermore, the home made stent is more physiological as the bile is drained internally to the duodenum and there was no bile loss or electrolyte

imbalance. On the other hand, the home made stent lacking the T-tube advantage of doing post operative cholangiogram or percutaneous management of post operative residual CBD stones. Also, the T-tube might be more suitable for external drainage of severely infected bile. These results agreed with that reported previously concerning the more favorable outcome of internal drainage using home made stent than external T-tube biliary drainage in the term of hospital stay, operating time and post operative recovery (11, 12).

In the G2S group bile was drained internally in 12 patients, 6 of them had choledochoduodenostomy stoma formation and in the remaining 6 using the ERCP stent for surgical drainage. Patients in this group had a less favorable outcome. This might be due to delayed surgical intervention, internal drainage of infected bile and the time consumed in the stoma formation.

### CONCLUSION

ERCP is a useful diagnostic and therapeutic modality in CBD stones. It should be done in a proper setup with good facilities and by well experienced operators.

The immediate surgical drainage after failed ERCP in stone extraction proved to decrease the patient morbidity and mortality.

In lacking of immediate surgical intervention facilities, ERCP stent proved to decrease the incidence of post ERCP cholangitis and could defer the patient safely for a delayed elective operation.

In surgical patients, internal biliary drainage through CBD stent and closure of CBD (Primary Choledochorrhaphy) proved to simplify the post operative management and shorten the hospital stay. Biliary enteric stoma formation is not preferred to be done in critically ill patients with severe septic cholangitis. External biliary drainage using the T-tube may be more suitable in this situation.

### RECOMMENDATIONS

The immediate choledocholithotomy, cholecystectomy and biliary drainage are recommended to improve the overall post-operative outcome after failure of ERCP in calculous obstructive jaundice.

The use of stent for internal biliary drainage and primary closure of CBD might be preferable to external T-tube drainage particularly in absence of cholangitis with severely infected bile.

### REFERENCES

1. Russell R C G , Williams N S, Bulstrode C G K., Baily & love short practice of surgery, 23rd, Edition, 2000; Chapter 54. The gall bladder and bile ducts p: 965-986.
2. Gibney EJ. Asymptomatic gallstones, Br. J. Surg. 1990; 77:368-72.
3. Sherlock S, Dooly J Disease of the liver and biliary system, 10th, edition, 1997; Chapter 31. Gall stones and inflammatory gall bladder disease. p: 593-624.
4. Lacaine F, Corlette MB, Bismuth H . Preoperative evaluation of the risk of common bile duct stones Arch Surg 1980; 115:111-16.
5. Cairns SR, Dias L, Cotton PB, Salomon PR, Russell RCG. Additional endoscopic procedures instead of urgent surgery for retained common bile duct stones Gut 1989;30:535-40.
6. Cotton PB, Forbes A, Leung JWC, Dineed L, Endoscopic stenting for long term treatment of large bile duct stones, 2-5 year follow-up. Gastrointest Endosc. 1987; 33:411-2.
7. Peters R, Macmathuna P, Lombard M, Karani J; Westaby D. Management of common bile duct stones with a biliary endoprosthesis report on 40 cases .Gut 1992;33: 1412-5.
8. Maxton DG, Tweedle DEF, Martin DF .Retained common bile duct stones after endoscopic sphincterotomy temporary and long term treatment with biliary stenting. Gut, 1995;36: 446-9.
9. Chen SS, Cbou FF Choledochotomy for biliary lithiasis. Is routine T-tube drainage necessary? Acta Chir Scaod 1990;156: 387-390.
10. Lygidiksd NJ Choledochotomy for biliary lithiasis T-tube drainage or primary closure effects on postoperative bacteremia and T-tube bile infection Am J Surg 1983;146:254-256.
11. Radwan E, Primary Common bile duct closure on a choledochoduodenal stent, the 19th annual meeting of Egyptian Society of Surgery, Abstract book 2001 hepato biliary surgery p 9.
12. Zhiyuan T, Jiadong L, Hailin X, Qin Z, Tongnian C. Primary choledochorrhaphy after common bile duct exploration. Digestive Surgery 1999;16:137-39.
13. McGahan JP, Goldberg B B,(CD) 2000 "Diagnostic Ultra sound a logical approach" Chapter 22. Lippincott CME, USA.
14. Shephard M, Mason J, (1st ed) 1999 Practical Endoscopy Chapman & Hall Medical Chapter 11, p: 251-282.
15. Sherlock S, Dooly J, Disease of the liver and biliary system. 10th, edition, 1997, Chapter 29, Imaging of the biliary tract. P: 561-575.



16. Johnson AS, Ferrara JJ, Steinberg SM, Gassen GM, Hollier LH, Flint LM .The role of endoscopic retrograde cholangiopancreatography: sphincterotomy versus common bile duct exploration as a primary technique in the management of choledocholithiasis. *Am Surg.* 1993;59(2):78-84
17. Boender J, Nix GA, de Ridder MA, Dees J, Schutte HE, van Buuren HR, van Blankenstein M. Endoscopic sphincterotomy and biliary drainage in patients with cholangitis due to common bile duct stones. *Am J Gastroenterol.* 1995;90(2):233-8
18. Cuschieri A, Croce E, Faggioni A, Jakimowicz J, Lacy A, Lezoche E, Morino M, Ribeiro VM, Toouli J, Visa J, Wayand W. EAES ductal stone study. Preliminary findings of multi-center prospective randomized trial comparing two-stage vs single-stage management. *Surg Endosc.* 1997;11(10):1057-8.
19. Rieger R, Sulzbacher H, Woisetschlager R, Schrenk P, Wayand W. Selective use of ERCP in patients undergoing laparoscopic cholecystectomy. *World J Surg.* 1994;18(6):900-4;
20. Lai KH, Lo GH, Lin CK, Hsu PI, Chan HH, Cheng JS, Wang EM. Do patients with recurrent choledocholithiasis after endoscopic sphincterotomy benefit from regular follow-up? *Gastrointest Endosc.* 2002;55(4):523-6.
21. Lauri A, Horton RC, Davidson BR, Burroughs AK, Dooley JS. Endoscopic extraction of bile duct stones: management related to stone size. *Gut.* 1993;34(12):1718-21
22. Blamey SL, Fearon KCH, Glimour WH, Osbourne DH, Carter DC, Prediction of risk in biliary surgery. *Br J Surgery.* 1983;70:535-538.
23. Pain JA, Cahill CJ, Baiely ME, Perioperative complications in obstructive Jaundice: Therapeutic considerations .*Br J Surg.* 1985;72:942-945.
24. Parks RW, clements EDB, Syme MG, Pope C, rolands BJ, Diamond T. Intestinal barrier dysfunction in clinical and experimental obstructive jaundice and its reversal by internal biliary drainage. *Br J Surgery* 1996; 83:181-184.
25. Dixon J M, Armestrong Cp, Duffy SW, Factors affecting morbidity and mortality after surgery for obstructive jaundice: A review of 373 patients. *Gut.* 1983;24:845-852.
26. Thomson JN, Edwards WH, Winearls CG, Blenkarn JJ, Benjamin IS, Blumgart LH, Renal impairment following biliary tract surgery. *Br J Surg.* 1987;74:843-847.
27. Stambuck EC, Pitt HA, Osher Pais S, Mann LL, Lois JF, Gomes AS, Percutaneous transhepatic drainage: Risks and benefits . *Arch Surg.* 1983;118:1388-1349.