

PRESERVATION OF PECTORALIS MINOR MUSCLE IN AXILLARY NODE CLEARANCE OF BREAST CANCER

By

Ali El-Arini, MD.*; Nancy Asaad, PhD.**; Moshira Abd El Wahed, PhD.**

Departments of General Surgery * and Pathology **, Faculty of Medicine, Minoufiya University.

Background: The pectoralis minor muscle is increasingly preserved in women undergoing axillary clearance as part of either breast conservation or mastectomy. The aim of the study was to determine the number of nodes removed and the proportion of positive nodes for patients submitted to breast surgery, with and without preservation of the pectoralis minor. In addition, to determine the incidence of early and late complications including the surgical, and functional consequences.

Patients and Methods: A prospective study was conducted in two groups of 30 patients each submitted to axillary dissection for breast cancer (46 mastectomies and 14 conservative procedures) with the pectoralis minor muscle spared in one group and removed in the other. The mean number of dissected lymph nodes in both procedures was counted. The immediate (1 month), early (1-3 months) and late (6 months up to 1 year) postoperative complications were recorded prospectively.

Results: Clinical details were similar in the two groups. Twenty five percent of patients had negative nodes and 75% had positive nodes. When the node-positive patients were subdivided in terms of extent of involvement (1-3, 4-9 and 10 or more) there were similar proportions in both groups. The mean total number of nodes removed in the two groups was similar: 16.5 (range, 7-32) (muscle spared group) versus 17.5 (range 7-34) (muscle removed group). Furthermore, on analyzing the number of dissected lymph nodes in relation to the anatomical level, no difference was observed in numbers, at level I, II, and III in both groups.

With respect to immediate postoperative complications there was no difference in the usual postoperative course between the two groups. Similarly, the early postoperative complications failed to demonstrate any difference between the two groups of patients apart from a slight increase in lymphoedema frequency and shoulder dysfunction in patients in whom the pectoralis minor was removed. The late postoperative complications revealed a higher difference in shoulder and arm movement restriction in favour of the spared muscle group (2/30 vs 6/30). Fewer patients with pectoralis minor muscle intact had lymphoedema (9/30) compared with those in which the muscle had been removed (14/30). We did not find differences in pain, winged scapula, or intercostobrachial syndrome at the 6-month to one-year follow-up. In contrast a highly significant statistical difference was found between the two groups with regard to the partial atrophy of the pectoralis major muscle (2/30) for the spared muscle group versus (18/30) for the removed muscle group.

Conclusion: The comparison of the two groups showed that the mean number of dissected nodes in both procedures was similar. Retention of the pectoralis minor is not associated with understaging or undertreatment of the axilla and also appears to prevent the partial atrophy and fibrosis of the pectoralis major. Patients treated with conservation of the pectoralis minor muscle showed atrophy of the pectoralis major muscle in (6.6%) of cases versus (60%) observed in the muscle removed group.

Keywords: Pectoralis Minor Preservation-Breast Surgery- Axillary Clearance

INTRODUCTION

Axillary dissection remains an important component of breast cancer surgery⁽¹⁾. The levels of axillary nodes are anatomically defined as level one (inferolateral to

pectoralis minor), level two (posterior to pectoralis minor) and level three (superomedial to pectoralis minor)⁽²⁾. The three levels axillary dissection for breast cancer patients provide extremely accurate information on lymph nodal

spread. The diagnostic sensitivity is positively related to the number of dissected axillary levels, the highest sensitivity is reached when a third level lymph node axillary dissection is performed (3,4).

Although the technique of axillary dissection in breast cancer treatment traditionally includes the resection of the pectoralis minor muscle, it has been shown recently that when the dissection is performed sparing the muscle, the average number of nodes removed is not reduced (5, 6). Nevertheless, axillary clearance does carry some short-and long-term morbidity, namely postoperative pain, arm lymphoedema, and restriction of shoulder movement (3). These complications may be reduced if the pectoralis minor muscle is not excised as part of the procedure. The pectoral neurovascular bundles are liable to be injured or severed while the pectoralis minor is excised because the medial pectoral neurovascular bundle commonly perforates the pectoralis minor. Careful visualization and experience is necessary to safeguard the pectoral neurovascular bundles as one has to work deeply through the base of the axilla (7).

Some authors (5, 2, 3, 1, 7, 6, 8, 4) have proposed new procedures with the aim of sparing axillary structures uninvolved in staging or treatment by simultaneous preservation of the total integrity of the pectoralis minor muscle and pectoralis nerves.

The aim of the study was to determine the number of nodes removed and the proportion of positive nodes for patients submitted to breast surgery, with and without preservation of the pectoralis minor muscle. In addition, to compare the incidence of early and late complications including the surgical, and functional consequences between the two groups.

PATIENTS AND METHODS

Sixty patients subjected to complete axillary dissection for operable breast carcinoma between January 1998 and December 2002, at Minoufiya University Hospital. All patients belonged to the T1, T2, T3 N0, N1, N2 clinical categories. In 30 of these patients the pectoralis minor muscle had been spared (spared muscle group) and in the other 30 patients it had been removed by resection of its attachment to the coracoid process and to the ribs (removed muscle group). A complete axillary dissection was performed in both groups, taking care to clearly mark the anatomical levels I, II, and III of the lymph node chain. Rotter's lymph nodes, separately dissected, were included in the second level.

To enable the pathologist to establish the level of the nodes, specimens were marked at operation by the surgeon with silk sutures. These were placed at the lower border of pectoralis minor and at the apex of the axilla. In women

who did not have excision of the pectoralis minor, another marker suture was placed on the fat next to the upper border of pectoralis minor. The fresh specimen was dissected in the pathology laboratory and the number of lymph nodes at each level was counted; representative samples were taken from each node after which the specimens were fixed, sectioned and stained with Haematoxylin and Eosin.

Immediate postoperative complications such as haemorrhage and/or haematoma, wound edge necrosis, wound infection, wound dehiscence, and seroma formation after removal of the suction drain requiring aspiration were recorded during the first month. Early complications such as winged scapula, intercostobrachial syndrome, pain, shoulder and arm movement restriction, upper arm swelling or lymphoedema were scored, at the first clinical examination at 3 months post-surgery. The second evaluation was carried out 6 months up to one year after surgery. The late complications were persistent winged scapula, persistent paraesthesias or numbness due to injury of the intercostobrachial nerve, persistent pain, shoulder and arm movement restriction, lymphoedema of the arm and atrophy of the pectoralis major muscle.

Local and axillary recurrences were determined during the follow-up period; median 30 months (range 6-60 months).

SURGICAL TECHNIQUE

The pectoralis major muscle can be detached, with a finger, from the underlying pectoralis minor muscle after having cut the muscular fascia along its lateral border. The potential space between pectoralis major and minor muscles is then realized and dissected. Attention is turned to the deep aspect of the pectoralis major muscle for identification and preservation of the medial neurovascular bundle. In addition, this area is inspected and palpated for possible involvement of the interpectoral nodes of Rotter (5). Dissection continues along the lateral aspect of the pectoralis major muscle to the level of the pectoralis minor muscle. At this point the lateral pectoral nerve is identified in its anatomic relationship with the pectoralis minor muscle. Preservation of the pectoral nerve is often attempted with either retraction or resection of the pectoralis minor (3).

The only structure to be spared between the long thoracic nerve and the pectoral muscles anteriorly is the medial pectoral nerve. This is usually evident to inspection, about 1 to 2 cm caudad to the level of the axillary vein border. Division of this nerve produces very apparent atrophy of the central and some of the lateral fibers of the pectoralis major muscle (6). The pectoralis minor is retracted medially and dissection of level I and II was started by incising the fascial sheath of the axillary vessels anteriorly

at the highest point of the axilla. Restriction of the plane of dissection to anterior to and below the axillary vein minimizes the chance of lymphoedema (4).

One of the major constraints in pectoralis minor sparing axillary dissection is the limitation to medial retraction of the muscle. Complete mobilization of the pectoralis minor muscle, achieved after incising along the medial border, allows the muscle to be retracted laterally with a Morris retractor, thus, allowing access to the level III lymph nodal dissection. Swinging of the pectoralis minor laterally or medially and retraction of the pectoralis major muscle medially expose the axillary contents at surface level and allow an excellent view and tend to support each other (Figs. 1-4). The specimen can be delivered from behind the pectoralis minor muscle into the main field to complete the dissection. When the limits of axillary levels are identified, they are marked with transfixing stiches (6).

STATISTICAL ANALYSIS

Data collected and analyzed by SPSS statistical package (SPSS Inc. Chigago, IL, USA). Statistical analysis was done according to Ingelfinger et al. (9), and Knapp and Miller (10). Quantitative data expressed as median, number, and percentage and analyzed by student T-test for comparison of groups. Quantitative data expressed as number and proportions and analyzed by X2-test. Other patient characteristics were analyzed by the log-rank test (11). P value was set as <0.05 for significant. Tabulations were done according to Knapp and Miller (10).

RESULTS

Clinical details were similar in both groups (spared muscle and removed muscle). The mean age of the two groups was similar (55.6 ± 8.2 and 56.3 ± 7.1 years). Laterality, tumor location, clinical tumor size and clinical stage were also similar (Table 1).

Fifteen (25%) patients had negative nodes and 45 (75%) had positive nodes. Of the pectoralis minor spared group, 26.6% had pathologically negative axillary nodes compared with 23.3% of those who had the muscle excised. When the node-positive patients were subdivided in terms of extent of involvement (1-3, 4-9 and 10 or more) there were nearly similar proportions in both groups (Table 2).

Conservative breast surgery (quadrantectomy or wide local excision and axillary dissection) plus radiotherapy was performed in 14(23.3%) women: 5 of the spared muscle group and 9 of the removed muscle group; whilst 46(76.6%) patients were submitted to modified radical mastectomy: equally divided between the two groups (Table 3).

The mean total number of nodes removed in the two

groups was similar: 16.5 ± 3.1 (range, 7-32) in those who had the pectoralis minor spared and 17.5 ± 3.4 (range, 7-34) in those whom the muscle was removed ($P=0.35$). Furthermore, on analyzing the number of dissected lymph nodes in relation to the anatomical level, no difference was observed in numbers, at level I, II, and III between the two groups of patients (Table 4).

The total number of cases with regular distribution through Levels I, II, and III was 41 (91.1%): 20 (91%) for the muscle spared group and 21 (91.3%) for the muscle removed group. The total number of cases with skip distribution was 4 cases (8.9%): 2(9.1%) for the first group and 2(8.7%) for the second group (Table 5).

With respect to immediate postoperative complications, there were no differences in the usual postsurgical course between the two groups of patients. In particular, we did not find any difference between the two groups in relation to the development of seroma. Seroma formation was recorded in 9/30 patients in which the muscle was spared, and in 8/30 patients in whom the muscle was removed. The suction drain was removed on about the tenth postoperative day (range, 6-14 days) if less than 50 ml per 24 hours has accumulated. Subsequent accumulation of serous fluid was aspirated using a needle and syringe under aseptic conditions if required and a firm bandage was applied on the wound. Postoperative haemorrhage and axillary haematoma formation, as well as necrosis or diathermy burns to the wound edges were rare in our study. However, postoperative wound infection of the axillary wound occurred in 6.6% for the whole group, and was managed using oral antibiotics, together with drainage of any infected seroma, which may have accumulated (Table 6).

The early postoperative complications performed at one to three months failed to demonstrate any difference between the two groups of patients apart from a slight increase in lymphoedema frequency and shoulder dysfunction in patients in whom the pectoralis minor was removed (3 vs 7 cases) and (7 vs 11 cases), respectively (Table 7).

The late postoperative complications revealed a slight difference in shoulder and arm movement restriction in favour of the first group (spared muscle) (2/30 cases) versus the second group (6/30). Fewer patients with the pectoralis minor muscle intact had lymphoedema (9/30) compared with those in which the muscle had been removed (14/30). All cases of lymphoedema were mild to moderate, no serious lymphoedema occurred in any case. We did not find differences in pain, winged scapula or intercostobrachial syndrome at the 6-months to one year clinical evaluation. In contrast a substantial difference was found between the two groups with regard to the partial

atrophy of the pectoralis major muscle: atrophy had occurred in 2/30 (6.6%) of cases of the first group (spared muscle) and in 18/30 (60%) of cases in which the pectoralis minor was removed. This finding appears as an infraclavicular sunken or chest wall depression, frequently unpleasant from the cosmetic point of view (Table 8).

Adjuvant treatment in the form of radiotherapy, chemotherapy, and hormonal treatment was given to 86.7%, 85%, and 73.3% of patients, respectively (Table 9).

The follow-up of 60 patients (mean 30.6, median 30, range 6-60 months), had shown axillary node recurrence in 2 patients (3.3%) for the whole series equally distributed between both groups, in whom lymphatic involvement had been shown through histologic examination to have a heavy axillary disease burden. Treatment consisted of excision of the axillary recurrent tumor. No radiotherapy was given to the axillary region.

Table (1): Demographic and clinical tumor characteristics

Characteristics	Pectoralis minor		Pectoralis minor		Total		P value
	spared	(n=30)	removed	(n=30)	(n=60)		
Mean age (range), year	55.6±8.2	(28-80)	56.3±7.1	(29-78)	55.9±7.3	(28-80)	0.44
Laterality							
Right	13	(43.3)	14	(46.7)	27	(45)	0.79
left	17	(56.7)	16	(53.3)	33	(55)	
Location							
Upper outer	14	(46.6)	16	(53.3)	30	(50)	0.95
Upper inner	5	(16.7)	4	(13.3)	9	(15)	
Lower inner	3	(10)	3	(10)	6	(10)	
Lower outer	2	(6.7)	2	(6.7)	4	(6.7)	
Central	2	(6.7)	3	(10)	5	(8.3)	
Unknown	4	(13.3)	2	(6.7)	6	(10)	
Clinical tumor size (cm)							
≤ 2 cm	4	(13.3)	3	(10)	7	(11.7)	0.62
> 2 ≤ 5 cm	7	(23.3)	11	(36.7)	18	(30)	
> 5 cm	17	(56.7)	13	(43.3)	30	(50)	
Unknown	2	(6.7)	3	(10)	5	(8.3)	
Clinical stage							
Stage I	4	(13.3)	3	(10)	7	(11.7)	0.96
Stage II	7	(23.3)	8	(26.6)	15	(25)	
Stage III	16	(53.3)	17	(56.7)	33	(55)	
Unknown	3	(10)	2	(6.7)	5	(8.3)	

Table (2): Pathologic tumor characteristics

Characteristics	Pectoralis minor		Pectoralis minor		Total		P value
	spared	(n=30)	removed	(n=30)	(n=60)		
Pathological nodal status							
Node negative	8	(26.6)	7	(23.3)	15	(25)	0.73
Node positive							
1-3 nodes	5	(16.6)	8	(26.6)	13	(21.6)	
4-9 nodes	12	(40)	9	(30)	21	(35)	
≥ 10 nodes	5	(16.6)	6	(20)	11	(18.3)	
Grade							
Well	4	(13.3)	6	(20)	10	(16.7)	0.57
Moderate	18	(60)	19	(63.3)	37	(61.7)	
Poor	8	(26.6)	5	(16.7)	13	(21.6)	
Histology							
Infiltrating duct carcinoma	27	(90)	23	(76.7)	50	(83.3)	0.31
Medullary carcinoma	2	(6.7)	3	(10)	5	(8.3)	
Infiltrating lobular carcinoma	1	(3.3)	4	(13.3)	5	(8.3)	
Hormone receptors							
Oestrogen receptors (ER)	20	(66.6)	19	(63.3)	39	(65)	0.78
Progesterone receptors (PR)	16	(53.3)	10	(33.3)	26	(43.3)	
Unknown	2	(6.6)	3	(10)	5	(8.3)	

Table (3): Total number of nodes removed according to type of breast surgery

Breast Surgery	Pectoralis minor spared (n=30)			Pectoralis minor removed (n=30)			Total (n=60)			P value
	Mean	Median	Range	Mean	Median	Range	Mean	Median	Range	
Patey (n=46)	15.6±4.6	15	(8-34)	15.3±4.5	15	(8-31)	15.5±4.5	15	(8-34)	0.77
Conservative therapy (n=14)	15.5±7.8	14.5	(7-29)	15.3±6.8	13	(7-28)	15.4±7.9	14	(7-29)	0.75
In continuity (n=5)	17±11.1	15	(7-29)	17.5±14.8	17.5	(7-28)	17.2±10.8	15	(7-29)	0.80
In discontinuity (n=9)	14.6±6.6	14	(7-25)	14.3±7.1	13	(7-24)	14.4±6.4	14	(7-25)	0.73

Table (4): Total number of nodes removed according to level of dissection

Level	Pectoralis minor spared (n=30)			Pectoralis minor removed (n=30)			P value
	Mean	Median	Range	Mean	Median	Range	
Level I	10.7±3.1	10	(3-15)	13.1±6.2	13	(5-30)	0.09
Level II	5.2±4.4	5	(3-18)	6.2±2.5	6	(4-13)	0.07
Level III	2.7±2.4	2	(0-9)	3.4±2.2	3	(0-12)	0.18
Total	16.5±3.1	16	(7-32)	17.5±3.4	17	(7-34)	0.35

Table (5): Number of patients with node metastasis according to level of dissection

Number of patients with positive nodes	Level			Skip Distribution	Total
	Level I	Level I + II	Level I+II+III		
Pectoralis minor spared	15 (68.2)	3 (13.6)	2 (9.1)	2 (9.1)	22 (100)
Pectoralis minor removed	13 (56.5)	5 (21.8)	3 (13)	2 (8.7)	23 (100)
Total	28 (62.2)	8 (17.8)	5 (11.1)	4 (8.9)	45 (100)
P value	0.60	0.45	0.64	0.60	0.76

Table (6): Immediate postoperative complications

Complications	Pectoralis minor spared (n=30)		Pectoralis minor removed (n=30)		Total (n=60)		P value
Haemorrhage/haematoma	0	(0)	1	(3.3)	1	(1.6)	0.31
Wound infection	2	(6.6)	2	(6.6)	4	(6.6)	0.60
Wound edge necrosis	1	(3.3)	0	(0)	1	(1.6)	0.31
Wound dehiscence	1	(3.3)	0	(0)	1	(1.6)	0.31
Seroma after drain removal requiring aspiration	9	(30)	8	(26.6)	17	(28.3)	0.77

Table (7): Early postoperative complications (1-3 months)

Complications	Pectoralis minor spared (n=30)		Pectoralis minor removed (n=30)		Total (n=60)	P value
Lymphoedema	3	(10)	7	(23.3)	10 (16.6)	0.16
Shoulder dysfunction	7	(23.3)	11	(36.6)	18 (30)	0.26
Pain	2	(6.6)	3	(10)	5 (8.3)	0.64
Winged scapula	4	(13.3)	5	(16.6)	9 (15)	0.72
Intercostobrachial syndrome	8	(26.6)	10	(33.3)	18 (30)	0.57

Table (8): Late postoperative complications (6months - 1 year)

Complications	Pectoralis minor spared (n=30)		Pectoralis minor removed (n=30)		Total (n=60)	P value
Lymphoedema	9	(30)	14	(46.6)	23 (38.3)	0.18
Shoulder dysfunction	2	(6.6)	6	(20)	8 (13.3)	0.13
Pain	5	(16.6)	6	(20)	11 (18.3)	0.74
Winged scapula	2	(6.6)	2	(6.6)	4 (6.6)	0.60
Intercosto brachial syndrome	17	(56.6)	19	(63.3)	36 (60)	0.57
Pectoralis major atrophy	2	(6.6)	18	(60)	20 (33.3)	0.0001

Table (9): Adjuvant treatment characteristics

Adjuvant treatment	Pectoralis minor spared (n=30)		Pectoralis minor removed (n=30)		Total (n=60)	P value
Adjuvant radiotherapy						
Yes	25	(83.3)	27	(90)	52 (86.7)	0.45
No	5	(16.7)	3	(10)	8 (13.3)	
Adjuvant chemotherapy						
Yes	26	(86.7)	25	(83.3)	51 (85)	0.72
No	4	(13.3)	5	(16.7)	9 (15)	
Adjuvant hormonal therapy						
Yes	21	(70)	23	(76.6)	44 (73.3)	0.56
No	9	(30)	7	(23.3)	16 (26.6)	

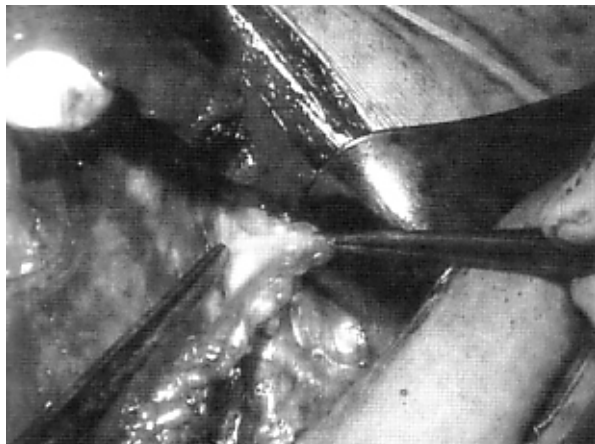


Fig.(1): Axillary vein exposure during first level lymph nodal dissection.

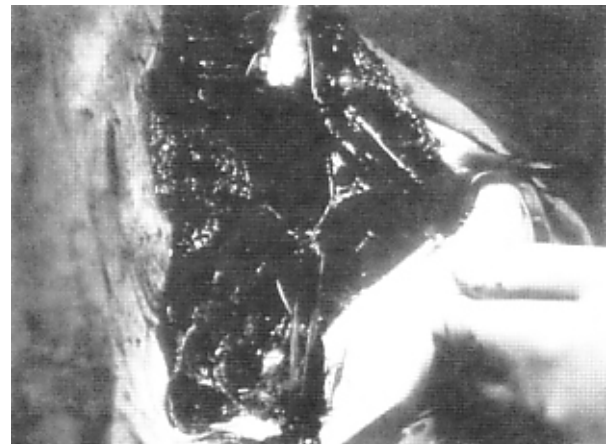


Fig. (2): Medial and lateral dissection of the pectoralis minor muscle, allowing the exposure and preservation of the medial and lateral pectoral nerves.

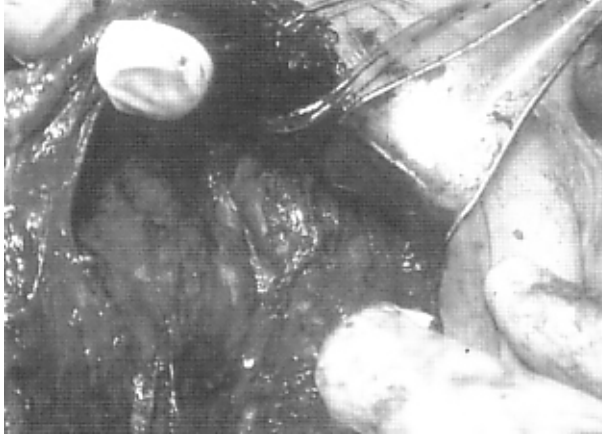


Fig. (3): Mobilization and swinging of pectoralis minor upwards and medially to reach Level II lymph nodes.




Fig.(4): Pectoralis minor muscle retracted laterally while the pectoralis major muscle is retracted medially to reach Level III lymph nodes.

DISCUSSION

Nodal status is still the most important prognostic factor in breast carcinoma (5,12). Our data suggest that the lymph nodal content of the axilla can be completely removed even when pectoralis muscular and nervous structures are preserved. It is thus unlikely to lead either to understaging of the disease or an increased risk for axillary recurrence. This agrees with previous studies which compared results after removal and preservation of pectoralis minor in women undergoing breast surgery (3, 4). In the current study, demographic, clinical, and pathological characteristics were similar in both groups. Although, the number of patients with positive nodes was higher than in other studies, this may be due to advanced stage and higher grade in our cases (5, 3, 13).

Although various characteristics of the primary tumor correlate with recurrence rates, the presence or absence of metastatic axillary nodes is the most important prognostic factor. Additionally, survival rates have been shown to decrease in proportion to the number of positive axillary nodes (14). Therefore, most patients are divided into categories of 1-3, 4-9, or 10 or more positive nodes, to help determine prognosis. In our study, only 25% of patients were node negative, and approximately 18% had more than 10 positive nodes. Previous studies have shown that a minimum of 7 to 10 nodes needed to be dissected for accurate staging (15, 16), our study confirms these results. Axillary lymph node yield was similar in both groups. A median of 16 (range, 7-32) were removed in the muscle spared group versus 17 (range, 7-34) in the muscle removed group ($P=0.35$).

The risk of involvement of the higher lymph node levels increases substantially when lower levels are involved (15). The size and the number of positive nodes may also influence the chance of involvement of the higher nodal stations (15, 17). The most commonly involved axillary lymph nodes are those in level I (i.e., those lymph nodes lateral to the pectoralis minor). It is much less common for level II lymph nodes (i.e., those lymph nodes underneath the pectoralis minor) to be involved without involvement of the level I lymph nodes. The risk of involvement of level III lymph nodes increases substantially when level I and/or II were involved (18, 19). Our data revealed similar number of nodes removed at level I, II, and III in both groups. The total number of cases with positive nodes having regular pattern of distribution through the three levels was 41 (91.1%). However, the total number of cases with skip distribution was 4 cases (8.9%) in agreement with other studies (3).

The rate of wound infection in axillary surgery has been reported at approximately 5% to 10% (20). Wound infection is more common in certain groups of patients: the elderly and immuno-compromised; those who undergo repeated aspiration of seroma or prolonged wound drainage (21). In our study incidence of wound infection was low 6.6% equally distributed between the two groups.

Postoperative haemorrhage and axillary haematoma formation should occur in less than 1% of patients, although subcutaneous bruising is common. In addition, necrosis or diathermy burns to the wound edges should not occur (2). Similar results were obtained in the current study.

Seromas are common following most types of axillary clearance (22, 23) but are reported to be less with axillary sampling. Seromas occur in 17 to 53% of breast surgery wounds (23). The incidence of seroma in our study was 28.3% (30% in the muscle spared group and 26.6% in the muscle removed group).

Shoulder and arm movement restriction is relatively common (approximately 10% to 20%). These complications may be minimized by close attention to the extent of the axillary dissection and in particular following the lower border of the axillary vein and not dissecting lymphatic tissue superior to this (25, 26). In addition, early mobilization and exercise is important for retaining normal mobility postoperatively (24). Shoulder and arm movement restriction revealed a slight difference in favor of the spared muscle group (6.6%) versus the removed muscle group (20%). However, the difference was not statistically significant ($P = 0.13$).

"The intercosto-brachial nerve syndrome" is characterized by paraesthesia of the inner aspect of the upper arm, shoulder, axilla and antero-lateral chest wall. Various studies have looked at this common problem and estimated that some numbness may be demonstrated in almost 80% of patients undergoing surgery (27). The frequency of numbness or paraesthesia in our series was 60% (36 cases): 17 in the muscle spared group and 19 in the muscle removed group, ($P=0.57$). The frequency of more significant or disabling pain was in the range of 5% to 10% (28, 25). In this series 18.3% (11 cases): 5 in the muscle spared group and 6 in the muscle removed group, complained of persistent pain as well.

Motor injury resulting from axillary dissection should be unusual, as the thoracodorsal nerve, long thoracic, and pectoral nerves can be exposed and protected (15). Many patients experience decreased muscle strength and range of motion after a complete axillary dissection (28, 29). Early physical therapy may help reduce this problem (30). The medial pectoral nerve is at risk when dissecting around pectoralis minor. This is particularly so if this muscle is divided, but the nerve may also be damaged during dissection where it swings along the lateral border of the pectoralis minor muscle. In up to one-third of patients, it lies well lateral to the muscle and is at significant risk. Damage to the nerve results in wasting of the lower fibres of pectoralis major. This will result in the loss of the anterior axillary fold, and perhaps a less than desirable cosmetic result. The lesion of the lateral pectoral nerve is equally obvious, as it causes fibrosis, atrophy, shortening of the pectoralis major muscle, and limitations of the shoulder movements. Pectoralis major atrophy occurred in (2/30, 6.6%) in the pectoralis minor spared group, and in (18/30, 60%) in the pectoralis minor removed group, the difference was highly statistically significant ($P = 0.0001$) (6).

Arm lymphoedema is a fairly common and often very troublesome complication following axillary treatment (31). It can occur any time following axillary dissection, and the incidence increases with time. Various studies have reported the incidence of lymphoedema to run between 10-40% (2, 28, 6). Fewer patients with the spared muscle group (9/30, 30%) had lymphoedema, compared with the removed muscle group (14/30, 46.6%) ($P=0.18$).

In the current study two patients (3.3%) developed axillary recurrence, one in the muscle spared group at 39 months, and the other in the muscle removed group at 52 months. Both cases were aged less than 40 years, with T3 tumor size and more than 10 grossly and pathologically positive nodes. The overall risk of axillary recurrence in both groups was in agreement with published series ranging from 0-3% (32, 2).

CONCLUSION

The comparison of the two groups showed that the mean number of dissected nodes in both procedures was similar. Retention of the pectoralis minor is not associated with understaging or undertreatment of the axilla and also appears to prevent the partial atrophy and fibrosis of the pectoralis major. Patients treated with conservation of the pectoralis minor muscle showed atrophy of the pectoralis major muscle in (6.6%) of cases versus (60%) observed in the muscle removed group.

REFERENCES

1. Singhal H. (1996): Axillary dissection: Preservation of the pectoralis minor. *J. Surg. Oncol.*; 61:310.
2. Tompson AM. (1999): Axillary node clearance for breast cancer. *J.R. Coll. Surg. Edinb.*; 44(April): 111-117.
3. Markandoo P, Smith P, Chaudary MA, Fentiman IS. (1998): Preservation of pectoralis minor in axillary clearance for breast cancer. *Br. J. Surg.*; 85: 1547-1548.
4. Muscolino G, Leo E, Sacchini V, Bendini AV, Luini A. (1988): Resectable breast cancer: axillary dissection sparing pectoralis muscles and nerves. *Eur. J. Surg. Oncol.*; 14:429-433.
5. Dasgupta S, Sanyal S, Sengupta SP. (1999): Transpectoral anterior approach to the axilla for lymph node dissection in association with mastectomy preserving both pectoral muscles and their neurovascular bundles. *Tumori*; 85(6): 498-502.
6. Merson M, Pirovano C, Balzani A, Luini A, Biasi S, Galimbertic V. (1992): The preservation of minor pectoralis muscle in axillary dissection for breast cancer: Functional and cosmetic evaluation. *Eur. J. Surg. Oncol.*; 18: 215-218.
7. Hena MA, Silk YN. (1993): Complete axillary lymph node dissection. *J. Surg. Oncol.*; 52: 40-41.

8. Scanlon EF. (1992): The postmastectomy pectoralis minor is worth preserving. *J. Surg. Oncol.* ; 50:19.
9. Ingelfinger JA, Mosteller FM, Thibodeau LA, Ware JH. (1994): *Biostatistics in clinical medicine.* McGraw-Hill Inc: New York: 127-153.
10. Knapp RG, Miller MC. (1992): *Clinical epidemiology and biostatistics.* Harwal Publishing Co., Pennsylvania: 143-187.
11. Mantel N. (1996): Evaluation of survival data and two new rank order statistics arising in its consideration. *Cancer Chemother. Rep.*, 50: 163-170.
12. Coburn MC, Bland KI. (1995): Surgery for early and minimally invasive breast cancer. *Curr. Opin. Oncol.*; 7: 506-510.
13. Siedman JD, Schnaper LA, Aisner SC.(1995): Relationship of the size of the invasive component of the primary breast carcinoma to axillary lymph node metastasis. *Cancer*; 75: 65-71.
14. Saha S, Farrar WB, Young DC, Ferrara JJ, Burak WE. (2000): Variation in axillary node dissection influences the degree of nodal involvement in breast cancer patients. *J. Surg. Oncol.*; 73:143-137.
15. Recht A, Houlihan MJ. (1995): Axillary lymph nodes and breast cancer. *Cancer*; 76: 1491-1512.
16. Axelsson C, Mouridsen H, Zedeler K. (1992): Axillary dissection of Level I and II lymph nodes is important in breast cancer classification (abstract). *Eur. J. Cancer*; 28A: 1450.
17. Gaglia P, Buisone R, Caldarella B, Lai M, Jayme A, Coldarolal. (1987): The correlation between the spread of metastases by level in the axillary nodes and disease-free survival in breast cancer: a multifactorial analysis. *Eur. J. Cancer*; 23: 849-954.
18. Senolsky GM, Moffat FL, Davisk, Masri MM, Clark KC, Robinson DS. (1991): Total axillary lymphadenectomy in the management of breast cancer. *Arch. Surg.*; 126: 1336-1342.
19. Chevionsky AH, Ferrara J, James AG, Minton JP, Young D, Farrar WB. (1990): Prospective evaluation of clinical and pathologic detection of axillary metastases in patients with carcinoma of the breast. *Surgery*; 108: 612-618.
20. Somers RG, Jablon LK, Keplan MJ, Sandler GL, Rosenblatt NK. (1992): The use of closed suction drainage after lumpectomy and axillary node dissection for breast cancer. A prospective randomized trial. *Ann. Surg.* ; 215: 146-149.
21. Jatoi L. (1999): Management of the axilla in primary breast cancer. *Surg. Clin. North. Am.*, 79(5): 1061-1073.
22. Roses DF, Brooks AD, Harris MN, Shapiro RL, Mintnick J. (1999): Complications of Level I and II axillary dissection in the carcinoma of the breast. *Ann. Surg.* ; 230(2): 194-201.
23. Knight CD, Griffen FD. (1995): Prevention of seromas in mastectomy wounds: The effect of shoulder immobilization. *Arch. Surg.*; 130: 99-101.
24. Jansen RF, Van Geel An, De Groot HG, Rottier AB, Oethuis GA, Pulten WL.(1990): Immediate versus delayed shoulder exercises after axillary lymph node dissection. *Am. J. Surg.* 160: 481-484.
25. Haldiuk M, Huchcroft S, Temple W, Schnurr BE. (1992): Arm function after axillary dissection for breast cancer: A pilot study to provide parameters estimates. *J. Surg. Oncol.*; 50: 47-52.
26. Dawson I, Stam L, Hespinga J M, Kalsbeek HL. (1989): Effect of shoulder immobilization on wound seroma and shoulder dysfunction following modified radical mastectomy: a randomized prospective trial. *Br. J. Surg.*; 76: 311-312.
27. Abdullah TI., Iddan J., Barr L., Baildan D, Bundred NJ. (1998): Prospective randomized controlled trial of preservation of the intercostobrachial nerve during axillary node clearance for breast cancer. *Br. J. Surg.*; 85: 1443-1445.
28. Lin PP, Allison DC, Wainstock J, Miller KD, Dooley WC, Friedman N. (1993): Impact of axillary lymph node dissection on the therapy of breast cancer patients. *J. Clin. Oncol.*; 11: 1536-1544.
29. Gerber L, Lampert M, Wood C, Duncan M, D Angelo T, Schain W. (1992): Comparison of pain, motion, and edema after modified radical mastectomy vs. local excision with axillary dissection and radiation. *Breast Cancer Res. Treat.*; 21: 139-145.
30. Gutman H, Kersz T., Brazilai T, Haddad M, Reiss R. (1990): Achievements of physical therapy in patients after modified radical mastectomy compared with quadrantectomy, axillary dissection, and radiation for carcinoma of the breast. *Arch. Surg.*; 125: 389-391.
31. Ganz PA. (1999): The quality of life after breast cancer-solving the problem of lymphedema. *N. Engl. J. Med.*; 340: 383-385.
32. Fredriksson I, Liljegren G, Arnesson LG, Amdin SO, Sjovall MP, Fornander T, Holmquist M, Holmberg L., Frisell J. (2002): Consequences of axillary recurrence after conservative breast surgery. *Br. J. Surg.*, 89: 902-908.