

## SURGICAL PHOTO QUIZ

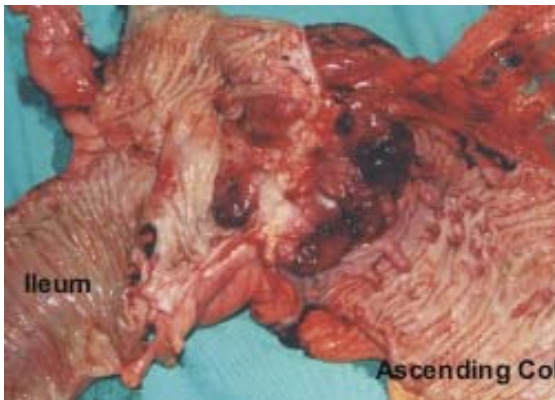
By

**Egyptian Group for Colorectal Surgeons**

*Ahmed A Abou-Zeid*

Professor of Surgery Ain Shams University

Email: ahabaz@hotmail.com



A male patient, 35 years old complained of diarrhoea and loss of weight of 7 months duration. Investigations revealed adenocarcinoma of the caecum. Metastatic workup showed that the tumour was restricted to the bowel. His brother had adenocarcinoma of the ascending colon at the age of 28 that was resected 2 years earlier. This same brother had metachronous tumour of the sigmoid colon that was discovered few weeks before the patient had his caecal tumour diagnosed. The father died of metastatic rectal cancer. The photograph shows the operative specimen of the patient. What do you recommend to treat this patient (Choose the best answer)?

1. Right hemicolectomy
2. Extended right hemicolectomy
3. Total colectomy, ileorectal anastomosis
4. Total proctocolectomy, terminal ileostomy
5. Restorative proctocolectomy

Send your answer to [ejs@ess-eg.org](mailto:ejs@ess-eg.org)

The correct answer and a short comment on the condition will be presented in the next issue of the journal.

### The correct answer for previous Photo Quiz (Vol 25, No 1, Jan., 2006)

The lesion is abdominal desmoid tumour and the original disease is familial adenomatous polyposis. FAP is a dominantly inherited polypoidal disease that is caused by an inherited germline mutation in the APC gene.

The disease is associated with innumerable colonic polyps that will definitely turn into cancer if not treated by total proctocolectomy. Extra colonic manifestations of the disease include gastric, duodenal and biliary neoplasms, osteomas, brain tumours, desmoid tumours and congenital hypertrophy of the retinal pigment epithelium (CHRPE). Desmoid tumours are problematic in their treatment because they often recur after resection.

They are the most common cause of death in FAP patients who had colonic resection.

