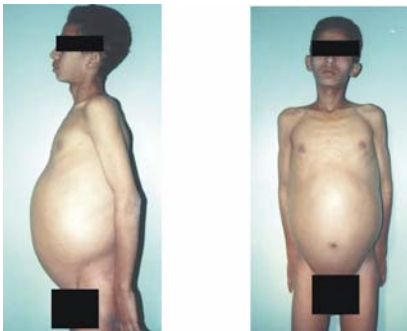


SURGICAL PHOTO QUIZ

By
Egyptian Group for Colorectal Surgeons
Ahmed A Abou-Zeid
Professor of Surgery Ain Shams University
Email: ahabaz@hotmail.com



Eighteen years old male complained of constipation dating since birth. He is on regular use of laxatives and enemas without which he could never evacuate. For the last month, he never opened bowel, he only passed flatus. What is the most probable diagnosis?

1. Simple constipation
2. Hirschsprung's disease
3. Acquired constipation secondary to anal problem
4. Slow transit constipation
5. Anorectal agenesis

Send your answer to ejs@ess-eg.org

The correct answer and a short comment on the condition will be presented in the next issue of the journal.

The correct answer for previous Photo Quiz (Vol 25, No 3, July, 2006)

The right answer is number 4. neoadjuvant radiochemotherapy followed by surgery.

Recent studies have shown that neoadjuvant radiochemotherapy significantly decrease the local recurrence rate in locally advanced rectal cancer. For this reason preoperative staging of rectal cancer is now mandatory. The best staging tools are endorectal ultrasound and MRI. CT is less accurate as a staging tool. T3 tumors (those infiltrating the perirectal fat), T4 tumors (those infiltrating nearby organ such as the prostate, seminal vesicles and vagina) and N1 tumors (those with positive perirectal nodal metastases) are considered locally advanced and thus are candidates for neoadjuvant radiochemotherapy. In the present photoquiz, despite mentioning that CT is less accurate in preoperative staging of rectal cancer, yet it is clear in the photograph that the tumor has infiltrated the perirectal fat with positive nodes (T3N1). Thus, neoadjuvant radiochemotherapy followed by surgery is probably the right decision for this patient.

