

## SURGICAL PHOTO QUIZ

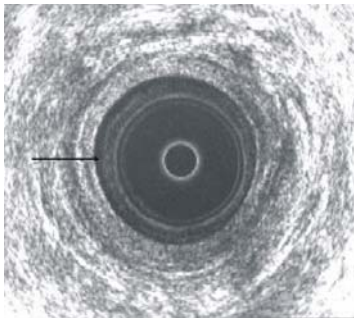
By

**Egyptian Group for Colorectal Surgeons**

*Ahmed A Abou-Zeid*

Professor of Surgery Ain Shams University

Email: ahabaz@hotmail.com



This is an ultrasound of a normal anal canal, the arrow is pointing to:

1. Probe / mucosa interface
2. Mucosa
3. Submucosa
4. Internal sphincter
5. External sphincter

Send your answer to [ejs@ess-eg.org](mailto:ejs@ess-eg.org)

The correct answer and a short comment on the condition will be presented in the next issue of the journal.

### The correct answer for previous Photo Quiz (Vol 26, No 3, July, 2007)

**The right answer is: Urgent contrast enema and proceed.**

Although the history of that patient is suggestive of large bowel cancer, yet the plain X ray abdomen shows large bowel obstruction with cut off at the level of the sigmoid colon. This plain X ray appearance is exactly the same in case of large bowel pseudo-obstruction, which is a disease with clinical and radiological findings similar to organic obstruction, however, without organic lesion. Pseudo-obstruction is common in patients with comorbid states such as respiratory failure, renal failure, cardiac disease, hepatic disease, electrolyte imbalance and old age. Surgery in case of pseudo-obstruction carries a high rate of mortality and thus should be avoided whenever possible. To exclude pseudo-obstruction, urgent contrast enema is done.

