

Accuracy of positron emission tomography-computed tomography in the assessment of metabolically negative axillary lymph nodes in breast cancer

Ahmed M. F. Salama^a, Mohamed R. Swilem^a, Ahmed Zidan^b,
Mohamed F. Sherif^c, Ahmed M. Nawar^a

^aDepartment of General Surgery,
Faculty of Medicine, Benha University, Benha,
Departments of ^bGeneral Surgery,
^cDiagnostic Radiology, Faculty of Medicine,
Tanta University, Tanta, Egypt

Correspondence to Mohamed R. Swilem, MSc,
Department of General Surgery, Faculty of
Medicine, Benha University, Qalubia Saad
Zaghloul Square, Benha 13511, Egypt.
Tel: +20 100 866 3457;
e-mail: phdoc97@gmail.com

Received: 14 December 2023

Revised: 10 January 2024

Accepted: 14 January 2024

Published: 22 March 2024

The Egyptian Journal of Surgery 2024,
43:502–509

Background

Breast cancer is a significant public health concern, and early detection of breast lesions is crucial for improved patient outcomes. Accurate assessment of axillary lymph node involvement in breast cancer is vital for staging and treatment decisions. The purpose of this study was to assess to what extent positron emission tomography (PET)-computed tomography (CT) can be used in the assessment of negative axillary lymph nodes in breast cancer and to determine if pathological variability can affect the result of the PET-CT.

Patients and methods

This prospective study was carried out on 50 female patients with locally advanced breast cancer and with negative PET-CT scans for active axillary lymph nodes. All studied cases underwent postoperative pathological examination to be compared with preoperative PET-CT results.

Results

Of the studied cases, 84% showed negative axillary lymph node involvement. PET/CT exhibited high sensitivity (95.24%) and specificity (87.5%) in predicting positive nodes, with an axillary maximum standardized uptake value cutoff value of 4.22 (area under the curve=0.923). Logistic regression revealed a significant association between higher T stage and positive lymph nodes ($P<0.05$).

Conclusion

PET/CT demonstrates strong predictive accuracy in detecting metabolically negative axillary lymph nodes in breast cancer patients.

Keywords:

axillary lymph nodes, breast cancer, maximum standardized uptake value, positron emission tomography/computed tomography

Egyptian J Surgery 43:502–509
© 2024 The Egyptian Journal of Surgery
1110-1121

Introduction

Breast cancer is the second most frequently diagnosed malignancy in the world after lung cancer, and more than two million new cases are seen each year. It is the leading cause of death in women around the world [1].

Axillary lymph node involvement is very important in terms of prognosis, staging, and treatment planning to be selected for managing the disease [2].

Axillary lymph node dissection (ALND) plays an essential role in the surgical management of breast cancer. The information obtained from pathologic examination of the removed lymph nodes helps to determine the pathologic staging of the disease and is an integral part of the treatment of breast cancer. ALND is beneficial for patients with breast cancer because it controls regional nodal disease and may improve overall survival [3].

Serious morbid complications, such as lymphedema of the arm, may occur after surgery or local radiotherapy to the axilla [4].

Positron emission tomography (PET) with integrated computed tomography (CT) using 18F-fluorodeoxyglucose (18F-FDG) is based on the principle of increased glucose metabolism in malignant tumors and has been investigated frequently in breast cancer [5].

FDG-PET/CT is used in the early stage to estimate the therapeutic response, reveal recurrent disease, and distal metastasis [6,7].

There is a general agreement about the high-diagnostic specificity of FDG-PET despite the well-known occurrence of false-positive results in diagnostic oncology with FDG-PET owing to concomitant inflammatory alteration. Nearly all recent investigations report a false-positive rate ranging

This is an open access journal, and articles are distributed under the terms of the Creative Commons Attribution-NonCommercial-ShareAlike 4.0 License, which allows others to remix, tweak, and build upon the work non-commercially, as long as appropriate credit is given and the new creations are licensed under the identical terms.

from 0 to 6%, and this is one of the reasons why several authors suggest that patients with FDG positive uptake should avoid sentinel lymph node biopsy (SLNB), and they should be directly addressed to ALND. In this case, FDG-PET can represent an alternative to SLNB [8,9].

Current technology available does not allow FDG-PET/CT to replace SLNB or ALND in the staging of the axilla in breast cancer, although this may change in the future with advancing technology [10]. At present, FDG-PET/CT may have a role to play in preselecting candidates for SLNB or ALND and thus avoid unnecessary surgery and potential morbidity [11,12].

The work aimed to assess to what extent PET-CT can be used in the assessment of negative axillary lymph nodes in breast cancer and to determine if pathological variability can affect the result of the PET-CT.

Patients and methods

Study design and patients

This prospective study involved 50 patients with confirmed breast cancer diagnoses. Participants were recruited from the Surgical Oncology Unit at the General Surgery Department, Faculty of Medicine, Benha University Hospital, and the General Surgery Department, Faculty of Medicine, Tanta University, between April 2021 and April 2023. The study was done after being approved by the Institutional Review Board, Faculty of Medicine, Benha University (IRB no: M.D 6.7.2021). Informed written consent was obtained from each patient, who also received an explanation of the study's purpose and a confidential code number.

Inclusion criteria were patients over 18 years requiring breast surgery for breast cancer, having undergone both PET/CT with negative results (locally advanced, T2, or T1 if PET/CT was available), and ALND or SLNB, all with a confirmed diagnosis of breast cancer. Exclusion criteria were those with positive PET/CT outcomes and pregnant women.

Patients with negative PET/CT results underwent axillary SLNB or axillary sampling (levels 1 and 2), and in cases where axillary SLNB was not available, all patients underwent primary breast tumor surgery.

SLNs shown during SLNB with open incision were shown in Fig. 1.

This study compares postoperative pathological findings with preoperative PET/CT results concerning axillary lymph nodes.

Methods

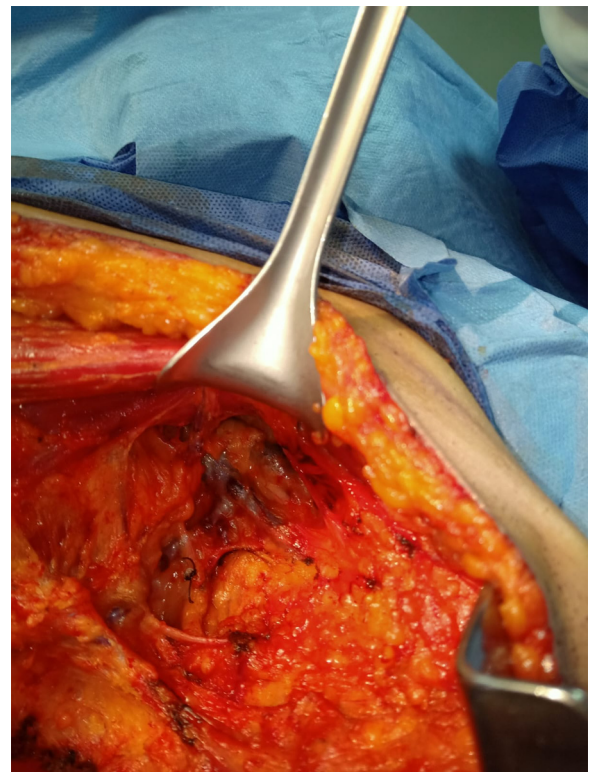
All cases under study underwent comprehensive assessments, starting with detailed history taking that included personal details (name, age, sex, and BMI), the current course and duration of the disease, past medical conditions or hospitalizations, and family medical history related to similar conditions. Thorough clinical examinations covered general assessments of vital signs such as pulse, blood pressure, respiratory rate, and temperature. Standard laboratory investigations encompassed complete blood count (hemoglobin, white blood cells, and platelets), kidney function tests, liver function tests, coagulation profiles, and if required, ECG and ECHO.

Preoperative evaluations involved clinical examinations and adherence to the PET/CT protocol.

Statistical analysis

The collected data were recorded, and subsequent processing was done using the Statistical Package for the Social Sciences (SPSS), 28.0 for Windows (SPSS Inc., Chicago, Illinois, USA). The Shapiro–Wilk test assessed data normality, while descriptive statistics (mean, SD, median, interquartile range for

Figure 1



SLNs shown during SLNB with open incision. SLNB, sentinel lymph node biopsy.

numerical data; frequency and percentage for nonnumerical data) provided a comprehensive summary. Logistic regression analysis explored variable relationships, with the odds ratio (OR) indicating association strength between exposure and outcome; an OR more than 1 denoted higher risk, less than 1 indicated a protective effect, and equal to 1 signified no impact. A 95% confidence interval was assessed OR precision, while significance was determined via *P* values (<0.05 considered significant) at a 95% confidence level.

Results

The mean age of the patients was 48.6 years, with a SD of 10.8 years. Approximately 48% of the cases were postmenopausal, while 52% were premenopausal. According to clinical staging, the majority of cases (88%) were classified as stage II, stage I represented only 2% of the cases, while 10% were classified as stage III (Table 1).

Lesions were bilateral in 6% of cases, while 94% of the cases were unilateral. Regarding the primary lesion site,

Table 1 Demographic and clinical data in the studied cases

Total cases (N=50)		
Age (years)	Mean±SD	48.6±10.8
	Median (interquartile range)	49 (45–55)
Menopausal status	Postmenopausal	24 (48)
	Premenopausal	26 (52)
Clinical staging	I	1 (2)
	II	44 (88)
	III	5 (10)

Quantitative data represented as mean±SD, median (interquartile range); qualitative data represented as *n* (%).

Table 2 Positron emission tomography-computed tomography examination among studied cases

Total cases (N=50)		
Laterality of lesion	Bilateral	3 (6)
	Unilateral	47 (94)
Site of primary lesion	Central region	6 (12)
	LIQ	5 (10)
	LOQ	12 (24)
	UIQ	5 (10)
	UOQ	22 (44)
T staging	T1	6 (12)
	T2	30 (60)
	T3	10 (20)
	T4	4 (8)
Size of lesion (cm)	3.7±1.2	
Size of LN (cm)	1.6±0.3	

Data represented as *n* (%) and mean±SD. LIQ, lower inner quadrant; LOQ, lower outer quadrant; UIQ, upper inner quadrant; UOQ, upper outer quadrant.

44% have lesions were located in the upper outer quadrant, making it the most common location. Other sites include the lower outer quadrant with 24%, the central region with 12%, the lower inner quadrant (LIQ) with 10%, and the upper inner quadrant (UIQ) with 10%. T1 tumors accounted for 12% of the cases, T2 tumors represented 60%, T3 tumors were 20%, and T4 tumors 8% of the cases. The mean size of the primary lesion was 3.7 cm, with a SD of 1.2 cm. The mean size of the axillary lymph nodes was 1.6 cm with a SD of 0.3 cm (Table 2).

In terms of pathology, 76% of the cases were classified as invasive ductal carcinoma (IDC), 16% were invasive lobular carcinoma, and 8% were of other pathological types. Regarding the pathological tumor grade, 14% of cases were classified as grade I, 52% as grade II, and 34% as grade III. For estrogen receptor expression, 46% of cases were negative, and 54% were positive. Regarding progesterone receptor expression, 48% of cases were negative, and 52% were positive. Regarding human epidermal growth factor (HER2) neu expression, 74% of cases were negative, while 26% were positive. Regarding molecular subtypes, 18% of cases exhibited HER2 neo-overexpression, 36% were classified as luminal A, 16% as luminal B, and 30% as triple negative. Among the studied cases, 84% have pathologically negative axillary lymph node status, indicating the absence of cancerous involvement in the axillary lymph nodes. On the other hand, 16% of the cases showed pathologically positive cancerous involvement in axillary lymph node histology (Table 3).

Table 3 Pathological examination in the studied cases

Total cases (N=50)		
Pathology	IDC	38 (76)
	ILC	8 (16)
	Others	4 (8)
Pathological tumor grade	GI	7 (14)
	GII	26 (52)
	GIII	17 (34)
ER	Negative	23 (46)
	Positive	27 (54)
PR	Negative	24 (48)
	Positive	26 (52)
HER2 neu	Negative	37 (74)
	Positive	13 (26)
Molecular subtype	HER2 neo-overexpression	9 (18)
	Luminal A	18 (36)
	Luminal B	8 (16)
	Triple negative	15 (30)
Axillary LN status	Negative	42 (84)
	Positive	8 (16)

Data represented as *n* (%). ER, estrogen receptor; HER2 neu, human epidermal growth factor; IDC, invasive ductal carcinoma; ILC, invasive lobular carcinoma; PR, progesterone receptor.

PET-CT results compared to pathology showed that PET scan results showed high sensitivity, specificity, and accuracy in the prediction of pathological diagnosis (Table 4).

The average size of the lesion for cases with positive nodes was 4.96 ± 0.98 cm, while for cases with negative nodes, it was 3.46 ± 1.15 cm with a cut-off value of 4.5 cm. A significant association between the size of the lesion and pathology results ($P=0.003$). The average size of the lymph node for cases with positive nodes was 2.04 ± 0.25 cm, whereas for cases with negative nodes, it was 1.5 ± 0.2 cm with a cut-off value of 1.73 cm. The statistical analysis indicates a highly significant association between the size of the lymph node and pathology results ($P < 0.001$). According to the axillary maximum standardized uptake value (SUV_{max}) in studied cases, positive nodes showed significantly higher SUV_{max} than negative nodes with a cut-off value of about 4.22 ($P < 0.001$; Table 5).

Receiver operating characteristic (ROC) curve of lesion size was conducted to predict positive and negative nodes. The size of the lesion showed high, moderate area under the curve (AUC) (AUC=0.844) for the prediction of positive nodes (Fig. 2).

The ROC curve of lymph node size was conducted to predict positive and negative nodes. The size of the lymph node showed a high, moderate AUC (AUC=0.832) for the prediction of positive nodes (Fig. 3).

The ROC curve of axillary SUV_{max} was conducted to predict positive and negative nodes. The axillary

Table 4 Agreement between positron emission tomography-computed tomography and pathology results

	True	False	Sensitivity (%)	Specificity (%)	P value
Axillary LN status	42	8	84	88	<0.001*

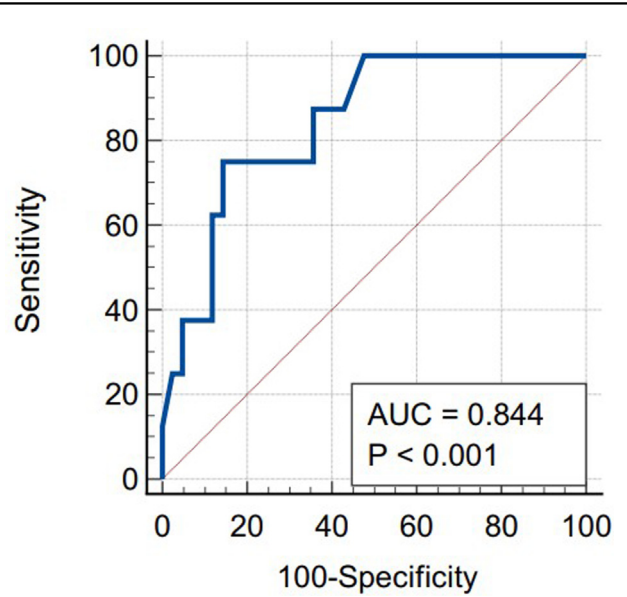
LN, lymph node. *Significant as P -value < 0.05.

Table 5 Association between size of lesion and pathology results, size of lymph nodes and pathology results and axillary maximum standardized uptake value and pathology results

	Total cases=50			Test	P
	Positive nodes (N=8)	Negative nodes (N=42)	Cut-off value		
Size of lesion (cm)	4.96 ± 0.98	3.46 ± 1.15	4.5	2.849	0.003*
Size of lymph node (cm)	2.04 ± 0.25	1.5 ± 0.2	1.73	4.375	<0.001*
Axillary LN SUV_{max}	5.97 (5.54–6.38)	2.41 (1.50–4.28)	4.22	3.758	<0.001*

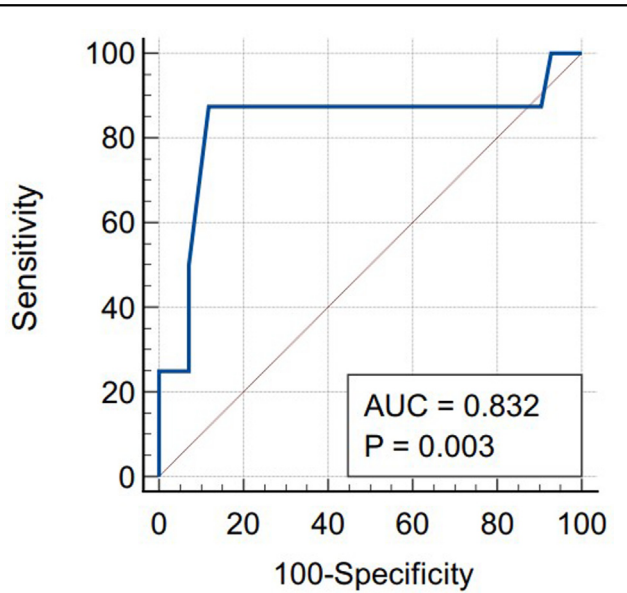
LN, lymph node; SUV_{max} , maximum standardized uptake value. Test, Mann–Whitney test. *Significance ($P < 0.05$).

Figure 2



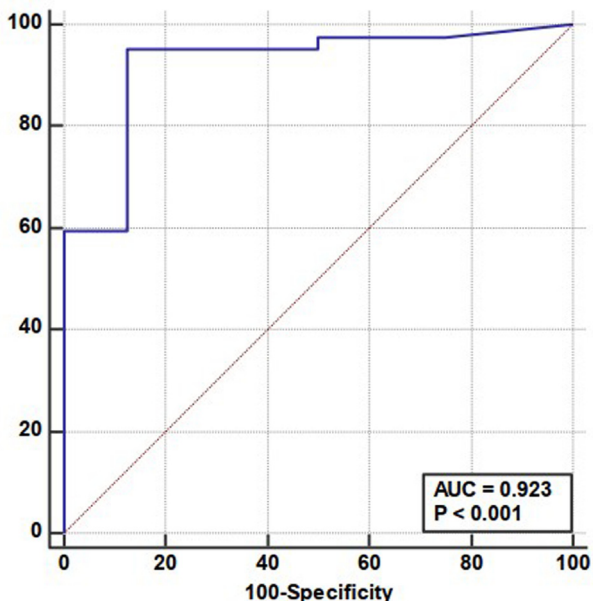
ROC curve analysis of size of lesion. ROC, receiver operating characteristic.

Figure 3



ROC curve analysis of size of lymph node. ROC, receiver operating characteristic.

Figure 4



ROC curve analysis of axillary SUV_{max} . ROC, receiver operating characteristic; SUV_{max} , maximum standardized uptake value.

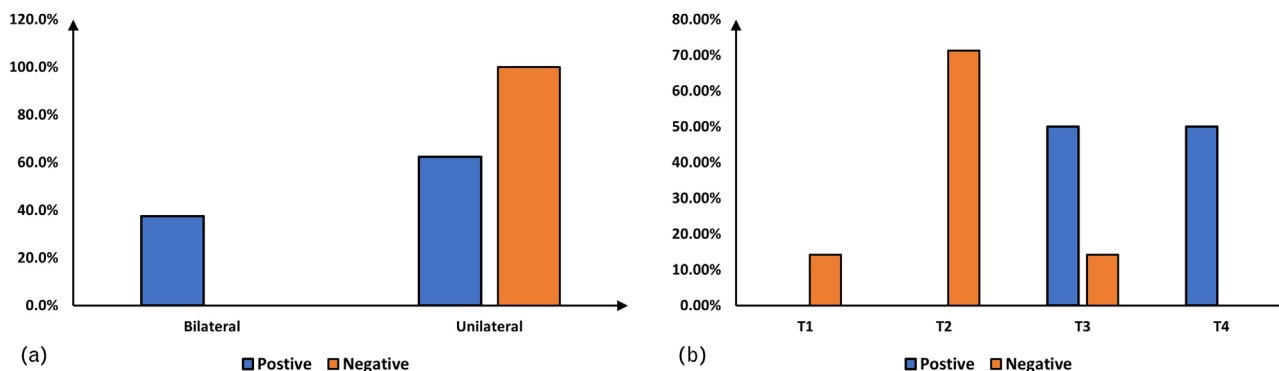
SUV_{max} showed high accuracy AUC (AUC=0.923) for the prediction of positive nodes (Fig. 4).

According to the association between the bilaterality of lesions and pathology results, the proportion of cases with bilateral lesions is significantly higher in the group with positive nodes compared to the group with negative nodes ($P=0.002$). However, the association between bilaterality and the presence of negative nodes does not appear to be statistically significant ($P=0.316$) (Fig. 5a).

Among the cases with positive nodes, there were no T1 or T2 tumors, while T3 and T4 tumors accounted for 50.0% of the cases each. In contrast, among the cases with negative nodes, T2 tumors were the most prevalent, accounting for 71.4% of the cases. A significantly higher proportion for of T3 ($P<0.04$) and T4 ($P <0.001$) among the positive group compared to the negative group (Fig. 5b).

Logistic regression analysis was conducted to predict positive and negative lymph nodes using age, menopause, laterality, size of lesion, size of lymph node, and tumor stage. Bilateral lesions, large-sized lesions, large-size lymph node, and high tumor T stage (3–4) were associated with an increased probability of positive lymph nodes in univariate analysis. High T stage was associated with a decreased probability of negative lymph nodes in multivariate analysis (Table 6).

Figure 5



(a) Association between pathology results and bilaterality of lesion and (b) distribution of tumor stages according to pathology results.

Table 6 Regression analysis for risk factors of positive lymph node status

	Univariate analysis			Multivariate analysis		
	P	OR	95% CI	P	OR	95% CI
Age	0.215	0.976	0.939–1.014	–	–	–
Menopausal status	0.100	0.874	0.866–5.189	–	–	–
Bilateral lesions	0.045*	4.798	1.032–22.304	–	–	–
Large size of lesion	0.027*	1.651	1.445–1.953	–	–	–
Size of LN	0.04*	1.246	1.012–1.631	–	–	–
Tumor stage (3–4)	0.021*	1.543	1.534–3.229	0.048*	1.214	1.030–1.482

CI, confidence interval; OR, odds ratio; LN, lymph node. *Significant ($P<0.05$).

Discussion

Breast cancer is the most frequent type of cancer in women. Several treatment weapons (surgery, radiation therapy, chemotherapy, targeted therapy, and endocrine therapy) are available [13]. To use optimal treatment for a given patient, however, the biological characteristics of the tumor and the precise staging of the disease need to be known. In particular, the presence or absence of distant metastases should be assessed [14].

Axillary lymph node involvement is an important predictive factor for recurrence and the most reliable prognostic factor in patients with primary breast cancer. Accurate information on axillary lymph node involvement is critical before treatment, helps in decision-making and guides prognosis [15].

SLNB and ALND are currently the surgical methods for accurate staging of the axilla in cN0 patients, but they are accompanied by many adverse reactions, including arm lymphedema, paresthesia, and shoulder dysfunction or numbness [16].

Integrated PET/CT with 18F-FDG is recommended for T2–T4 staging or clinically locally advanced breast cancer. This imaging modality is efficient in exploring the axillary lymph node status and detecting metastatic lesions, with high sensibility and specificity (respectively 56–77% and 96–100%) [17]. The 18F-FDG uptake, the SUV_{max} , reflects lesion behavior [18].

This prospective study has been carried out on 50 female patients with early or locally advanced breast cancer and with negative PET-CT scans for active axillary lymph nodes. All studied cases underwent postoperative pathological examination to be compared with preoperative PET-CT results. Lymph node harvesting has been done by either SLNB or ALND.

According to demographic data of the studied cases, the mean age of the patients was 48.6 years with a SD of 10.8 years. Approximately 48% of the cases were postmenopausal, while 52% were premenopausal.

In agreement with our study, Straver and colleagues assessed the accuracy of 18F-FDG-PET/CT to visualize lymph node metastases before the start of neoadjuvant chemotherapy. Thirty-eight patients with invasive breast cancer with a mean age of the patients was 49 years (range: 30–68) [19].

Furthermore, Fuster and colleagues evaluated the utility of PET and 18F-FDG in the initial staging of large primary breast tumors. Sixty consecutive patients with large (>3 cm) primary breast cancer were entered into the study. The mean age was 57 ± 13 years [20].

According to clinical staging, the majority of cases (88%) were classified as stage II. Stage I represented only 2% of the cases, while 10% were classified as stage III.

Also, Önner and colleagues, who compared both PET-CT and CT and their association with prognostic factors of breast cancer, concluded that according to the clinical T groups, there were 25 (26.6%) patients in the T1c group, 52 (55.3%) patients in the T2 group, 11 (11.7%) patients in the T3 group, and six (6.4%) patients in the T4 group [21].

According to this study, lesions were bilateral in 6% of cases, while in 94% of the cases were unilateral. Regarding the primary lesion site, 44% have lesions in the upper outer quadrant, making it the most common location. Other sites include the lower outer quadrant with 24%, the central region with 12%, the lower inner quadrant with 10%, and the upper inner quadrant with 10%. T1 tumors accounted for 12% of the cases, T2 tumors represented 60%, T3 tumors were 20%, and T4 tumors 8% of the cases.

Parallel to our findings, Kamal and colleagues determined the diagnostic usefulness of PET/CT in the initial assessment of patients with newly diagnosed breast cancer who were referred for tumor staging, pretherapeutic, or preoperative evaluation. It was observed that PET/CT revealed lesions in the right breast in 26 (52%) patients, the left breast in 20 (40%) patients, and bilaterally in four (8%) individuals. As regards T staging (local tumor staging) by both CT and PET/CT, seven (14%) patients were staged as T1, 37 (74%) patients were staged as T2, four (8%) patients were staged as T3, and two (4%) patients were staged as T4 stage [22].

Regarding pathology, 76% of the cases were classified as IDC, 16% were invasive lobular carcinoma, and 8% of the cases were other pathological types. Regarding the pathological tumor grade, 14% of cases were classified as grade I, 52% as grade II, and 34% as grade III.

In agreement with our findings, Alshaibani and colleagues evaluated the accuracy of PET-CT scan

in detecting axillary lymph node metastases compared to the pathology results in patients with primary breast cancer. Twenty-one newly diagnosed females with invasive breast cancer were staged using FDG-PET-CT scan. Eighteen (85.7%) patients had IDC, one (4.8%) had medullary carcinoma, and one (4.8%) had mucinous carcinoma. Grade I was in three (14.3%), grade II presented in 11 (52.4%), and grade III presented in seven (33.3%) [23].

In this study, for estrogen receptor expression, 46% of cases were negative, and 54% were positive. Regarding progesterone receptor expression, 48% of cases were negative, and 52% were positive. Regarding HER2 neu expression, 74% of cases were negative, while 26% were positive. Regarding molecular subtypes, 18% of cases exhibited HER2 neo-overexpression, 36% were classified as luminal A, 16% as luminal B, and 30% as triple negative.

In the current work, among the studied cases, 84% have negative axillary lymph node status, indicating the absence of cancerous involvement in the axillary lymph nodes. On the other hand, 16% of the cases showed positive cancerous involvement in axillary lymph node histology.

Veronesi and colleagues compared SLNB and FDG-PET/CT in detecting occult axillary metastases, FDG-PET/CT was negative in 193 (81%) cases. Of those 193 patients, 128 patients showed pathologically negative SLNB, while 65 were positive. Thus, FDG-PET/CT was unable to detect occult axillary metastases in one-third of cases [24].

According to Sasada and colleagues, who studied the ability to identify axillary lymph node metastasis in patients with breast cancer using dual-phase FDG-PET/CT, the sensitivity and specificity of FDG-PET/CT for detecting axillary lymph node metastasis were 74.7 and 83.4%, respectively [25].

According to Zhang and colleagues, who studied the relation between SUV_{max} and the incidence of lymph node metastasis. The SUV_{max} values were significantly different between metastatic and nonmetastatic lymph nodes in both the early and delayed scans ($P < 0.001$). For metastatic lymph nodes, the SUV_{max} value on the delayed scan (6.17 ± 2.62) was significantly higher compared with the early scan (5.45 ± 1.35 ; $\Delta SUV_{max} = 0.08 \pm 0.21$, $P < 0.001$). Moreover, the SUV_{max} values were not significantly different between the delayed (2.82 ± 0.91) and early scans (2.79 ± 0.72 ; $\Delta SUV_{max} = -0.00 \pm 0.11$, $P = 0.77$) in nonmetastatic lymph nodes [26].

In the multivariate analysis, larger tumor size, nuclear grade III, high axillary SUV_{max1} , and positive axillary RI were independent predictive factors of lymph node metastasis, and the molecular subtype was not significant.

The study had several limitations worth noting. First, being a single-center study with a relatively small sample size, the generalizability of the findings might be restricted. Second, the study did not delve into the various methods of treatment, which could have provided a more comprehensive understanding. Additionally, the exclusion of PET-CT positive cases and pregnant women might have narrowed the scope of observations.

Conclusion

In conclusion, PET/CT is a precise, noninvasive method with high sensitivity and specificity in the assessment of negative axillary lymph nodes. Univariate analysis linked bilateral and large lesions, along with high tumor T stages (3–4), to positive lymph nodes. The multivariate analysis emphasized the association between the high T stage and the risk of positive lymph nodes.

Acknowledgments

The actual work was done at Surgical Oncology Unit at the General Surgery Department, Faculty of Medicine, Benha University Hospital, and the General Surgery Department, Faculty of Medicine, Tanta University.

Authors' contributors: all authors made a significant contribution to the work reported, whether that is in the conception, study design, execution, acquisition of data, analysis, and interpretation, or all these areas; took part in drafting, revising, or critically reviewing the article; gave final approval of the version to be published; have agreed on the journal to which the article has been submitted; and agree to be accountable for all aspects of the work. The manuscript has been read and approved by all the authors.

Financial support and sponsorship

Nil.

Conflicts of interest

There are no conflicts of interest.

References

- Łukaszewicz S, Czeczeliwski M, Forma A, Baj J, Sitarz R, Stanistawek A. Breast cancer-epidemiology, risk factors, classification, prognostic markers, and current treatment strategies – an updated review. *Cancers (Basel)* 2021; 13:4287.

- 2 Mohammed AA. Predictive factors affecting axillary lymph node involvement in patients with breast cancer in Duhok: cross-sectional study. *Ann Med Surg (Lond)* 2019; 44:87–90.
- 3 Abass MO, Gismalla MDA, Alsheikh AA, Elhassan MMA. Axillary lymph node dissection for breast cancer: efficacy and complication in developing countries. *J Glob Oncol* 2018; 4:1–8.
- 4 Rupp J, Hadamitzky C, Henkenberens C, Christiansen H, Steinmann D, Bruns F. Frequency and risk factors for arm lymphedema after multimodal breast-conserving treatment of nodal positive breast cancer – a long-term observation. *Radiat Oncol* 2019; 14:39.
- 5 Lang BH. The role of 18F-fluorodeoxyglucose positron emission tomography in the prognostication, diagnosis, and management of thyroid carcinoma. *J Thyroid Res* 2012; 2012:198313.
- 6 Kitajima K, Nakajo M, Kaida H, Minamimoto R, Hirata K, Tsurusaki M, *et al.* Present and future roles of FDG-PET/CT imaging in the management of gastrointestinal cancer: an update. *Nagoya J Med Sci* 2017; 79:527–543.
- 7 Shawky M, Ali ZAE, Hashem DH, Houseni M. Role of positron-emission tomography/computed tomography (PET/CT) in breast cancer. *Egypt J Radiol Nucl Med* 2020; 51:125.
- 8 Al-Ibraheem A, Buck A, Krause BJ, Scheidhauer K, Schwaiger M. Clinical applications of FDG PET and PET/CT in head and neck cancer. *J Oncol* 2009; 2009:208725.
- 9 Narayanan P, Sahdev A. The role of (18)F-FDG PET CT in common gynaecological malignancies. *Br J Radiol* 2017; 90:20170283.
- 10 Robertson IJ, Hand F, Kell MR. FDG-PET/CT in the staging of local/regional metastases in breast cancer. *Breast* 2011; 20:491–494.
- 11 Heusner TA, Kuemmel S, Hahn S, Koeninger A, Otterbach F, Hamami ME, *et al.* Diagnostic value of full-dose FDG PET/CT for axillary lymph node staging in breast cancer patients. *Eur J Nucl Med Mol Imaging* 2009; 36:1543–1550.
- 12 Hadebe B, Harry L, Ebrahim T, Pillay V, Vorster M. The role of PET/CT in breast cancer. *Diagnostics (Basel)* 2023; 13:597.
- 13 Burguin A, Diorio C, Durocher F. Breast cancer treatments: updates and new challenges. *J Pers Med* 2021; 11:808.
- 14 Groheux D, Hindie E. Breast cancer: initial workup and staging with FDG PET/CT. *Clin Transl Imaging* 2021; 9:221–231.
- 15 Zong Q, Deng J, Ge W, Chen J, Xu D. Establishment of simple nomograms for predicting axillary lymph node involvement in early breast cancer. *Cancer Manag Res* 2020; 12:2025–2035.
- 16 Chen K, Yin G, Xu W. Predictive value of (18)F-FDG PET/CT-based radiomics model for occult axillary lymph node metastasis in clinically node-negative breast cancer. *Diagnostics (Basel)* 2022; 12:997.
- 17 Ko H, Baghdadi Y, Love C, Sparano JA. Clinical utility of 18F-FDG PET/CT in staging localized breast cancer before initiating preoperative systemic therapy. *J Natl Compr Canc Netw* 2020; 18:1240–1246.
- 18 Parisse-Di Martino S, Faure C, Moggetti T. Discordant results in (18)F-FDG PET/CT and ultrasound-based assessment for axillary lymph node metastasis detection: A large retrospective analysis in 560 patients with breast cancer. *Cancer Treat Res Commun* 2021; 27:100344.
- 19 Straver ME, Aukema TS, Olmos RAV, Rutgers EJT, Gilhuijs KGA, Schot ME, *et al.* Feasibility of FDG PET/CT to monitor the response of axillary lymph node metastases to neoadjuvant chemotherapy in breast cancer patients. *Eur J Nucl Med Mol Imaging* 2010; 37:1069–1076.
- 20 Fuster D, Duch J, Paredes P, Velasco M, Muñoz M, Santamaría G, *et al.* Preoperative staging of large primary breast cancer with [18F] fluorodeoxyglucose positron emission tomography/computed tomography compared with conventional imaging procedures. *J Clin Oncol* 2008; 26:4746–4751.
- 21 Öner H, Canaz F, Dinçer M, Işiksoy S, Sivriköz İA, Entok E, *et al.* Which of the fluorine-18 fluorodeoxyglucose positron emission tomography/computerized tomography parameters are better associated with prognostic factors in breast cancer? *Medicine (Baltimore)* 2019; 98:e15925.
- 22 Kamal AM, Kamal OA, Sakr HM, Ali SA. Role of 18F-FDG PET/CT in evaluation of recently diagnosed breast cancer patients. *Egypt J Radiol Nucl Med* 2022; 53:178.
- 23 Alshaibani N, Hamza E, Baithun S, Meer H, Aljowder A, Salem Y. The accuracy of PET-CT scan in detecting axillary lymph node metastasis in breast cancer. *Bahrain Med Bull* 2017; 39:20–23.
- 24 Veronesi U, De Cicco C, Galimberti VE, Fernandez JR, Rotmensz N, Viale G, *et al.* A comparative study on the value of FDG-PET and sentinel node biopsy to identify occult axillary metastases. *Ann Oncol* 2007; 18:473–478.
- 25 Sasada S, Masumoto N, Kimura Y, Kajitani K, Emi A, Kadoya T, *et al.* Identification of axillary lymph node metastasis in patients with breast cancer using dual-phase FDG PET/CT. *Am J Roentgenol* 2019; 213:1129–1135.
- 26 Zhang J, Shi X, Xiao Y, Ma C, Cao G, Liu Y, *et al.* Early SUV(max) is the best predictor of axillary lymph node metastasis in stage III breast cancers. *Quant Imaging Med Surg* 2021; 11:1680–1691.