

SURGICAL QUIZ

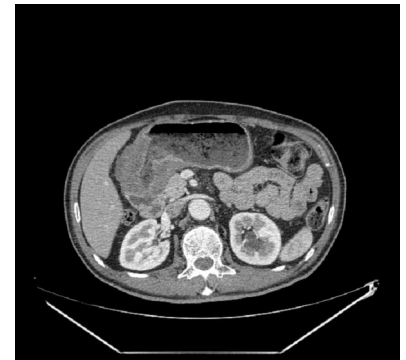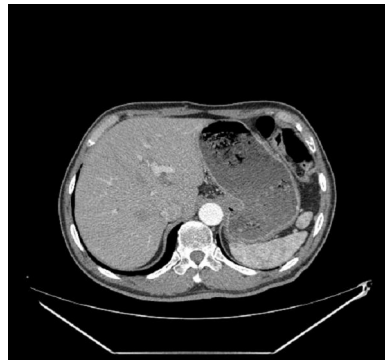Mohamed Selimah

Lecturer of Surgery. Medical Research Institute, Alexandria University.

Email: mselima@gmail.com

A 50 year old male patient presented with loss of weight, epigastric fullness, nausea, and vomiting after eating. Which of the following represents the most likely diagnosis for this patient?

- A) Ulcer scar
- B) Benign gastric ulcer
- C) Probably benign (equivocal) gastric ulcer
- D) Malignant gastric ulcer



Images kindly provided by Omega Scan, Alexandria, Egypt

Send your answer to ejs@ess-eg.org

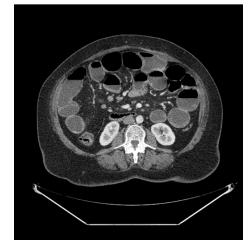
The correct answer and a short comment on the condition will be presented in the next issue of the journal.

The correct answer for previous Photo Quiz (Vol. 28, No. 4, October, 2009)

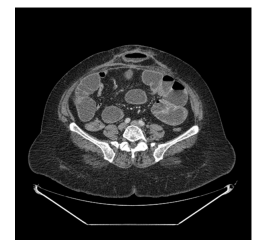The right answer is (C): Recurrent ventral hernia

The small bowel is markedly dilated with multiple air fluid levels. The colon, however, is collapsed. Image 2 shows a recurrent hernia with small bowel loop in the hernia sac.

The most common cause of small bowel obstruction (SBO) in adults is postsurgical adhesions. The second most common identified cause of SBO is an incarcerated groin hernia. Other etiologies of SBO include malignant tumor (20%), hernia (10%), inflammatory bowel disease (5%), volvulus (3%), and miscellaneous causes (2%).



1



2