

SURGICAL QUIZ

Mohamed Said,¹ Ahmed Hazem Helmy²

¹Assistant Professor of General & Hepatobiliary Surgery, ²Professor of General & Hepatobiliary Surgery, Head of Department of General Surgery & Experimental Surgical Unit, Theodore Bilharze Research Institute, Egypt

Correspondence to: Mohamed Said, Email: hedayamsm@yahoo.com

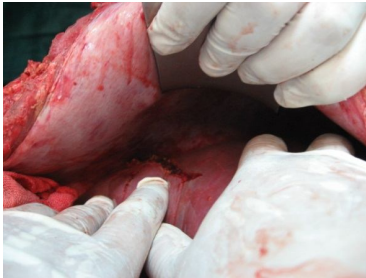


Fig. 1

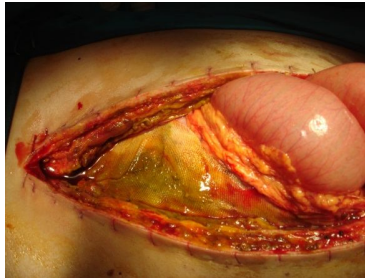


Fig. 2

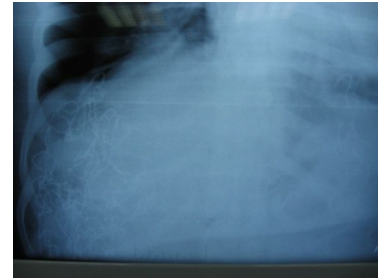


Fig. 3

Male patient 23 years old with motor car accident presented with shock immediate exploration and blood transfusion was done followed by redo after 3 days.

What was the injury in Fig 1?

X ray in Fig 2 is postoperative shows -----

What was done in first procedure and in redo?

Please Send your answer to ejs@ess-eg.org

The correct answer and a short comment on the condition will be presented in the next issue of the journal.

The correct answer for previous Photo Quiz (Vol. 30, No. 2, April, 2011)

Answer:

1-What is the operative procedure?
Exploration of the common bile duct.

2-What are the figures shown above?
Intraoperative cholangiogram-t tube
cholangiogram-choledochoscopy.

3-What sort of follow up after discharge?
Bilirubin total and direct.

