

SURGICAL QUIZ

Mohammed Hedaya,¹ Ahmed Hazem Helmy²

¹Assistant Professor of General & Hepatobiliary Surgery, ²Professor of General & Hepatobiliary Surgery, Head of Department of General Surgery & Experimental Surgical Unit, Theodore Bilharze Research Institute, Egypt

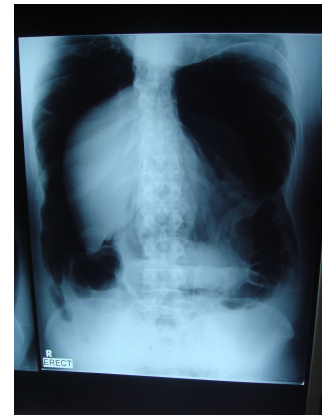
Correspondence to: Mohammed Said, Email: hedayamsm@yahoo.com

Male patient 33 years old after colonoscopy his main complaint was abdominal pain and dyspnea.

1-This x ray shows ----

2-What is the most likely diagnosis?

3-What is the proper management?



Please Send your answer to ejs@ess-eg.org

The correct answer and a short comment on the condition will be presented in the next issue of the journal.

The correct answer for previous Photo Quiz (Vol. 30, No. 3, July, 2011)

Answer:

Injury in fig1 was extensive parenchymatous liver damage.
Postoperative x ray shows radiopaque thread of perihepatic packs.
Perihepatic packing then removal of packs.

