

# Impact of concomitant vascular injury on the outcome of bile duct injury

Ahmed Sallam, Ibrahim Marwan, Motasem M. Ali, Abdelrahman Gamal, Saleh Khairy, Islam Ayoub, Ahmed Attia, Ghadier Saaed, Osama Hegazy

Department of HPB Surgery, National Liver Institute, Menoufia University, Menoufia, Egypt

Correspondence to Abdelrahman Gamal, MD, El Minya, Abrag El Atbaa, Kornish El Nil, Tower 11, Postal Code 6111. Mob: +0100 442 3383; e-mail: abdelrahmansaleh90@gmail.com

**Received:** 20 February 2023

**Revised:** 17 March 2023

**Accepted:** 26 March 2023

**Published:** 11 August 2023

**The Egyptian Journal of Surgery** 2023, 42:502–508

## Background

Compared with open cholecystectomy, the frequency of iatrogenic bile duct damage (bile duct injury) has almost doubled as laparoscopic cholecystectomy (LC) has become more prevalent. The authors aimed to analyze the prevalence of postcholecystectomy vasculobiliary injury and its influence on illness and death.

## Methods

Medical records were reviewed on 50 consecutive patients with iatrogenic bile duct injuries from either open or laparoscopic cholecystectomy who were treated at the National Liver Institute, Menoufia University between January 1, 2020 and October 31, 2022.

The medical records were examined for patient demographics and preoperative and postoperative clinical scenarios, which included symptoms, operative procedures, diagnostic methods, operative repairs, length of ICU and Hospital stays, postoperative follow-up, short- and long-term complications, need for radiographic or operative revision, and patient mortality.

## Results

The studied patients were allocated into two groups, according to presence of concomitant vascular injury; group A: cases did not develop concomitant vascular injury, group B: cases developed concomitant vascular injury. Vascular injury was significantly elevated in males than those without vascular injury ( $P=0.027$ ). There were no significant variance among the studied groups as regard Hospital stay and ICU admission. There was no significant variance among the studied groups as regard short-term complications. There was a significant variance among the studied groups as regard long-term complications ( $P=0.003$ ). Right lobe atrophy was significantly elevated in vascular injury cases than those without vascular injury.

## Conclusions

Concomitant vascular injury postcholecystectomy prevalence was significantly associated with long-term complications; right lobe atrophy was significantly elevated in vascular injury cases than those without vascular injury.

## Keywords:

bile duct injury, concomitant vascular injury, outcome

Egyptian J Surgery 42:502–508  
© 2023 The Egyptian Journal of Surgery  
1110-1121

## Introduction

Iatrogenic biliary injuries during cholecystectomy are a major surgical complication that may have catastrophic effects, including an elevated risk of premature mortality [1,2].

Due to the increasing use of laparoscopic cholecystectomy (LC), iatrogenic bile duct injury (BDI) frequency has almost doubled when compared with open cholecystectomy [3,4].

In order to define the type of BDI, several classifications of BDI have been proposed, but none is universally accepted as each of them has its own limitation. Patient's condition, timing of recognition of injury, and the presence of sepsis are not accounted in these classification systems. Among them, Bismuth's

classification and Strasberg's classification are most commonly used by clinicians [5].

Given that BDI sustained during LC is reported to happen more proximally than during open cholecystectomy and that mistaken identity of the anatomy is not restricted to the biliary tree, an elevated concomitant hepatic artery injury (HAI) frequency can be predicted [6,7].

HAI may follow BDI, with the most frequent injury type including the right hepatic artery (RHA) in

This is an open access journal, and articles are distributed under the terms of the Creative Commons Attribution-NonCommercial-ShareAlike 4.0 License, which allows others to remix, tweak, and build upon the work non-commercially, as long as appropriate credit is given and the new creations are licensed under the identical terms.

conjunction with a debridement damage of the common hepatic duct, owing to the closeness of the artery and duct [6,8].

Although concurrent bile duct and hepatic artery damage is an increasingly reported consequence of LC, the clinical significance of concurrent vascular injury remains unclear. In healthy individuals, interruption of the hepatic artery flow is often easily tolerated. The well-described vulnerability of the bile duct to ischemia damage may lead to the higher incidence during biliary reconstruction [9,10].

It is difficult to determine the HAI prevalence in relation to BDI, since few papers on BDI cover the issue and the majority of series feature highly chosen case groups in the setting of BDI. In addition, it is sometimes challenging to evaluate the state of the RHA during procedures to treat a BDI, since the RHA is frequently engaged in an inflammatory process due to bile leakage, tissue injury, and infection. In addition, regular vascular imaging is seldom done during the evaluation of such accidents. Therefore, the frequency of vascular damage is most likely understated [11,12].

RHA damage was a major predictor of biliary reconstruction poor long-term patency because stricture development following biliary reconstruction is more prevalent in individuals with an associated RHA injury than in those without vascular injury [13,14].

## Patients and methods

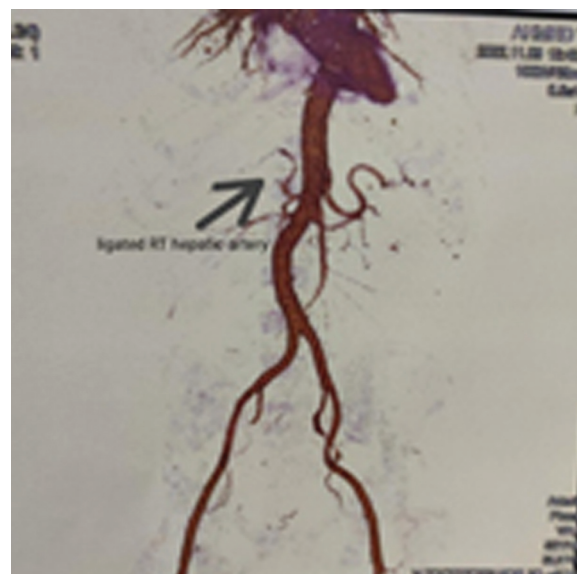Medical records were reviewed on 50 consecutive patients with iatrogenic bile duct injuries from either open or LC who were treated at the National Liver Institute-Menoufia University between January 1, 2020 and October 31, 2022.

The medical records were examined for patient demographics and preoperative and postoperative clinical scenarios, which included clinical presentation, classification of BDI according to Strasberg classification either by magnetic resonance cholangiopancreatography (MRCP) or endoscopic retrograde cholangiopancreatography (ERCP), operative procedures, diagnostic methods, time of intervention classified into immediate (during the first 72 h), intermediate (between 72 h and 1.5 months) and late (after 1.5 months), operative repairs, length of ICU and Hospital stays, postoperative follow-up, short- and long-term

complications, need for radiographic or operative revision, and patient mortality.

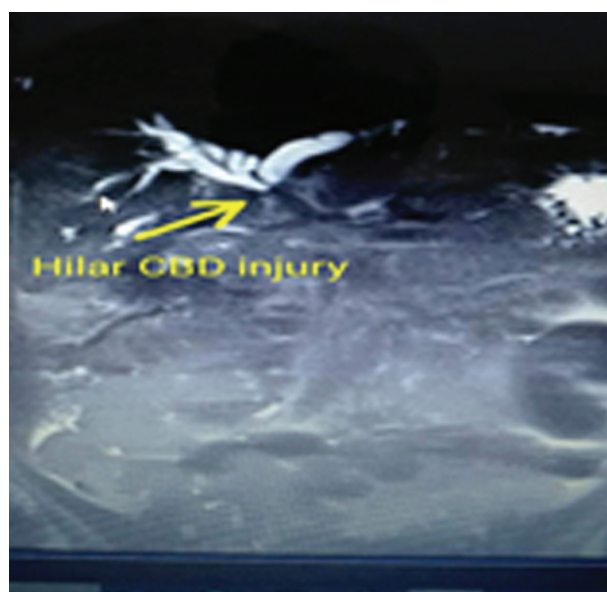
Multiple diagnostic methods were used to define biliary injuries, including surgical recognition, ERCP and percutaneous transhepatic cholangiography, and MRCP (Fig. 1). Arterial injuries were identified intraoperatively or defined by hepatic arteriograms (Fig. 2). Primary management, defined as all therapeutic interventions performed after recognition of bile duct injuries, included surgical intervention,

**Figure 1**



Magnetic resonance cholangiopancreatography show iatrogenic bile duct injury strasberg class E2.

**Figure 2**



Computed tomography hepatic angiography show interruption of right hepatic artery.

endoscopic or percutaneous transhepatic dilation, and stenting. Failed interventions were defined by either biliary obstruction or recurrent cholangitis associated with a radiographically defined biliary stricture.

Surgical management of BDI involve identification of the common hepatic duct either at the proximal common hepatic duct or at the level of the hepatic duct confluence. All fibrotic material was excised, and Roux En Y biliary-enteric anastomosis was performed using 5-0 absorbable monofilament sutures Fig. 3.

Surgical management of vascular injury involve either reconstruction, repair of injured vessel if diagnosed intraoperative or trial of reconstruction of ligated vessel if diagnosed later.

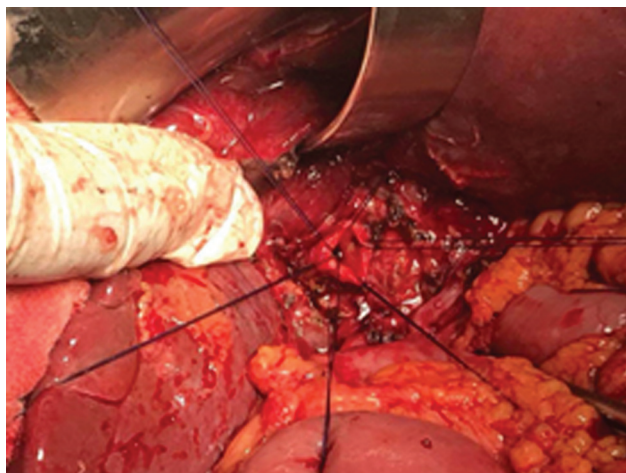
All patients were followed as outpatients. Management failures were defined as patients requiring further invasive procedures to correct either biliary obstruction or recurrent episodes of cholangitis. Once identified, these patients were studied by percutaneous transhepatic cholangiography, and, when applicable, angioplasty or stenting was implemented. Surgical revision was reserved for radiologic treatment failures.

All data are presented as mean±SD. Statistical analyses were performed using the *t* test (two-tailed, unpaired) and  $\chi^2$  analysis. Statistical significance was set at  $P < .05$ .

## Results

As regard demographic data, these patients were 36 females (72%) and 14 males (28%) with total mean age

**Figure 3**



Preplaced sutures at cut end of CBD.

of (41.34±13.38 years) (range, 22–70 years). On all, 12% cases had diabetes mellitus (DM), 8% cases had cardiac diseases, 6% cases were hypertensive, 4% cases had hepatitis C virus (HCV), 2% cases were cirrhotic, and 2% cases were epileptics.

As regard preoperative data, 60% cases were presented as bile leak, 40% cases had jaundice and 28% cases had abdominal pain. Twelve percent cases had intraoperative bleeding, 4% cases had fever, 2% cases had cholangitis, and 2% cases had hematemesis. Open cholecystectomy was done for 58% cases while 42% cases underwent LC. Thirty-two percent cases had type E2, 26% had type A, 22% had type E1, 8% had type C, 6% had type E3, 4% had type D and 2% had type B. Out of those ten cases, three cases had ligated RHA, three cases had main portal vein injury, three cases had RHA pseudoaneurysm and one case had right portal vein injury. Concomitant vascular injury was detected in a mean duration of 8.0±7.19 days with range from 1 day to 30 days. There were four cases detected intraoperatively while six cases were detected later by computed tomography hepatic angiography.

As regard management procedures of BDI, Roux En Y HJ was the most frequent technique, that was done in 22 cases followed by ERCP and stent which was performed in 15 cases, redo hepaticojejunostomy in six cases, end to end anastomosis of BD over stent in two cases, ligation of aberrant right hepatic duct in one case, external biliary diversion in one case, CBD exploration, and T Tube drainage in one case and right hepatectomy in one case.

As regard management procedures of concomitant vascular injuries, four cases were diagnosed intraoperative while then remaining six cases were diagnosed later, repair of side wall injury of main portal vein in three cases, repair of right portal vein in one case, ligation of RHA pseudoaneurysm in two cases.

It was reported that 12 (24%) of studied cases were admitted to ICU. Hospital stay was 10.55±4.94 days with range from 3 to 30 days.

As regard short term outcome of management, chest infection was the most common complications reported in 10% cases, 6% cases had wound infection, and 4% cases had sepsis. One case had, anastomotic leak, one had bile leak, one had deep venous thrombosis (DVT), one had liver abscess, and one had wound dehiscence.

As regard long term outcome of management, anastomotic stricture was the most common complications reported in 12% cases Fig. 4, and right lobe atrophy in 4% of cases, common bile duct (CBD) stricture in 4% of cases. Two (4%) of studied patients died Table 1.

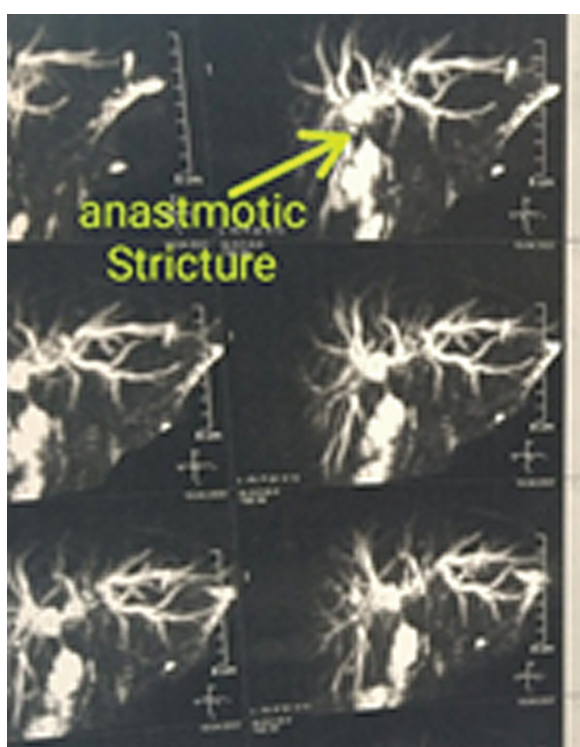
The studied cases were allocated into two groups, regarding presence of concomitant vascular injury; group A: cases did not develop concomitant vascular injury, group B: cases developed concomitant vascular injury. Vascular injury was significantly elevated in males than those without vascular injury ( $P=0.027$ ) Table 2.

**Discussion**

In our research, as regard demographic data of the studied cohort, we found that the age of patients ranged from 22 to 70 years with mean age±SD being 41.34±13.38 years. Most cases were females (72%) while there were 14 (28%) males. Regarding comorbidities, 12% cases had DM, 8% cases had cardiac diseases, 6% cases were hypertensive, 4% cases had HCV, 2% cases were cirrhotic, and 2% cases were epileptics.

Comparable with our results Hafeez Bhatti *et al.* [15], who found the median age was 39 (20–80) years with the majority of females (male:female ratio was 1:5.5).

**Figure 4**



MRCP show anastomotic stricture.

Regarding clinical presentation among the studied group, it was found that 60% cases were presented as bile leak, 40% cases had jaundice and 28% cases had abdominal pain. Twelve percent cases had intraoperative bleeding, 4% cases had fever, 2% cases has cholangitis, and 2% cases had hematemesis.

In agreement with the current study Hafeez Bhatti *et al.* [15], demonstrated that the most frequent manifestations were jaundice and abdominal pain followed by bile in drain. They also found that the presenting symptoms were non significantly associated with vascular injury.

Also, Gad *et al.* [16], found that the most common presentations were bile from drain 21 (30.4%), Jaundice 16 (23.2%), discovery during cholecystectomy 14 (20.3%), and Cholangitis 12 (17.4%). They also found that the clinical presentation was non significantly associated with early or late postoperative morbidity.

Regarding the type of cholecystectomy, we found that open cholecystectomy was done for 58% cases while 42% cases underwent LC. In line with our research Díaz-Martínez *et al.* [17], revealed that the majority of cases (62%) had open cholecystectomy, whereas 27.9% underwent LC, and only 10.1% underwent converted cholecystectomy.

This research showed that concomitant vascular injury was detected in a mean duration of 8.0±7.19 days with

**Table 1 Distribution of patients as regard short and long term outcome**

Parameters	Studied patients (n=50) N (%)
<b>Short term outcome</b>	
No	35 (70.0%)
Anastomotic leak	1 (2.0%)
Bile leak	1 (2.0%)
Chest infection	5 (10.0%)
DVT	1 (2.0%)
Liver ischemia and multiple abscesses	1 (2.0%)
Sepsis	2 (4.0%)
Wound dehiscence	1 (2.0%)
Wound infection	3 (6.0%)
<b>Long-term outcome</b>	
No	40 (80.0%)
Anastomotic stricture	6 (12.0%)
CBD stricture	2 (4.0%)
RT lobe atrophy	2 (4.0%)
Yes	2 (4.0%)
<b>Mortality</b>	
No	48 (96.0%)
Yes	2 (4.0%)

range from 1 to 30 days. Also, Díaz-Martínez *et al.* [17], showed that the bile duct was repaired after a median of 84 (0-292) days.

As well, Gad *et al.* [16], revealed that in 20.3% cases, BI was detected during cholecystectomy; however, in 44.9%, 26.1%, and 8.7%, BI was diagnosed in the early (within 7 days after cholecystectomy), intermediate (7 days–3 months), and late (beyond 3 months) postoperative periods, respectively.

In this research injury categorization for ducts Strasberg's categorization was used to classify BDI as follow: 34% cases had type A, 32% had type E2, 22% had type E1, 6% had type E3, 4% had type D, and 2% had type B.

In addition, Gad *et al.* [16], showed that according to Strasberg classification of injury there were E1 in 25 (36.2%), E2 in 32 (46.4%), E3 in 8 (11.6%), and E4 in 4 (5.8%). They also found that the Strasberg classification was non significantly associated with early or late postoperative morbidity.

In the current study there was 10 (20%) cases had concomitant vascular injury. Out of those ten cases, three cases had ligated RHA which was discovered later during repair of BDI, three cases had main portal vein artery which was discovered intraoperative, three cases had RHA pseudoaneurysm, and one case had right portal vein injury.

Comparable with our results, Gad *et al.* [16], showed that there were 10% of patients had vascular injuries. The most frequent injury was RHA ligated in 7.2%.

In the current study Roux En Y HJ was the most frequent technique, that was done in 40% cases followed by ERCP and stent, which was performed in 22% of the patients.

In addition, Mahasupachai *et al.* [18], revealed that HJ is the most frequent operation, as it was done on 90% cases. Ten percent of patients had primary T-tube repair.

Roux-en-Y HJ is the mainstay of therapy for complicated BDI.

In this research it was reported that 12 (24%) of studied patients were admitted to ICU.

However, Díaz-Martínez *et al.* [17], revealed that due to biliary peritonitis and pneumonia, only one case (1.3%) needed a hospital stay in the ICU after surgery.

The higher rate of ICU admissions in the current study may be due to the higher rate of comorbidities and complications in our sample.

Regarding short-term complications among the studied patients, it was found that chest infection was the most common complications reported in 10% cases, 6% cases had wound infection, and 4% cases had sepsis. One case had, anastomotic leak, one had bile leak, one had DVT, one had liver ischemia and multiple abscesses, and one had wound dehiscence.

However, Díaz-Martínez *et al.* [17], revealed that in short-term follow-up, cholangitis (11.4%) and bile leakage (10%) were the most prevalent problems.

**Table 2 Comparison between the two studied groups as regard short and long-term outcome**

	Group (A) No vascular injury (No.=40) No. (%)	Group (B) Vascular injury (No.=10) No. (%)	Test value	P-value
<i>Short term complications</i>				
No	26 (65.0%)	9 (90.0%)	X <sup>2</sup> =8.21	0.413
Anastomotic leak	1 (2.5%)	0		
Bile leak	1 (2.5%)	0		
Chest infection	5 (12.5%)	0		
DVT	1 (2.5%)	0		
Liver ischemia and multiple abscesses	0 (0.0%)	1 (10.0%)		
Sepsis	2 (5.0%)	0		
Wound dehiscence	1 (2.5%)	0		
Wound infection	3 (7.5%)	0		
<i>Long- term complications</i>				
No	35 (87.5%)	5 (50.0%)	X <sup>2</sup> = 13.7	0.003*
Anastomotic stricture	5 (12.5%)	2 (20.0%)		
CBD stricture	0 (0.0%)	1 (10.0%)		
Right lobe atrophy	0 (0.0%)	2 (20.0%)		

\*: significant as P value less than equal to 0.05.

Regarding long-term complications among the studied patients, it was found that long-term complications among the studied patients. Anastomotic stricture was the most common complications reported in 12% cases and 4% cases had right lobe atrophy. One case had liver ischemia and one had BD stricture. Also, Gad *et al.* [16], revealed that the late biliary was 17.4%, in the form of recurrent cholangitis 7.25%; where the initial attacks developed at 9, 10, 20, 33, and 39 months from definitive surgery, stricture 7.25%, which occurred at 20, 21, 22, 25, and 35 months from surgery, and both stricture and recurrent cholangitis 2.9%, which happened at 40 and 45 months from surgery.

Also, Hafeez Bhatti *et al.* [15], revealed that 90-day illness was 25.7% and the complications were wound infection in 17.6%, Pleural effusion in 5.2% and Sepsis in 2.6% there were only 7.6% grade III and above problems.

This research showed that hospital stay was  $10.55 \pm 4.94$  days with range from 3 to 30 days. However, Gad *et al.* [16], demonstrated that hospital stay was  $8.6 \pm 5.2$  days. While, Patrono *et al.* [19], revealed that hospital stay was 14 (10–22) days.

This research showed that the mortality rate was two (4%). Also, Stilling and colleagues, demonstrated that postoperative illness was 36% and the 30-day death was 2%. But, Hafeez Bhatti *et al.* [15], demonstrated that there were no mortalities.

Vascular injury was significantly elevated in males than those without vascular injury. This was supported by Booi *et al.* [20], who revealed that in multivariable analysis male gender was the only independent variable related with stricture formation. Contrary to our findings, Hafeez Bhatti *et al.* [15], revealed that there was no significant relationship among the BDI incidence with vascular injury and gender, presenting symptom, cholecystectomy and radiological intervention. The disagreement may be because of differences in sample size.

In this research, there was no significant variance among the studied groups as regard hospital stay and ICU admission. Also, there was no significant variance among the studied groups as regard short term complications.

Our results were supported by Sarno *et al.* [21], revealed that cases with dual vascular damage showed worse long-term results.

As well, Buell *et al.* [22], reported an elevated illness rate, and worse long-term results in cases with vascular injuries and simultaneous biliary.

Contrary to our findings, Gad *et al.* [16], showed that vascular injury was non-significantly associated with late complications. The disagreement with our results may be due to the difference in sample size and procedural details. Also, vascular injuries had no impact late biliary finding postoperatively in Walsh *et al.* [23], Sulpice *et al.* [24], Lubikowski *et al.* [25], Keleman *et al.* [26], and Pulitano *et al.* [8].

Limitations: relatively small sample size, single center research, follow-up was limited for relatively short duration.

---

## Conclusions

Concomitant vascular injury postcholecystectomy prevalence was significantly associated with long-term complications, right lobe atrophy was significantly elevated in vascular injury cases than those without vascular injury.

## Financial support and sponsorship

Nil.

## Conflicts of interest

There are no conflicts of interest.

---

## References

- 1 Pesce A, Palmucci S, La Greca G, Puleo S. Iatrogenic bile duct injury: impact and management challenges. *Clin Exp Gastroenterol* 2019; 12:121–8.
- 2 Salama IA, Shoreem HA, Saleh SM, Hegazy O, Housseini M, Abbasy M, Badra G, Ibrahim T Iatrogenic biliary injuries: multidisciplinary management in a major tertiary referral center. *HPB Surg* 2014; 2014:575136.
- 3 El-Dhuwaib Y, Slavin J, Corless DJ, Begaj I, Durkin D, Deakin M. Bile duct reconstruction following laparoscopic cholecystectomy in England. *Surg Endosc* 2016; 30:3516–25.
- 4 Adamsen S, Hansen OH, Funch-Jensen P, Schulze S, Stage JG, Wara P. Bile duct injury during laparoscopic cholecystectomy: a prospective nationwide series. *J Am Coll Surg* 1997; 184:571–8.
- 5 Lau WY, Lai EC. Classification of iatrogenic bile duct injury. *Hepatobiliary Pancreat Dis Int* 2007; 6:459–63.
- 6 Mamdouh K, Khalil A. Evaluating the outcome of direct repair of bile duct injury. *Med J Cairo Univ* 2018; 86:4379–83.
- 7 Strasberg SM, Hertl M, Soper NJ. An analysis of the problem of biliary injury during laparoscopic cholecystectomy. *J Am Coll Surg* 1995; 180:101–25.
- 8 Pulitanò C, Parks RW, Ireland H, Wigmore SJ, Garden OJ. Impact of concomitant arterial injury on the outcome of laparoscopic bile duct injury. *Am J Surg* 2011; 201:238–44.
- 9 Chiruvella A, Sarmiento JM, Sweeney JF, Lin E, Davis SS Jr. Iatrogenic combined bile duct and right hepatic artery injury during single incision laparoscopic cholecystectomy. *JLS* 2010; 14:268–7.
- 10 Terblanche J, Allison HF, Northover JM. An ischemic basis for biliary strictures. *Surgery* 1983; 94:52–7.
- 11 Jin S, Fu Q, Wuyun G, Wuyun T. Management of post-hepatectomy complications. *World J Gastroenterol* 2013; 19:7983–91.

- 12 Li J, Frilling A, Nadalin S, Paul A, Malagò M, Broelsch CE. Management of concomitant hepatic artery injury in patients with iatrogenic major bile duct injury after laparoscopic cholecystectomy. *Br J Surg* 2008; 95:460–5.
- 13 de'Angelis N, Catena F, Memeo R, Coccolini F, Martínez-Pérez A, Romeo OM, *et al.* 2020 WSES guidelines for the detection and management of bile duct injury during cholecystectomy. *World J Emerg Surg* 2021; 16:30–43
- 14 Schmidt SC, Langrehr JM, Hintze RE, Neuhaus P. Long-term results and risk factors influencing outcome of major bile duct injuries following cholecystectomy. *Br J Surg* 2005; 92:76–82.
- 15 Hafeez Bhatti AB, Dar FS, Zia H, Rafique MS, Khan NY, Salih M, Shah NH. Prognostication of learning curve on surgical management of vasculobiliary injuries after cholecystectomy. *Int J Hepatol* 2016; 2016:2647130.
- 16 Gad EH, Ayoup E, Kamel Y, Zakareya T, Abbasy M, Nada A, Housseni M, Abd-Elsamee MA-S. Surgical management of laparoscopic cholecystectomy (LC) related major bile duct injuries; predictors of short- and long-term outcomes in a tertiary Egyptian center- a retrospective cohort study. *Ann Med Surg (Lond)* 2018; 36:219–30.
- 17 Díaz-Martínez J, Chapa-Azuela O, Roldan-García JA, Flores-Rangel GA. Bile duct injuries after cholecystectomy, analysis of constant risk. *Ann Hepatobiliary Pancreat Surg* 2020; 24:150–5.
- 18 Mahasupachai S, Asavakarn S, Limsrichamrern S. Does concomitant vascular injury have an impact on the outcome after surgical repair of iatrogenic bile duct injuries. *HPB* 2021; 23:S362.
- 19 Patrono D, Benvenga R, Colli F, Baroffio P, Romagnoli R, Salizzoni M. Surgical management of post-cholecystectomy bile duct injuries: referral patterns and factors influencing early and long-term outcome. *Updates Surg* 2015; 67:283–91.
- 20 Booiy KAC, Coelen RJ, de Reuver PR, Besselink MG, van Delden OM, Rauws EA, *et al.* Long-term follow-up and risk factors for strictures after hepaticojejunostomy for bile duct injury: An analysis of surgical and percutaneous treatment in a tertiary center. *Surgery* 2018; 163:1121–7.
- 21 Sarno G, Al-Sarira AA, Ghaneh P, Fenwick SW, Malik HZ, Poston GJ. Cholecystectomy-related bile duct and vasculobiliary injuries. *Br J Surg* 2012; 99:1129–36.
- 22 Buell JF, Cronin DC, Funaki B, Koffron A, Yoshida A, Lo A, *et al.* Devastating and fatal complications associated with combined vascular and bile duct injuries during cholecystectomy. *Arch Surg* 2002; 137:703–8. discussion 8–10
- 23 Walsh RM, Henderson JM, Vogt DP, Brown N. Long-term outcome of biliary reconstruction for bile duct injuries from laparoscopic cholecystectomies. *Surgery* 2007; 142:450–6. discussion 6–7
- 24 Sulpice L, Garnier S, Rayar M, Meunier B, Boudjema K. Biliary cirrhosis and sepsis are two risk factors of failure after surgical repair of major bile duct injury post-laparoscopic cholecystectomy. *Langenbecks Arch Surg* 2014; 399:601–8.
- 25 Lubikowski J, Post M, Biątek A, Kordowski J, Milkiewicz P, Wójcicki M. Surgical management and outcome of bile duct injuries following cholecystectomy: a single-center experience. *Langenbecks Arch Surg* 2011; 396:699–707.
- 26 Keleman AM, Imagawa DK, Findeiss L, Hanna MH, Tan VH, Katz MH, *et al.* Associated vascular injury in patients with bile duct injury during cholecystectomy. *Am Surg* 2011; 77:1330–3.