

Evaluation of sartorius muscle flap versus tensor fascia lata to cover exposed groin vascular grafts: which is better?

Ayman M. Abdelmofeed^a, El-Sayed A. Abd El-Mabood^b, Refaat S. Salama^c

Departments of ^aGeneral and Plastic Surgery, ^bGeneral and Vascular Surgery, ^cGeneral Surgery, Benha University, Benha, Egypt

Correspondence to Ayman M. Abdelmofeed, MD, Department of General and Plastic Surgery, Benha University, Benha University Hospital, 1 Farid Nada Street, Benha, 13516, Egypt. Mob: 01006795649, 01156196042; e-mail: aymanabdelmofeed@yahoo.com

Received: 3 April 2020

Revised: 18 April 2020

Accepted: 10 May 2020

Published: 24 December 2020

The Egyptian Journal of Surgery 2020, 39:837–843

Purpose

To focus on the importance of tensor fascia lata or sartorius muscle flaps to improve wound healing and to save exposed groin vascular grafts with minimal complications and to evaluate which is better.

Background

Treatment of an exposed groin vascular grafts after vascular interventions may be challenging. Saving these grafts saves a patient's limb.

Patients and methods

A prospective, randomized clinical trial was conducted on 54 patients suffering from exposed groin vascular grafts to compare postoperative outcomes using tensor fascia lata flap [group A; 28 (51.8%) cases] versus sartorius muscle flap [group B; 26 (48.2%) cases]. Postoperative follow-up was for 6 months.

Results

No flap loss was recorded in any of the procedure. Minor complications, such as skin graft was lost partially, were seen in group A in five (17.9%) cases at the donor area, but partial loss of skin graft was noticed only in one (3.8%) case in group B ($P=0.0022$). Small hematoma was noticed in six (21.4%) cases in group A but only in two (7.6%) cases in group B ($P=0.0036$). Finally, overall wound healing was noticed in 22 (78.6%) cases in group A and 24 (92.3%) cases in group B ($P=0.014$).

Conclusion

Both tensor fascia lata and sartorius muscle flaps for exposed groin vascular grafts are considered a protective weapon to save these exposed grafts and to help to ensure good wound healing. Sartorius muscle flaps are easily rotated from the same incision, are more effective, and are safe, with minimal postoperative complications.

Keywords:

exposed vascular grafts, outcomes, sartorius muscle flap, tensor fascia lata

Egyptian J Surgery 39:837–843

© 2020 The Egyptian Journal of Surgery

1110-1121

Introduction

Vascular graft exposure after vascular bypass surgery is a still significant cause of limb loss and morbidity after using artificial vascular grafts in peripheral revascularization surgery owing to superficial position of the graft, especially in thin patients [1].

The groin region is a common site of vascular bypass repair for lower limb ischemia, and this region has many predisposing mechanisms of infections near the applied artificial grafts: lymphatic disruption with lymphorrhea, skin maceration due to proximity to perineum and/or devitalized fat due to arterial compromise, and/or difficulty care of the wound in the area [2,3].

Graft exposure that may result from wound infection increases the risk of graft removal/disruption, which could result in major amputation or death. Graft infections proximally increase the risk of mortality but distally are more likely to increase rates of amputation. The graft survival and limb survival

depend on the depth of the wound infection and graft itself involvement [4–6].

Early cover reduces greatly the incidence of complications. Several attempts were made to decrease the morbidity resulting from groin wound complications by applying adequately vascularized flaps to close dead space, enhancing healing [7–9].

There are many advantages of flap coverage; it decreases the formation of seroma by closing the dead space in the groin. Furthermore, it allows well-vascularized tissue for optimum wound healing. Moreover, it helps tensionless wound, so hospital stay is short [10–12].

This is an open access journal, and articles are distributed under the terms of the Creative Commons Attribution-NonCommercial-ShareAlike 4.0 License, which allows others to remix, tweak, and build upon the work non-commercially, as long as appropriate credit is given and the new creations are licensed under the identical terms.

The closure of groin wounds after vascular bypass presents a great challenge. The gold standard management for such defects are massive debridement, an extra-anatomic revascularization, and/or graft removal. Good debridement, adequate local care and support, and flap transposition can improve adequately the outcomes [13,14].

The common flaps used to cover groin area after vascular intervention include gracilis and sartorius muscle flaps, tensor fascia lata, rectus abdominis, and femoris flaps. These flaps have different rates of success for treating exposed groin vascular grafts. Moreover, it provides better coverage for groin defects, as they are resistant to infection [15].

Vascular anatomy

Tensor fasciae latae muscle originates from outer lip of the iliac crest and is covered by two layers of fasciae that fuse at the point between upper third and lower two thirds of thigh and continue as iliotibial tract to be inserted into lateral condyle of femur. Tensor fascia lata flap is supplied by the lateral femoral circumflex artery and in some patients by ascending branch directly from profunda femoris artery. The vascular pedicle pierces muscle (6–8 cm) below the origin of the muscle. Skin overlying the muscle is supplied by four or five perforators originating from the pedicle [16–18].

However, sartorius muscle arises from anterior superior iliac spine by tendinous fibers and inserted by aponeurosis into upper part of the tibia. Sartorius has multiple arterial supply from SFA, lateral circumflex femoral, and popliteal arteries through its geniculate branches. These segmental branches enter the posteromedial aspect of the muscle [19,20].

Patients and methods

After local ethical committee of Benha University and Benha Insurance approval and obtaining written fully informed patients consent, this study included 54 patients suffering from exposed groin vascular grafts in the form of discharging sinuses or frank exposure owing to wound dehiscence who were fit for surgery from Benha University and Benha Insurance hospitals during the period between August 2016 to March 2020, so as to allow 6-month follow-up period for the last case operated on. All patients presenting were admitted at General Surgery ward for clinical evaluation, laboratory assessment, and under full observations by a vascular surgeon for vascular outcome and complications and a plastic reconstructive surgeon for flap monitoring and outcomes.

This study is a prospective, randomized clinical trial. Patients were randomly allocated by using simple random allocation cards method into two groups: the use of tensor fascia lata flap [group A; 28 (51.8%)] versus sartorius muscle flap [group B; 26 (48.2%) cases].

The aim of the study was to focus on the importance of tensor fascia lata or sartorius muscle flaps to improve wound healing and to save exposed groin vascular grafts with minimal complications and to compare their outcomes.

Patients included in this study had groin wound defect with exposed vascular graft after vascular operations. All were fit for surgery with good general condition. However, patients were excluded from this study who were suffering from diabetes mellitus, hypercoagulation disorders, those maintained on immunosuppressive therapy or corticosteroids, traumatic crushed sartorius or tensor fascia lata muscles, or previous muscle harvesting.

Operative procedures

Swab culture of wound was taken in all patients, and any infection was treated first and then flap coverage was applied.

Harvesting techniques

The preoperative localization and markings of the muscle to be harvested was done, followed by general or spinal anesthesia.

Group A: the tensor fascia lata muscle flap harvesting (Figs 1 and 2).

The tensor fasciae lata flap could be muscular or musculocutaneous. In this study, harvesting of musculocutaneous flap was as follows: three bony prominences were palpated and marked: iliac crest, anterior superior iliac spine, and lateral femoral condyle. A line was drawn from iliac crest to lateral condyle of femur to map musculofascial tract. Moreover, muscle belly was mapped and then an island of skin centered along the muscle belly was identified.

Two points, 8 and 10 cm below iliac crest and at anterior border of the muscle, were mapped (entry points of vascular pedicle and lateral femoral cutaneous nerve). Anterior margin of skin flap was first incised, and then the incision was extended in a lazy-S fashion above and below. After identifying and dissecting anterior margin of tensor fasciae latae

Figure 1

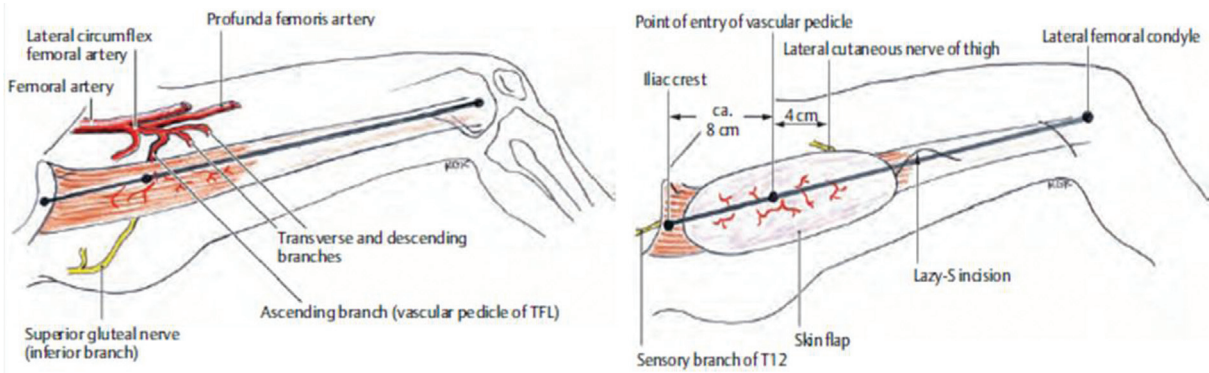


Diagram for blood supply and harvest of tensor fascia lata flap

Diagram for blood supply and harvest of tensor fascia lata flap.

Figure 2

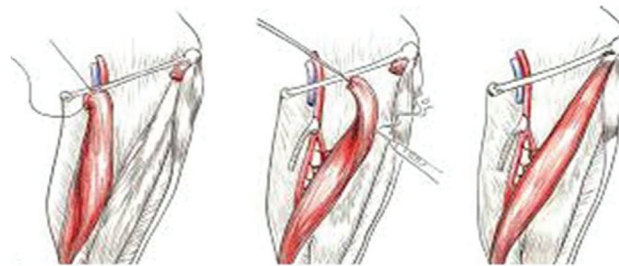


Diagram of Sartorius harvest

Steps of tensor fascia lata muscle flap harvesting.

muscle, it was retracted laterally and backwards to expose entry point of vascular pedicle.

These vessels pass in the space between rectus femoris and vastus lateralis. So rectus femoris was dissected bluntly from septal space and retracted anteromedially to visualize vascular pedicle, and then posterior incisions of skin island were completed, taking care to preserve the cutaneous nerve. Iliotibial tract was dissected and transected as distally as needed. The flap was rotated anteromedially and upward to cover groin wound and donor site was closed primarily over closed suction drain or skin grafted if wide.

Group B: the sartorius muscle flap harvesting (Figs 3, 4).

Sartorius was dissected along its lateral border as its blood supply comes segmentally along its medial border from five to eleven vascular pedicles from SFA, with uppermost one about 6.5 cm below anterior superior iliac spine. Then muscle flap was

transected close to anterior superior iliac spine and rotated medially to cover exposed graft. Then tendinous part of muscle was sutured to inguinal ligament. Then some sutures were done to fix rotated muscle to adjacent tissue. Suction drain was put in original site of sartorius and then direct closure was done or skin graft used if wide.

Outcome items

Drain was removed when less than 30 ml/day, and flap was checked at the third postoperative day for infection or necrosis, and the patient was followed up as inpatient for 1 week and outpatient monthly for 6 months to assess functional outcome, that is, any disability.

Statistical analysis

Study data were tabulated and analyzed using SPSS, version 16 software (SPSS Inc., Chicago, Illinois, USA). Categorical data were presented as number and percentages, using Fisher's exact test. Continuous data were expressed as mean±SD.

Figure 3

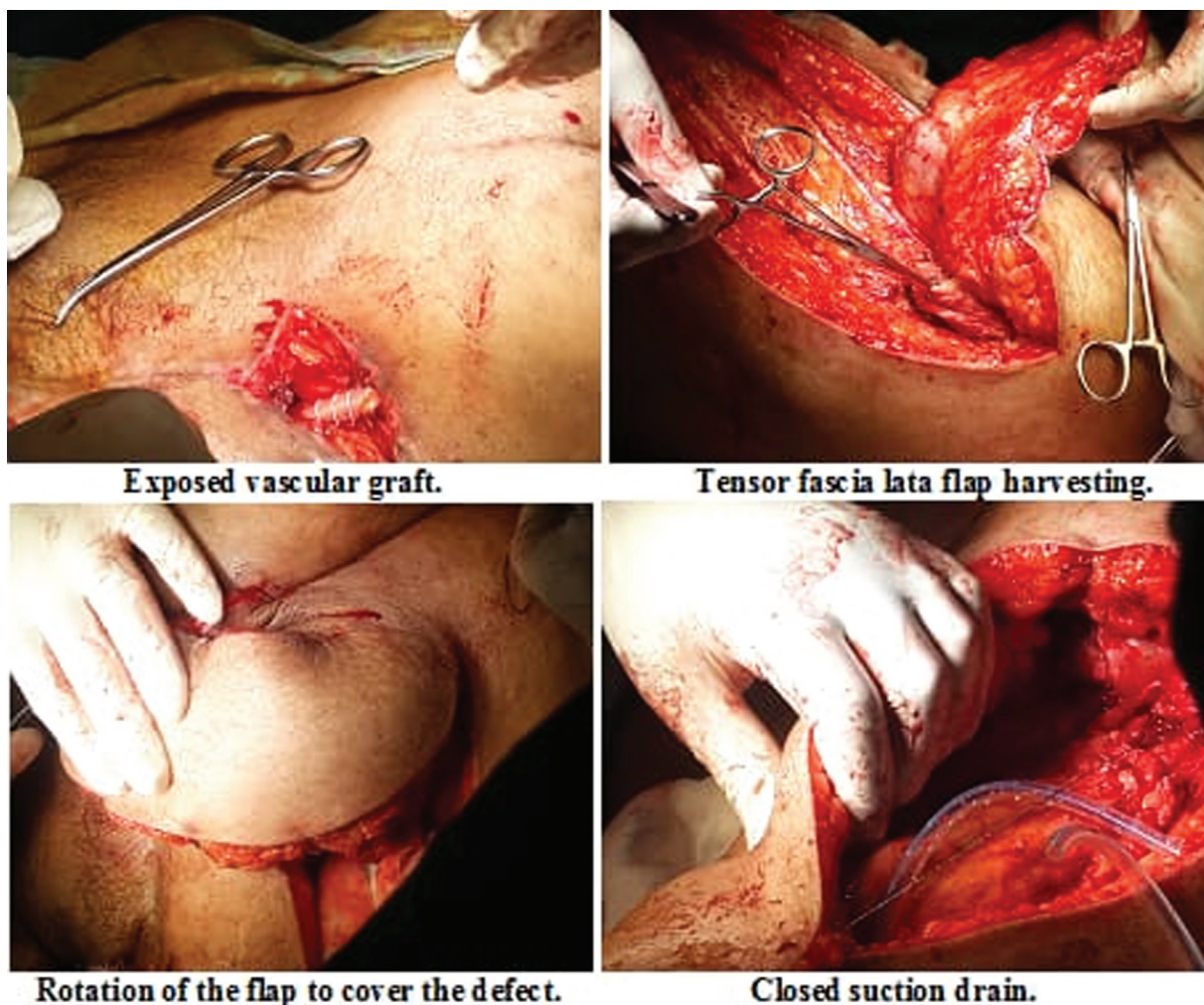


Diagram of sartorius harvest.

Quantitative data were presented as mean and SD and were analyzed by using one way unpaired *t*-test was used to compare quantitative variables, in parametric data ($SD < 50\%$ mean). *P* value less than 0.05 was considered significant.

These all data are shown in the following pictures.

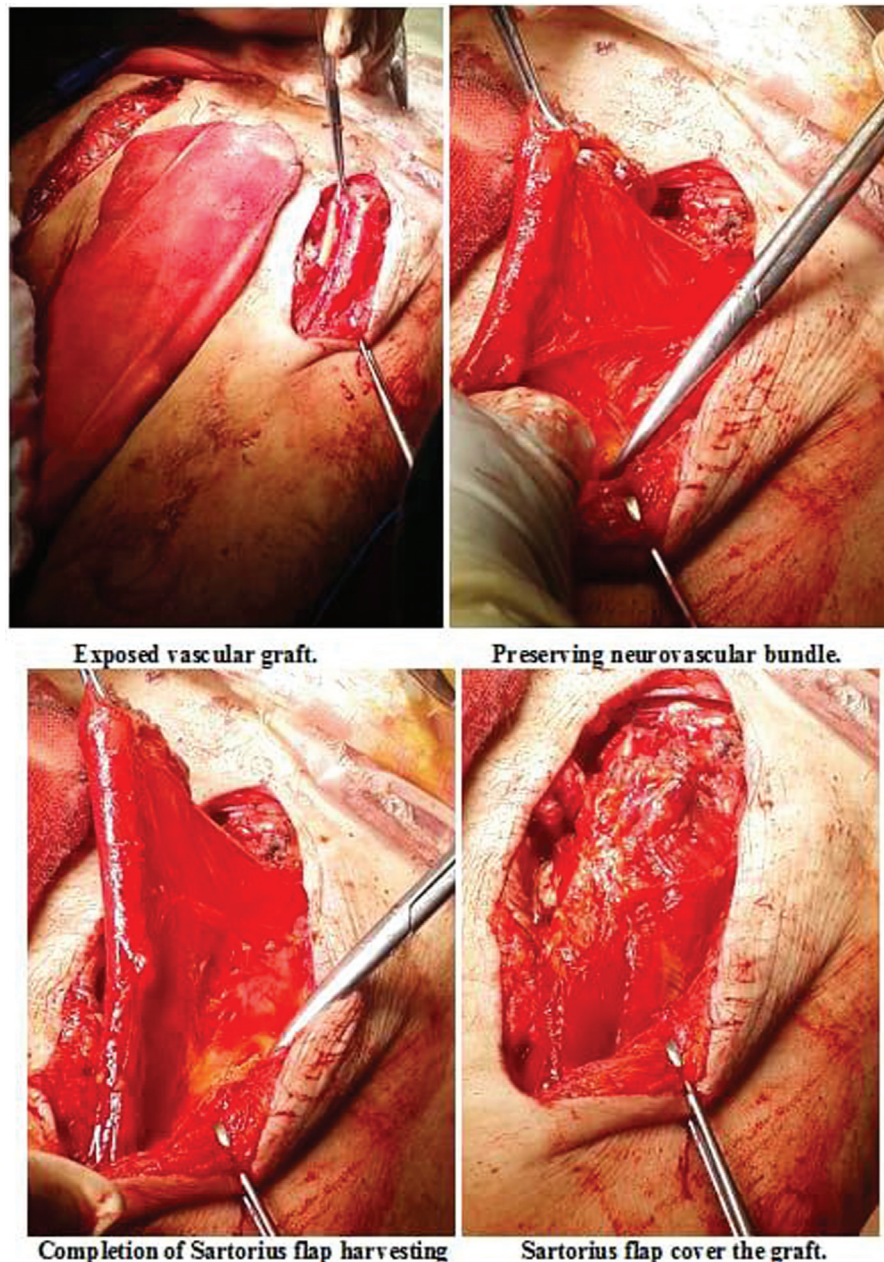
Results

A prospective, randomized trial was performed to compare postoperative outcomes using tensor fascia lata flap [group A; 28 (51.8%) cases] versus sartorius muscle flap [group B; 26 (48.2%) cases] to cover exposed groin vascular grafts. There were 19 (35.2%) female and 35 (64.8%) male patients. Patients included in this study were suffering from exposed vascular graft after vascular operation; the types of grafts used were femoral-popliteal [seven saphenous and 16 synthetic (six ringed and 10 nonringed PTFE grafts (JOTEC GmbH, Hechingen, Germany)], aortobifemoral

[synthetic: knitted polyester (Dacron) collagen coated grafts (FlowNit Bioseal, JOTEC GmbH)], femorofemoral crossover bypass [synthetic: ringed PTFE grafts (JOTEC GmbH)], axillofemoral bypass [synthetic: ringed PTFE grafts (JOTEC GmbH)], dialysis graft [three saphenous, 10 synthetic: nonringed PTFE grafts (JOTEC GmbH)], and femoral endarterectomy with patch (seven saphenous patch). None of the patients were lost to follow-up, and data collection was complete. There was no statistical difference between both groups (Table 1).

No intraoperative complications or mortality was recorded. All patients had debridement to prepare the wound for coverage and then the flap was applied, with mean operative time of 63.8 ± 4 min, range: 50–81 min, in group A, and 46.1 ± 3 min, range: 33–59 min, in group B. Mean intraoperative blood loss was 156 ± 5.5 ml, range: 150–160 ml, in group A and 147.2 ± 5.1 ml, range: 140–150 ml, in

Figure 4



Steps of sartorius muscle flap harvesting.

group B. Patients in group A were discharged 1–4 days postoperatively, but in group B were discharged 1–2 days postoperatively (Table 2).

Regarding postoperative outcomes, no flap loss was recorded in any of the procedure. Minor complication such as partial loss of skin graft was noticed in group A in five (17.9%) cases at the donor area. These cases were treated conservatively and healed by secondary intension, except 2/5 (40%) cases, which needed thiersch graft at the defect area. However, partial loss of skin graft was noticed only in one (3.8%) case in group B, which was treated conservatively.

Moreover, small hematoma was noticed in group A in six (21.4%) cases but only in two (7.6%) cases was noticed in group B. All these cases were treated conservatively and ended with good results. Infection was encountered in four (14.3%) cases in group A and one (3.8%) case in group B. The infection was controlled by appropriate antibiotics according to culture and sensitivity. Finally, overall wound healing was noticed in 22 (78.6%) cases in group A and 24 (92.3%) cases in group B, and regarding functional outcome, no any disability was recorded, with complete functions of the lower limb (Table 3).

Table 1 Demographic data of the cases

Variables	Group A [n (%)]	Group B [n (%)]	P value
Age (years)			
Between 41 and 60 years	12 (22.2)	12 (22.2)	0.47 (NS)
Older than 60 years	16 (29.7)	14 (25.9)	
Mean±SD	59.0±11.9	57.2±12.7	
Sex			
Female	10 (18.5)	9 (16.7)	0.26 (NS)
Male	18 (33.3)	17 (31.5)	
Indications			
Femoral-popliteal bypass	12 (22.2)	11 (20.4)	0.39 (NS)
Aortobifemoral bypass	3 (5.6)	3 (5.6)	
Femorofemoral crossover bypass	2 (3.6)	1 (1.9)	
Axillofemoral bypass	1 (1.9)	1 (1.9)	
Dialysis graft	7 (12.8)	6 (11.1)	
Femoral endarterectomy with patch	3 (5.6)	4 (7.4)	

Table 2 Operative and immediate postoperative data

Variables	Group A [N=28 (51.8%)]	Group B [N=26 (48.2%)]	t	P value
Operative time (min)				
Mean±SD	63.8±4	46.1±3	3.9	0.000 (HS)
Range	50–81	33–59		
Intraoperative blood loss (ml)				
Mean±SD	156±5.5	147.2±5.1	7.4	0.001 (HS)
Range	150–160	140–150		
Duration of postoperative hospital stay (days)				
Mean±SD	1.8±0.5	1.2±0.4	4.6	0.001 (HS)
Range	1-4	1-2		

HS, highly significant. Statistically significant difference by using unpaired *t*-test.

Table 3 Postoperative outcomes

	Group A [N=28 (51.8%)] [n (%)]	Group B [N=26 (48.2%)] [n (%)]	P value
Partial loss of skin graft	5 (17.9)	1 (3.8)	0.0022
Hematoma	6 (21.4)	2 (7.6)	0.0036
Infection	4 (14.3)	1 (3.8)	0.0028
Wound healing after 2 weeks	22 (78.6)	24 (92.3)	0.014
Vascular graft salvage	26 (92.9)	25 (96.2)	0.49

Discussion

Treatment for exposed grafts was complete removal and extensive debridement and then extra-anatomical revascularization whenever possible. However, these techniques increase the risk of limb loss and mortality. Calligaro *et al.* [21] reported that coverage using muscle flaps resulted in better wound healing and decreased morbidity, including superinfection, disrupted anastomosis, and thrombosis.

In the past, the management of infected vascular grafts was total removal of it with adequate debridement and extra-anatomical bypass. Major amputation and death

rates were observed in 10–79% and 9–58%, respectively [22]. Rapid antibiotics and debridement and flap coverage of femoral vessels can save graft [4,12]. In 2008, Kotb [23] recommended the early local muscular flap reconstruction for successful salvage of exposed infra-inguinal vascular bypass grafts.

In the current study, patients comprised 19 (35.2%) female and 35 (64.8%) male patients, and 30 patients were above 60 years old. These results were comparable to the results reported by Landry *et al.* [12], who mentioned mean age of the patients was 67.0±11.9 years, and sex distribution was (male/female) 50/50. Moreover, these results were near similar to the results described by May *et al.* [5], where most of the patients were above 60 years old.

Patients included in this study were suffering from exposed vascular graft after vascular operation; 23 (42.6%) patients was femoral-popliteal bypass. These results were comparable to the results reported by Landry *et al.* [12], who reported first operations of endarterectomy in eight cases, aortofemoral bypass in six cases, femoral-distal bypass in three cases, and axillofemoral bypass in four cases.

By reviewing operative data, mean operative time was 63.8±4 min, range: 50–81 min in group A and 46.1±3 min, range: 33–59 min, in group B. Mean intraoperative blood loss was 156±5.5 ml, range: 150–160 ml in group A, and 147.2±5.1 ml, range: 140–150 ml in group B, that is, negligible operative time and blood loss. This agrees with Gravvanis *et al.* [9], who stated a negligible and insignificant operative time. Patients in group A were discharged 1–4 days postoperatively, but in group B were discharged 1–2 days postoperatively. This is in contrast to Gravvanis *et al.* [9] and Fischer *et al.* [2], who reported 8 and 13.3 days, respectively.

Regarding postoperative outcomes, no flap loss was recorded in any of the procedure. The type of muscle flap plays a great role in graft salvage rate. In the present study, postoperative complications were less in sartorius flap group in addition to better overall wound healing. This is similar to the study done by Fischer *et al.* [4] on 244 patients undergoing muscle flap, which concluded that sartorius flaps are better to prevent limb loss.

Medial dissection of sartorius muscle should be avoided as it has a high risk of impairing viability because arterial supply enters its posteromedial aspect [24].

Conclusion

Both tensor fascia lata and sartorius muscle flaps for exposed groin vascular grafts are considered a protective weapon to save these exposed grafts and help to ensure good wound healing. Sartorius muscle flaps are easily rotated from the same incision, have more effective better blood supply, so more resistance to infection, safe on the donor site, less operative time, less blood loss, and minimal postoperative complications.

Financial support and sponsorship

Nil.

Conflicts of interest

There are no conflicts of interest.

References

1 Hasse B, Husmann L, Zinkernagel A. Vascular graft infections. *Swiss Med Wkly* 2013; 143:w13754.

- 2 Fischer JP, Nelson JA, Wang GJ, Foley PJ, Wu LC, Rohrbach JI. Prophylactic muscle flaps in vascular surgery: the Penn Groin Assessment Scale. *Plast Reconstr Surg* 2012; 129:940e–949e.
- 3 Nelson JA, Fischer JP, Wink JD, Wingate NA, Woo EY, Shang EK. Predicting the need for muscle flap salvage after open groin vascular procedures: a clinical assessment tool. *J Plast Surg Hand Surg* 2014; 48:389–395.
- 4 Fischer JP, Mirzabeigi MN, Sieber BA. Outcome analysis of 244 consecutive flaps for managing complex groin wounds. *J Plast Reconstr Aesthet Surg* 2013; 66:1396–1404.
- 5 May BL, Zelenski NA, Daluvoy S, V Blanton MW, Shortell CK, Erdmann DG. Salvage of exposed groin vascular grafts with early intervention using local muscle flaps. *Plast Reconstr Surg Glob Open* 2015; 3:e514.
- 6 Alkon JD, Smith AO, Losee JE. Management of complex groin wounds: preferred use of rectus femoris muscle flap. *Plast Reconstr Surg* 2005; 115:776–783.
- 7 Illig KA, Alkon JE, Smith AL. Rotational muscle flap closure for acute groin wound infections following vascular surgery. *Ann Vasc Surg* 2004; 18:661–668.
- 8 Colwell AS, Donaldson MC, Belkin MH, Orgill DP. Management of early groin vascular bypass graft infections with sartorius and rectus femoris flaps. *Ann Plast Surg* 2004; 52:49–53.
- 9 Gravvanis A, Caulfield R, Mathur B, Ramakrishnan V. Management of inguinal lymphadenopathy immediate sartorius transposition and reconstruction of recurrence with pedicled ALT Flap. *Ann Plast Surg* 2009; 63:307–310.
- 10 Wu LC, Djohan RS, Liu TS, Chao AH, Lohman RF, Song DH. Proximal vascular pedicle preservation for sartorius muscle flap transposition. *Plast Reconstr Surg* 2006; 117:253–258.
- 11 Morasch MD, Sam AD, Kibbe MR. Early results with use of gracilis muscle flap coverage of infected groin wounds after vascular surgery. *J Vasc Surg* 2004; 39:1277–1283.
- 12 Landry GJ, Carlson JR, Liem TK, Mitchell EL, Edwards JM, Moneta GL. The sartorius muscle flap: an important adjunct for complicated femoral wounds involving vascular grafts. *Amer J Surg* 2009; 197:655–659.
- 13 Agarwal A, Gupta S, Bhattacharya N. Tensor fascia lata flap reconstruction in groin malignancy. *Singapore Med J* 2009; 50:781–784.
- 14 Evriviades D, Raurell A, Perks A. Pedicled anterolateral thigh flap for reconstruction after radical groin dissection. *Urology* 2007; 70:996–999.
- 15 Shih P, Cheng H, Wu C, Chang S, Chen H. Management of infected groin wounds after vascular surgery. *Surg Infect* 2013; 14:3.
- 16 Ammar AD, Turrentine MW. Exposed synthetic vascular grafts of the groin: graft preservation by means of the tensor fascia latae flap. *J Vasc Surg* 1989; 10:202–204.
- 17 Deiler S, Pfadenhauer A, Widmann J, Stutzle H, Kanz K, Stock W. Tensor fasciae latae perforator flap for reconstruction of composite Achilles tendon defects with skin and vascularized fascia. *Plast Reconstr Surg* 2000; 106:342–349.
- 18 Krishnan KG, Winkler PA, Müller AL, Grevers GK, Steiger HJ. Closure of recurrent frontal skull base defects with vascularized flaps—a technical case report. *Acta Neurochir (Wien)* 2000; 142:1353–1358.
- 19 Petrsek PF, Kalman PG, Martin RD. Sartorius myoplasty for deep groin wounds following vascular reconstruction. *Am J Surg* 1990; 160:175–178.
- 20 Mendez Fernandes MA, Quast DC, Geis RC, Henly WS. Distally based sartorius flap in the treatment of infected femoral arterial prostheses. *J Cardiovasc Surg (Torino)* 1980; 21:628–631.
- 21 Calligaro KD, Veith FJ, Sales CM. Comparison of muscle flaps and delayed secondary intention wound healing for infected lower extremity arterial grafts. *Ann Vasc Surg* 1994; 8:31–37.
- 22 Ryu DY, Jung HJ, Ramaiah VG, Rodriguez-Lopez JA, Lee SS. Infected groin (graft/patch): managed with sartorius muscle flap. *Vasc Specialist Int* 2016; 32:11–16.
- 23 Kotb H. Lower extremity vascular prosthesis infection – successful salvage with local muscular flap reconstruction. *Bull Alex Fac Med* 2008; 44:173–178.
- 24 Khalil I, Sudarsky L. Sartorius muscle ‘twist’ rotation flap: an answer to flap necrosis. *J Vasc Surg* 1989; 6:93–94.