

Feasibility of gluteus maximus myocutaneous pedicled flap for presacral pressure sore reconstruction: a simple approach

Ayman M. Abdelmofeed, Mohamed F. Abdelhalim

Department of General Surgery, Benha University Hospital, Benha, Egypt

Correspondence to Ayman M. Abdelmofeed, MD, Department of General Surgery, Benha University Hospital, 1 Farid Nada Street, Benha, 13511, Egypt. Tel: 01061627850; fax: 0133231012; e-mail: aymanabdelmofeed@yahoo.com

Received: 26 January 2020

Revised: 16 February 2020

Accepted: 22 February 2020

Published: 28 August 2020

The Egyptian Journal of Surgery 2020, 39:613–621

Background

Pressure sore, bed sores, and decubitus ulcer have the same meaning and are used to describe ischemic tissue loss resulting from prolonged pressure over bony prominence. They can develop anywhere in the body, but often are located in the trochanteric, ischial, heel, and sacral areas. Although tissue destruction can occur over areas like the scalp, shoulders, calves, and heels when a patient is lying down, ischial sores occur in wheelchair-bound patients who are sitting, making 'pressure sore' the better term.

Objectives

The purpose of the study is to describe our experience in the management of sacral pressure sore with a gluteus maximus myocutaneous flap, its feasibility and outcome.

Patients and methods

Our prospective study has been conducted in the Surgery Department of Benha University Hospital from February 2017 to February 2019 on 20 patients treated with a unilateral gluteus maximus myocutaneous flap to reconstruct the presacral defect due to pressure sore and all patients have signed informed consents before they have been involved in this study.

Results

Gluteus maximus flap in presacral pressure sores is a highly feasible and effective method for the treatment of presacral pressure ulcer defect. It has been associated with short operative time (average 45 min) and small amounts of intraoperative blood loss (average 338 ml), three cases out of 20 showed postoperative hematoma, two cases developed wound dehiscence, two cases developed infection, one case developed partial flap necrosis, four cases developed pigmentation, two cases developed keloid, and only one case developed postoperative recurrence.

Conclusion

The gluteus maximus myocutaneous flap is a useful, safe, and versatile flap for the repair of presacral decubitus ulcer by a simple approach. It may be recommended as the procedure of choice for surgical treatment of this type of wound.

Keywords:

bed sores, decubitus ulcer, gluteus maximus, muscle flap, pressure sore

Egyptian J Surgery 39:613–621
© 2020 The Egyptian Journal of Surgery
1110-1121

Introduction

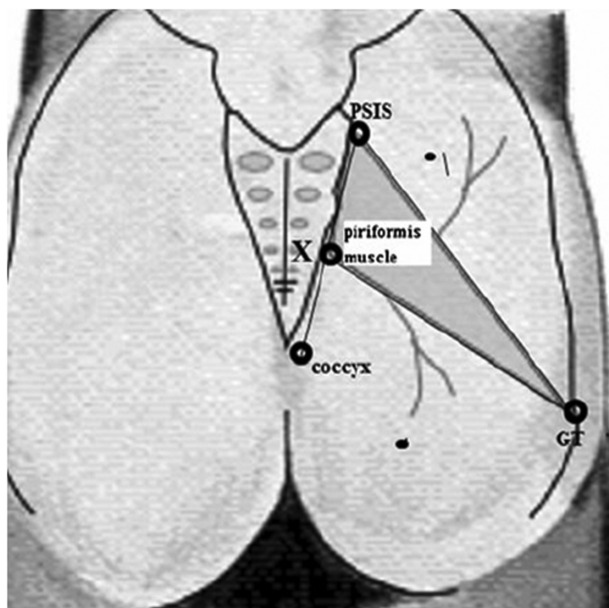
Pressure sore, bed sores, and decubitus ulcer have the same meaning used to describe ischemic tissue loss resulting from prolonged pressure over bony prominence. They can develop anywhere in the body, but are often located in the trochanteric, ischial, heel, and sacral areas. The term decubitus ulcers is derived from Latin decumbere to mean 'lie down' occurs over areas that have underlying bony prominences when the patient is recumbent, for example, the sacrum, trochanter, heel, and the occiput. Terms such as bedsore or decubitus ulcer should be avoided as they suggest all the sores are a result of supine positioning. Although tissue destruction can occur over areas like the sacrum, scalp, shoulders, calves, and the heels when a patient is lying down, ischial sores occur in wheelchair-bound

patients who are sitting, making 'pressure sore' the better term [1].

Gluteal region is mainly supplied by superior and inferior gluteal arteries which are branches of internal iliac artery (Fig. 1). Gluteal perforator flaps are designed based on the perforators in the above two arteries. The National Pressure Sore Advisory Conference classified pressure sores into four stages from stage 1 to stage 4 [2].

This is an open access journal, and articles are distributed under the terms of the Creative Commons Attribution-NonCommercial-ShareAlike 4.0 License, which allows others to remix, tweak, and build upon the work non-commercially, as long as appropriate credit is given and the new creations are licensed under the identical terms.

Figure 1



The site of vessels can be identified: (a) the inferior gluteal artery is located at the intersection of the lower and mid 1/3 parts of the line drawn from the posterior superior iliac spine (p) to the ischial tuberosity. Perforators of inferior gluteal artery lies on the inferior of the piriformis muscle, indicated by thick dotted lines. (b) Superior gluteal artery is located at the intersection of the lateral and mid-third of the line drawn from the posterior superior iliac spine (p) to the great trochanter. Perforators lie above the piriformis muscle [13].

Stage 1 pressure ulcer refers to nonblanchable erythema of intact skin, while stage 2 implies partial thickness skin loss with exposed dermis. Stage 3 refers to full thickness skin loss while stage 4 implies full thickness skin and tissue loss [3].

Pressure sores are caused mainly by external unrelieved pressure which exceeds the capillary pressure leading to ischemic necrosis. Other factors that may cause bed sores include shearing which causes tearing of blood vessels, friction which may breach the epidermis, moisture which causes maceration of the skin, and neurological conditions [4].

In general, optimum management of bed sores begins with prevention by optimizing nutritional status, eradication of infection, relieving pressure, and minimizing other contributing factors. Pressure sores stage 1 and stage 2 can be treated conservatively by using optimal nonsurgical ulcer treatment and by eliminating the local and general conditions that interfere with healing, while pressure sore stage 3 and stage 4 usually require surgical intervention [5].

Nonsurgical management can be rendered by enzymatic debridement using urea and collagenase among other enzymes over the wound [6].

In addition, adjuvant treatments for pressure ulcers play an important role including the use of newer methods to improve wound healing, for example vacuum therapy, hyperbaric oxygen, lasers, ultrasound, and electrotherapy [7].

While surgical management of bed sores includes debridement including chemical debridement, for example Dakin solution and mechanical debridement using dressing changes along with wound cleansing and surgical debridement by excision of ulcer, underlying bursa, and calcifications [8].

It also includes different surgical flaps, for example, musculocutaneous flaps, for example gluteus maximus myocutaneous flaps which has also many advantages as they can be revised or readvanced if recurrence occurs and that sutures do not lie on the pressure zone and those flaps can fill in undermined ulcers with skin removal [9].

Fasciocutaneous flap has also many advantages as it conserves normal anatomy of the area of bed sore postoperatively. It also reduces donor site morbidity, minimal blood loss, decreased postoperative pain, shorter hospital stays, and reduced costs with preservation of muscle function [10].

The purpose of this study is to describe our experience in the management of presacral pressure sore with gluteus maximus myocutaneous flap, its feasibility and outcome.

Patients and methods

Our prospective study was conducted in the Surgery Department of Benha University Hospital from January 2017 to January 2019 on 20 patients after an approval from the research ethics committee in Benha Faculty of Medicine and all patients have signed informed consents that they have been involved in this study. All the patients met our inclusion criteria including clean sacral pressure sore or dirty sore after a period of debridement medically or surgically, audible superior and inferior gluteal arteries by Doppler, no ischemic manifestations, ulcer away from the anus in fecal incontinence or colostomy will be done before, good general condition to withstand anesthesia and healing process, and no osteomyelitis visible on radiograph.

Technique of gluteus maximus myocutaneous flap

- (1) The skin territory of gluteus maximus measuring about 24×24 cm and includes the skin overlying the

Figure 2

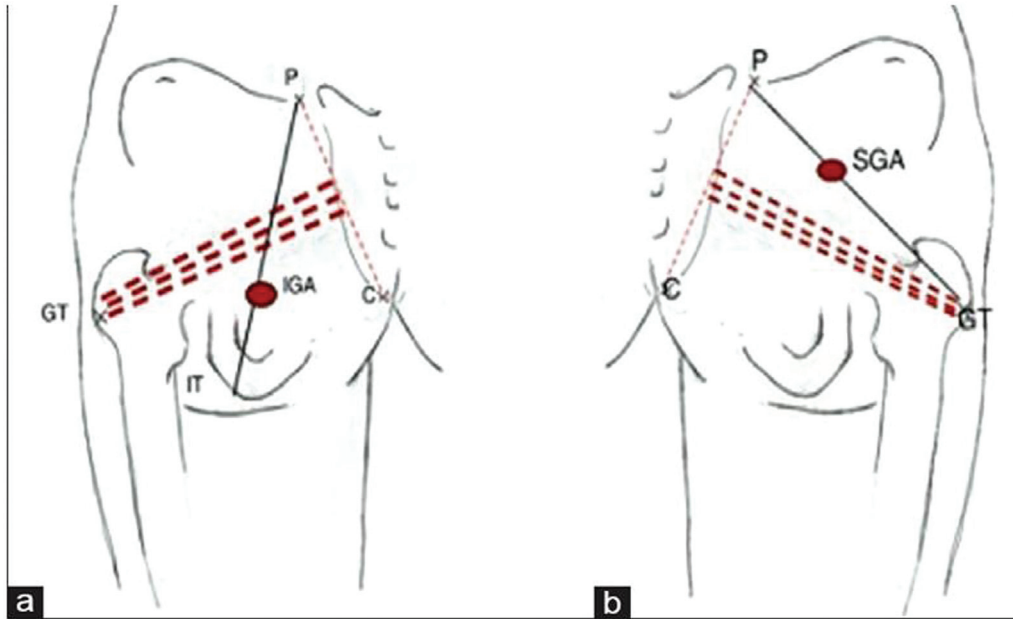
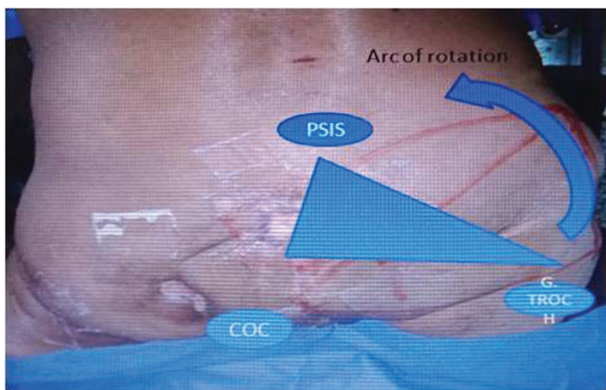


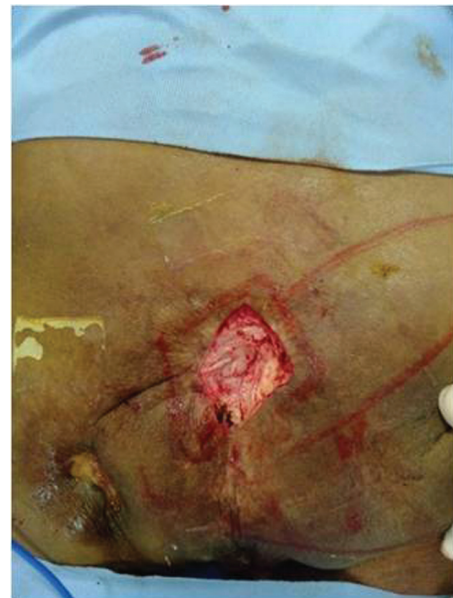Diagram of the piriformis muscle's surface marking. GT, greater trochanter; PSIS, posterior superior iliac spine, X point midway between the coccyx and PSIS.

Figure 3



Landmarks for skin incision.

Figure 4



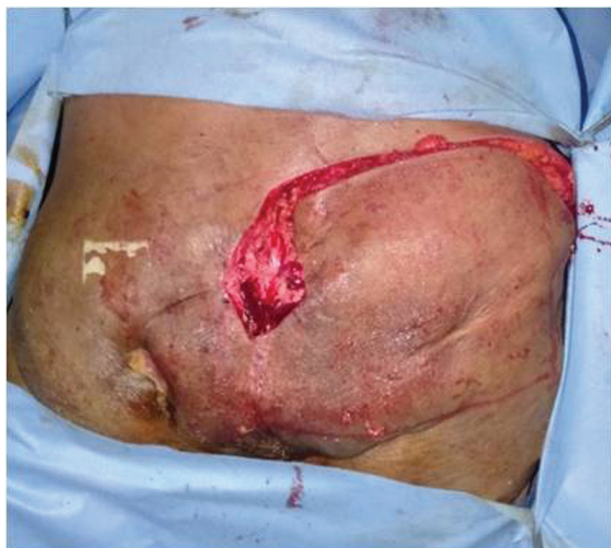Excision of ulcer base.

muscle and 2–3 cm beyond it. The role of anesthesia and technique and operative details and postoperative care and follow-up are also considered.

- (2) The patient was placed in a prone position and the following landmarks were marked: posterior superior iliac spine, coccyx, greater trochanter; the surface marking of the piriformis muscle is made by drawing a line between the posterior superior iliac spine and the greater trochanter of the femur. A second line is drawn between the top of the greater trochanter to a point midway between the posterior superior iliac spine and the coccyx. The superior gluteal artery and inferior gluteal artery and their perforators are

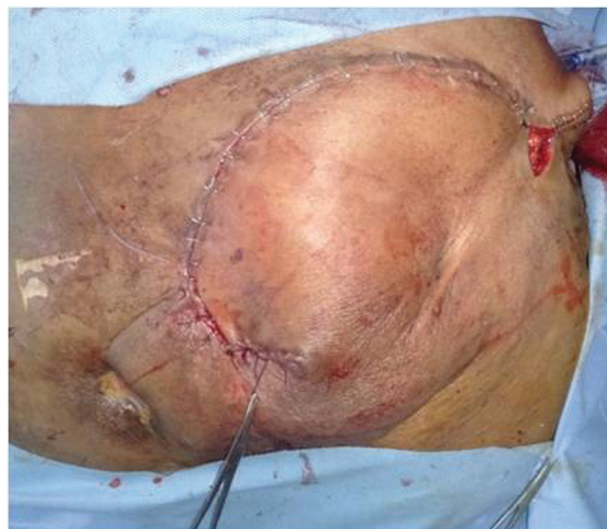- located above and below this triangle, respectively. Using a hand-held Doppler probe, all the perforator vessels were detected and marked on the skin (Fig. 2) [11,12].
- (3) To harvest this flap, the incision is made just lateral to the gluteal crease, extending it superiorly and laterally to the defect, but remaining medial to the greater trochanter as shown in Fig. 3.
- (4) Excision of the ulcer (Fig. 4).

Figure 5



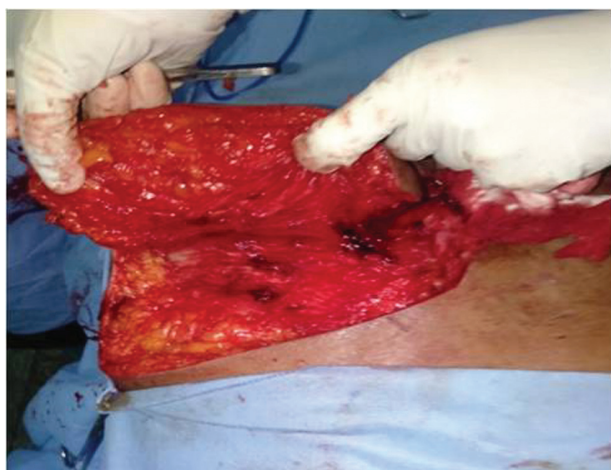Skin incision.

Figure 7



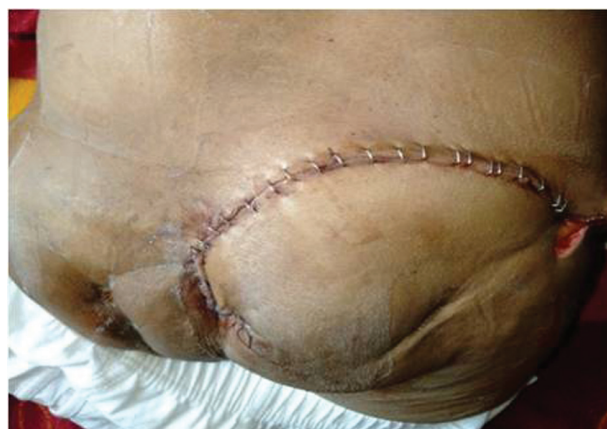Closure of the wound by skin staplers.

Figure 6



Dissection and separation of the myocutaneous flap.

Figure 8



One week postoperatively.

- (5) Skin incision (Fig. 5).
- (6) Dissection and separation of myocutaneous flap (Fig. 6).
The muscle is then elevated from its inferior border by dissecting into the areolar plane, which is below the muscle and above the sciatic nerve. The dissection should be continued until an adequate size is acquired to fully fill the defect.
- (7) Finally, the flap is placed into position by suturing the excess muscle into the depth of the wound, and closure is performed by layers (Figs 7–12).

Postoperative care

The patient is maintained on a low residue diet and kept in a prone or lateral position. Periodic turning in bed was started immediately. Negative suction was

continued until the collection of fluid stopped, that is about 2–3 weeks postoperatively.

Patients were followed up initially monthly for 3 months, every 3 months for a year, and then half yearly.

Results

This study was conducted in the General Surgery Department, Benha University Hospital on 20 patients with sacral pressure sore treated with the gluteus maximus myocutaneous flap.

Demographic characteristics

- (1) As regards age, the mean±SD age of the whole study population was 49±11 years.

- (2) As regards sex, 65% of the study population were men, while 35.0% were women.

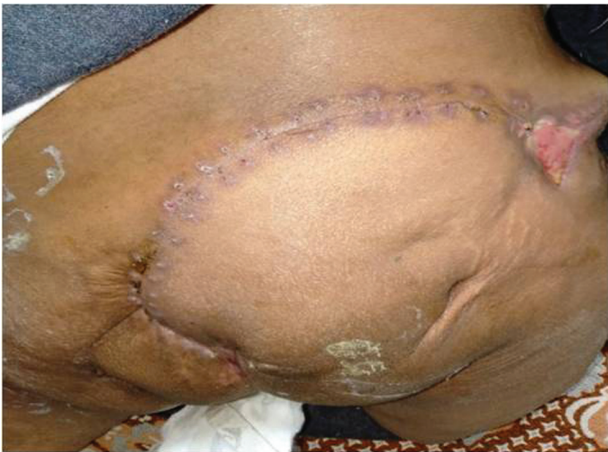Diagnosis

- (1) The most frequent diagnosis was traumatic paraplegia (25.0%), followed by encephalitis (20.0%) while the least frequent diagnoses were diabetic neuropathy, head injury, idiopathic quadriparesis, traumatic quadriplegia, and tuberculosis paraplegia (5.0% for each).

Preoperative assessment

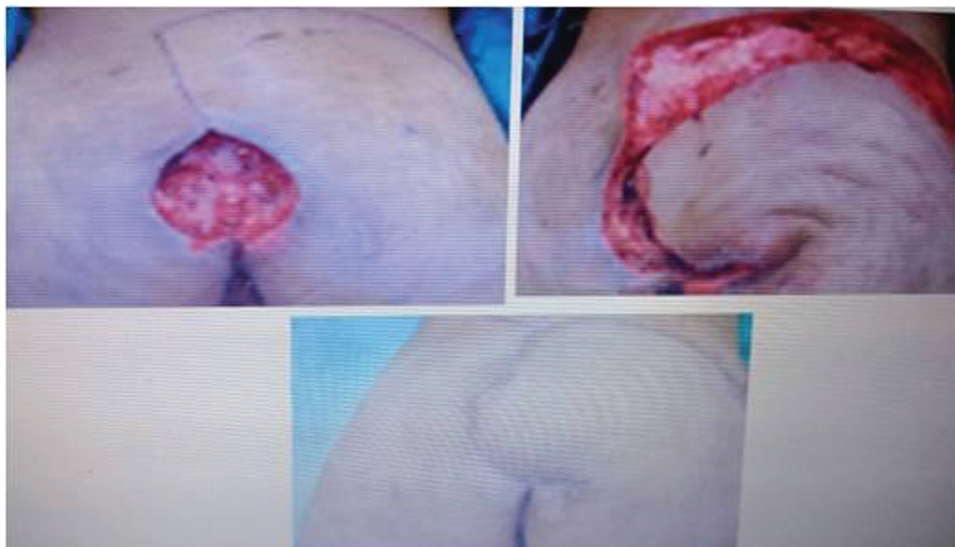Of the study patients, 60% were diabetics while 55% were hypertensive. Ischemic changes were reported in 50%. Fecal incontinence was found in 55 and 35% were smokers.

Figure 9



Six week postoperatively.

Figure 10



Case 1.

Operative details

- (1) As regards operative time, the mean±SD operative time was 45±5 min.
 (2) As regards blood loss, the mean±SD blood loss was 338±53.

Complications

- (1) The most frequent complications were hematoma and wound dehiscence (15% for each), followed by infection (10%). The least frequent complications were flap necrosis (5.0%) and recurrence (5.0%) (Tables 1–6).

Length of hospital stay and time to drain removal

The mean length of hospital stay was 4 days with a standard deviation of 2 days, while the mean time to drain removal was 6 days with a standard deviation of 2 days (Table 7).

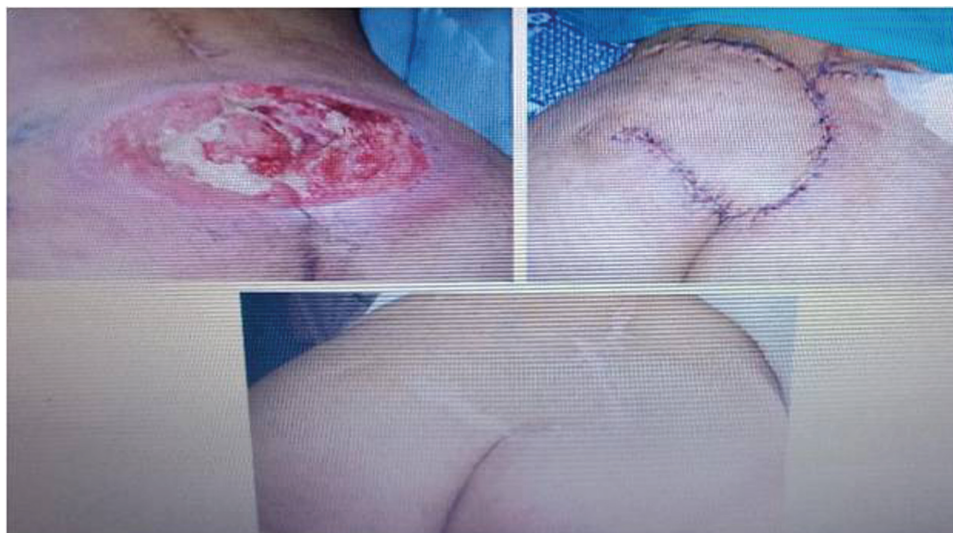Pigmentation and scarring

- (1) As regards pigmentation, 20.0% of the study population showed dark pigmentation, 10.0% showed hypopigmentation while 70% were normal.
 (2) As regards scarring, 70.0% of patients showed a linear scar, 20.0% showed hypertrophic scar while 10.0% showed a keloid scar (Table 8).

Patient satisfaction

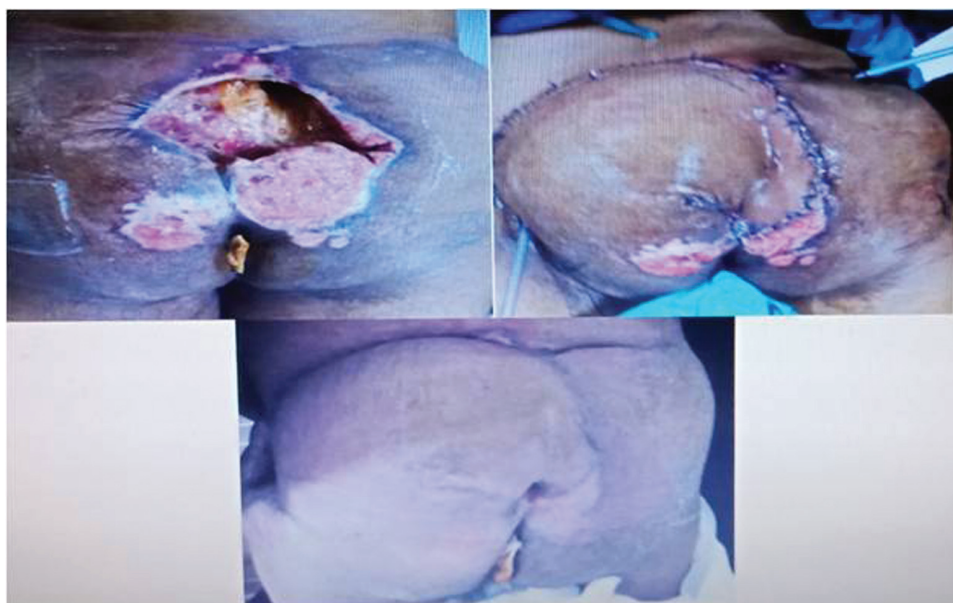
- (1) Half of the study population reported good satisfaction (50.0%); 20% reported excellent satisfaction and a same percent reported fair satisfaction.

Figure 11



Case 2.

Figure 12



Case 3.

Table 1 Demographic characteristics in the study population

Demographics	
Age (years)	
Mean±SD	49±11
Sex [n (%)]	
Males	13 (65.0)
Females	7 (35.0)

(2) Only 10% reported poor satisfaction (Table 9).

Complications and level of satisfaction

There was a significant association between complications and the level of satisfaction.

Complications were higher in those with poor to fair satisfaction (100%) compared with those with good to excellent satisfaction (14.3%). The *P* value was 0.001 (Table 10).

Discussion

Our study included 20 patients of which 13 were men and seven were women with age ranging from 38 to 60 years with five patients being between 30 and 40 years, four patients between 41 and 50 years, five patients between 51 and 60 years, and six patients over 60 years.

Table 2 Frequency distribution of the diagnosis in the study population

	<i>n</i> (%)
Diagnosis	
Diabetic neuropathy	1 (5.0)
Encephalitis	4 (20.0)
Fracture neck femur	1 (5.0)
Fracture pelvis	2 (10.0)
Head injury	1 (5.0)
Idiopathic quadriparesis	1 (5.0)
Traumatic paraplegia	5 (25.0)
Traumatic quadriplegia	1 (5.0)
Tuberculosis paraplegia	1 (5.0)
Tumor compression	3 (15.0)

Table 3 Frequency distribution of preoperative findings in the study population

	<i>n</i> (%)
Diabetes	12 (60.0)
Hypertension	11 (55.0)
Ischemic changes	10 (50.0)
Fecal incontinence	11 (55.0)
Smoking	7 (35.0)

Table 4 Sore stage and size in the study population

Sore size and stage	
Sore size (cm)	
Mean±SD	8±2
Sore stage [<i>n</i> (%)]	
III	9 (45.0)
IV	55.0)

While the Aggarwal *et al.* [3] study was conducted on 34 patients, two of which were children (under 18 years old), 12 between 19 and 29 years old, 11 between 30 and 39 years old, six between 40 and 49 years old, and three between 50 and 59 years old.

In the study conducted by Duci *et al.* [14], it included 55 patients. In this study, pressure ulcer (PUs) were predominant in male patients with 42 cases with only 13 cases in female patients. The incidence of pressure ulcers was noted to be higher in the age group of 30–39 years with 20 cases followed by children where the children are considered up to the age of 19 years by WHO with 10 cases, 20–29 years nine cases, 40–49 years five cases, 50–59 years five cases, 60–69 years two cases, and over 70 years four cases. The average age of patients was 34.8 years.

In our study, the most frequent diagnosis was traumatic paraplegia (25.0%), followed by encephalitis (20.0%) while the least frequent diagnoses were diabetic neuropathy, head injury, idiopathic quadriparesis,

Table 5 Operative time and blood loss in the study population

	Mean±SD
Operative time (min)	45±5
Blood loss	338±53

Table 6 Frequency distribution of the complications in the study population

	<i>n</i> (%)
Hematoma	3 (15.0)
Infection	2 (10.0)
Wound dehiscence	2 (10.0)
Flap necrosis	1 (5.0)
Recurrence	1 (5.0)

Table 7 Length of hospital stay and time to drain removal in the study population

	Mean±SD
Length of hospital stay (days)	4±2
Time to drain removal (days)	6±2

Table 8 Degree of skin pigmentation and scarring in the study population

	<i>n</i> (%)
Pigmentation	
Dark	4 (20.0)
Hypopigmented	2 (10.0)
Normal	14 (70.0)
Scarring	
Hypertrophic scar	4 (20.0)
Keloid scar	2 (10.0)
Linear scar	14 (70.0)

Table 9 Postoperative patient's satisfaction level

	<i>n</i> (%)
Satisfaction	
Excellent	4 (20.0)
Fair	4 (20.0)
Good	10 (50.0)
Poor	2 (10.0)

Table 10 Complications according to the level of satisfaction

	Satisfaction		<i>P</i> value
	Poor to fair	Good to excellent	
Complications [<i>n</i> (%)]			
Yes	6 (100.0)	2 (14.3)	0.001

traumatic quadriplegia, and tuberculosis paraplegia (5.0% for each).

According to Aggarwal *et al.* [3], of the 34 patients, 24 were tetraplegic, six paraplegics, and four had no neurological deficit.

According to Duci *et al.* [14], the patients with spinal cord injuries had the highest incidence of PUs with 48 cases, followed by three patients with cerebral injuries, orthopedic traumatic injuries with three cases, and one case with congenital anomaly of the spinal cord.

In our study, half of the study population reported good satisfaction (50.0%). In all, 20% reported excellent satisfaction and the same percent reported fair satisfaction, while only 10% reported poor satisfaction.

In the Aggarwal *et al.* [3] study, excellent to good results were observed in 30 (88.3%) cases. Recurrence due to major flap necrosis in one (2.9%) case was related to the general debilitating state of the patient. The poor results in two patients (including one with a major flap necrosis) were attributed to the poor quality of postoperative care and the general poor health of the patient.

In our study, 11 out of 20 had fecal incontinence, 85% of complications occurred in patients with fecal incontinence like infection, wound dehiscence, and recurrence.

According to RicaRdo Goes Figueiras [15], only one patient was not incontinent whereas 10 patients had fecal and urinary incontinence and six had only urinary incontinence. Of the total cases with postoperative complications (32%), half occurred in the sacral region. The high incidence in the sacral region may have been related to contact with feces and urine near the surgical scar since all patients but one had urinary or fecal incontinence.

In our study which included 20 patients 13 men and seven women with a mean age of 49 years old, all patients had pressure ulcers with different grades and sizes; all of which were treated surgically by gluteus maximus myocutaneous flap.

In our study, complications included three cases of hematoma, two cases of wound infection, two cases of wound dehiscence, one case of partial flap necrosis, and one case of recurrence with no cases of postoperative severe morbidity or mortality.

The hematoma cases passed conservatively by hot fomentation and alpha chymotrypsin oral tablets. Wound infection was also managed conservatively by local and systemic antibiotics according to culture and sensitivity; as regards two cases of wound dehiscence one case was managed by ordinary dressing and nutrition supplementation with multivitamins and minerals especially vitamin C, E, B complex, and

zinc. The other case requires secondary suture, as regards partial flap necrosis managed conservatively by chemical debridement with collagenase ointment but for the recurrence case scheduled for another option after 6 months.

According to Lin *et al.* [16] in the study of reusable perforator-preserving gluteal artery-based rotation fasciocutaneous flap for pressure sore reconstruction, which included 23 men and 13 women with a mean age of 59.3 years (range, 24–89 years). There were 24 sacral ulcers, 11 ischial ulcers, and one trochanteric ulcer. In this study, complications included four cases of tip necrosis, three wound dehiscences, two recurrences reusing the same flap for pressure sore reconstruction, one seroma, and one patient who died on the fourth postoperative day.

Conclusion

The gluteus maximus myocutaneous pedicled flap is a reliable and versatile flap by this simple approach. It is an ideal flap for patients in whom the risk of ulcer recurrence is high. We recommend the following guidelines for ensuring flap success and preventing recurrence: (a) strict preoperative as well as postoperative control of medical conditions such as diabetes mellitus and hypertension; (b) good preoperative mapping of perforator vessels using a Doppler probe; (c) adequate intraoperative debridement of the sore with complete bursectomy; (d) maintaining a prone position for 2 weeks postoperatively; and (e) preoperative and postoperative optimization of nutrition.

As these are the most important points of difficulties facing us to operate on this special patient in general and locally by bad hygiene, presence of weak anal sphincter and stool incontinence, atherosclerosis of feeding vessels.

Financial support and sponsorship

Nil.

Conflicts of interest

There are no conflicts of interest.

References

- 1 Moore ZEH, Cowman S. Repositioning for treating pressure ulcers. *Cochrane Database Syst Rev* 2012; 1:CD006898.
- 2 VanDenKerkhof EG, Friedberg E, Harrison MB. Prevalence and risk of pressure ulcers in acute care following implementation of practice guidelines: annual pressure ulcer prevalence census 1994-2008. *J Healthcare Qual* 2011; 33:58–67.
- 3 Aggarwal A, Sangwan SS, Siwach RC, Batra KM. Gluteus maximus island flap for the repair of sacral pressure sores. *Spinal Cord* 1996; 34:346–350.

- 4 Bauer J, Phillips LG. MOC-PSSM CME article: pressure sores. *Plast Reconstr Surg* 2008; 121:1–10.
- 5 Levine SM, Sinno S, Levine JP, Saadeh PB. An evidence-based approach to the surgical management of pressure ulcers. *Ann Plast Surg* 2012; 69:482–484.
- 6 Regan MA, Teasell RW, Wolfe DL, Keast D, Mortenson WB, Aubut JA. A systematic review of therapeutic interventions for pressure ulcers after spinal cord injury. *Arch Phys Med Rehabil* 2009; 90:213–231.
- 7 Ubbink DT, Westerbos SJ, Evans D, Land L, Vermeulen H. Topical negative pressure for treating chronic wounds. *Cochrane Database Syst Rev* 2008; 16:CD001898.
- 8 Smith F, Dryburgh N, Donaldson J, Mitchell M. Debridement for surgical wounds. *Cochrane Database Syst Rev* 2011; 3:CD006214.
- 9 Rubayi S, Chandrasekhar BS. Trunk, abdomen, and pressure sore reconstruction. *Plast Reconstr Surg* 2011; 128:201e–215e.
- 10 Kim YS, Lew DH, Roh TS, Yoo WM, Lee WJ, Tark KC. Inferior gluteal artery perforator flap: a viable alternative for ischial pressure sores. *J Plast Reconstr Aesthet Surg* 2009; 62:1347–1354.
- 11 Koshima I, Moriguchi T, Soeda S, Kawata S, Ohta S, Ikeda A. The gluteal perforator-based flap for repair of sacral pressure sores. *Plast Reconstr Surg* 1993; 91:678.
- 12 Verpaele AM, Blondeel PN, Van Landuyt K. The superior gluteal artery perforator flap: an additional tool in the treatment of sacral pressure sores. *Br J Plast Surg* 1999; 52:385.
- 13 Yasar B, Duru C, Ergani HM, Kaplan A, Igde M, Unlu RE. Safe and easy way to reconstruct pressure ulcers: gluteal artery perforator flaps. *Turk J Plast Surg* 2019; 27:193–198.
- 14 Duci SB, Arifi HM, Selmani ME, Mekaj AY, Gashi MM, Buja ZA, *et al.* Surgical treatment of 55 patients with pressure ulcers at the department of plastic and reconstructive surgery kosovo during the period 2000–2010: a retrospective study. *Plast Surg Int* 2013; 2013:129692.
- 15 RicaRdo Goes FiGueiRas. Surgical treatment of pressure ulcers: a two-year experience. *Rev Bras Cir Plást* 2011; 26:418–427.
- 16 Lin PY, Kuo YR, Tsai YT. A reusable perforator-preserving gluteal artery-based rotation fasciocutaneous flap for pressure sore reconstruction. *Microsurgery* 2012; 32:189–195.