

Endoscopic stenting as a bridge to elective surgery versus emergency laparotomy for patients with acute malignant large bowel obstruction

Taher H. Elwan, Nasser A. Zaher

Department of General Surgery, Faculty of Medicine, Benha University, Benha, Egypt

Correspondence to Taher H. Elwan, MD, Fareed Nada Street, Benha, 13511, Egypt. Tel: +20 100 357 2390; fax: +20 133 227 491/20 133 213 511; e-mail: drtaher2008@yahoo.com

Received: 12 January 2020

Revised: 17 January 2020

Accepted: 25 January 2020

Published: 28 August 2020

The Egyptian Journal of Surgery 2020, 39:529–535

Objectives

To evaluate the effect of colonic decompression using endoscopic colonic stenting (ECS) followed by elective surgery versus emergency surgical intervention in cases of acute obstructive malignancy of the colon.

Patients and methods

The current prospective comparative study includes 60 patients who presented with a picture of acute malignant colonic obstruction. The large bowel obstruction was defined as colonic dilation with multiple air-fluid levels on plain abdominal radiograph plus the findings of an abdomen computed tomography result compatible with a malignant stricture. Patients were classified according to the type of management into emergency surgery (ES) and ECS. Data were gathered and analyzed.

Results

In the ES group, 18/30 (60%) patients had a resection and primary anastomosis, 8/30 (26.7%) patients underwent Hartman's operation, whereas the remaining 4/30 (13.3%) underwent colostomy only. In the ECS group, 24/30 (80%) patients had a resection and primary anastomosis in an elective surgery, whereas the remaining 6/30 (20%) cases had a diverting stoma. All patients with obstructed colon cancer on the right side showed a clinical and technical success rate of 100% in both groups. However, obstructed colon cancer on the left side did not show the same rate of success in ES and ECS group. The ECS group showed a remarkably lower ($P=0.02$) rate of ICU admission than the ES group. The mean total hospital admission was remarkably longer ($P=0.047$) in the group ES group compared with the ECS group. Postoperative complications were remarkably higher ($P=0.028$) in the ES group compared with the ECS group.

Conclusion

ECS for patients having acute malignant right or left colonic obstruction is a safe and effective procedure, with excellent technical and clinical success rates.

Keywords:

emergency surgery, endoscopic colonic stenting, malignant colonic obstruction

Egyptian J Surgery 39:529–535
© 2020 The Egyptian Journal of Surgery
1110-1121

Introduction

Worldwide, colorectal cancer (CRC) is the third most common malignancy and one of the major causes of malignancy-related mortality. Obstruction of the bowel is the presenting manifestation in ~25% of patients with CRC. Emergency surgery (ES) has been the usual management for obstructing CRC; however, ES has high proportions of stoma formation, morbidity (40–50%), and mortality (15–20%) [1,2].

Recently, the use of an endoscopic colonic stenting (ECS) as a bridge of elective surgery has increased markedly. Many authors have reported that ECS improved the short-term surgical outcomes for acute malignant colonic obstruction [3]. Several studies comparing ECS as a bridge for elective surgery versus emergency laparotomy for malignant acute

colonic obstruction have shown significant decreases in the percentages of wound infection and stoma formation, with an increase in the rates of one-stage surgery [4]. Surgical decision making on facing a case of acute malignant colonic obstruction varies according to patient's fitness [5]. The classic decision is to do the three-steps procedure, so that the tumor resection was done on an elective setting after improving the patient's general condition after the relief of bowel obstruction [6].

ECS have been used in patients with inoperable obstructive CRC for palliation, in patients who are

This is an open access journal, and articles are distributed under the terms of the Creative Commons Attribution-NonCommercial-ShareAlike 4.0 License, which allows others to remix, tweak, and build upon the work non-commercially, as long as appropriate credit is given and the new creations are licensed under the identical terms.

unfit for resection, or as a bridge to elective surgery [7]. After relieving of bowel obstruction through the ECS, the differentiation between its role as a bridge to elective surgery or as a palliation is often done after the patient has been recovered from the acute obstruction. Analyzing the result of ECS for colonic obstruction revealed that it is a reasonably safe method with high clinical and technical success rates of 88 and 92%, respectively [8].

The present study tried to evaluate the outcome of using an ECS followed by elective resection of the tumor versus emergency operation in cases of acute malignant large bowel obstruction.

Patients and methods

The current prospective comparative study was conducted at the General Surgery Department of Benha University Hospital in Egypt and King Fahd Hospital in Saudi Arabia from December 2015 until December 2019. The study includes 60 consecutive patients who came to our emergency department having an attack of acute large bowel obstruction. The study protocol was approved by the Local Ethical Committee. For involvement in the study, signed informed consent was taken from all patients who in details were informed about the benefits and drawbacks of both treatment strategies.

Patients were evaluated clinically through general, abdominal, and digital rectal examination. Routine laboratory tests as well as diagnostic imaging were completed in the form of plain erect radiograph of the abdomen, ultrasonography for other organ pathology, and computed tomography (CT) scans with contrast of the abdomen. The diagnosis of the malignant large bowel obstruction had been established by the CT scan.

We included in our study (a) patients who had manifestations of large bowel obstruction for less than 1 week, with dilation of the colon on plain erect abdominal radiograph in left-side obstruction and dilation of ascending colon and small intestine in right-side obstruction and typical findings on abdominal CT well-matched with a malignant colonic stricture, (b) age more than or equal to 18 years, and (c) an American Society of Anesthesiology (ASA) score of less than IV.

Our exclusion criteria were (a) any serious complication that needs an urgent laparotomy, such as bowel perforation, peritonitis, fever, and sepsis; (b)

noncolonic obstruction; (c) nonmalignant large bowel obstruction; (d) the distal margin of the tumor being less than 10 cm from the anal verge; (e) ASA score more than III; (f) patients with psychiatric diseases; and (g) patients participating in other studies.

Patients were randomly, using sealed envelopes, allocated into two groups according to the type of management given: ES group (ES) and ECS group (ECS). Each group included 30 patients with acute malignant colonic obstruction.

The data collected from the patients included the following: (a) demographic data, including sex, age, duration of obstruction, if it was de novo or recurrent, the associated comorbidities, and tumor characteristics included location, whether left colon (if the tumor is present distal to the splenic flexure) or right colon (if the tumor is present proximal to the splenic flexure) and (b) procedural and postprocedural data. Data were collected and statistically analyzed.

Management plans

Group A (emergency surgery)

Operations were implemented according to conventional standards within 24 h after admission. Surgical options included either (a) Hartmann's procedure without resection, (b) resection with Hartmann's procedure, or (c) resection, on-table lavage, then primary anastomosis in the same setting with or without diverting stoma.

After stabilization of the patients' general condition following ES, patients who underwent a Hartmann's operation without resection, proper staging of the cancer was done. Colostomy was kept as a permanent solution if the patient refused the idea of re-operation or when the second operation was judged to carry an unsuitable risk (ASA grades >IV). In patients who underwent primary tumor resection and colostomy, the bowel continuity restoration was made within 3–6 months after the first surgery.

Group B (endoscopic colonic stenting)

Patients of this group underwent an ECS using Enteral Wallflex stent (Boston Scientific, Natick, Massachusetts, USA), which had a diameter of 22 mm and was accessible in three forms: 60, 90, and 120 mm. The ECS was preceded by an enema to prepare the left colon and intravenous dosage of prophylactic antibiotic. All the ECS procedures were

implemented under general anesthesia with airway active management to avoid bronchoaspiration, and also general anesthesia keeps the patient not moving during the procedure to decrease the possibility of endoscopic complications.

During endoscopy, limited insufflation was used to reduce the risk of perforation, and upon reaching the obstructing tumor, an attempt was made to pass the tumor with the endoscope. However, if the endoscope cannot pass through the tumor, we use a guide wire and passed it through the tumor under the guidance of the fluoroscopy. Then, the stent at this time can be inserted with the aid of fluoroscopy under endoscopic guidance. The length of the stent (6, 9, or 12 cm) was selected according to the length of the tumor predicted on the images of the CT, with 2 cm present at upper and lower sides of the lesion. In any procedure, no more than one stent was used.

Successful decompression was defined by the improvement of obstructive manifestations as patients passing flatus or stools and/or disappearance of nausea and vomiting, and no air–fluid levels on plain abdominal radiograph.

Post-endoscopic colonic stenting management

In case of successful decompression and the condition of the patient was improved, tumor staging was achieved (abdomen and chest CT scanning):

If patients were considered as at high risk owing to serious comorbidities, such as peritoneal carcinomatosis, advanced tumor, and/or irresectable metastatic lesions, at this time patients were considered not appropriate for surgery and ECS was considered as a palliative treatment.

- (1) If the patient was fit for surgery, elective surgery was conducted within 2 weeks of ECS.
- (2) If decompression did not occur within 3 days (failed ECS) or if the patient's condition clinically deteriorated, the patient was managed through emergency laparotomy as in group A.

Statistical analysis

Data were presented as mean±SD, ranges, numbers, and ratios. Results were analyzed using Wilcoxon's ranked test for unrelated data (*Z* test) and χ^2 test for numerical data. Statistical analysis was conducted using the IBM SPSS (version 23, 2015; IBM, Riyadh, Saudi Arabia) for Windows statistical package. *P* value less than 0.05 was considered statistically significant.

Results

The present study included 38 male patients and 22 female patients. The mean total duration of bowel obstruction of patients in ES group was 4.5±1.4 days, with range 1–6 days, versus 4.1±1.5 days, with range 2–6 days, in the ECS group. In the ES group, 60% of the tumors were located on the left-side colon (the tumor is present distal to the splenic flexure), whereas 40% of the tumors in the patients were located in the right-side colon (the tumor is present proximal to the splenic flexure in the transverse colon). Ten (33.3%) patients of the ECS group had the tumor on the right side, whereas 20 (66.7%) patients had a left colon lesion. There was nonremarkable difference between both groups regarding the remaining demographic and clinical data, as summarized in Table 1.

Among the patients of the ES group, 18 (60%) patients had a resection and anastomosis after colonic lavage and on-table irrigation; ten (55.6%) of them completed without a need for a diverting stoma, whereas eight (54.4%) cases had a diverting stoma because of bad general condition of the patients. Eight (26.7%) patients in this group underwent Hartman's operation (resection of the tumor and colostomy without anastomosis), whereas the remaining four (13.3%) cases underwent colostomy only owing to the bad general condition of the patients (Table 2).

All patients of the ECS group underwent successful stenting with a technical success rate of 100%; however, the effective decompression was accomplished only in 25 patients, giving a clinical success rate of 84.3%. Decompression failed in five patients in spite of a well-fitted stent, giving a clinical failure rate of 15.7% among patients of the ECS group, and these patients of failed decompression (considered as a failure rate of ECS) underwent an emergency operation as in ES group patients.

Among the patients of the ECS group, 24 (80%) patients had a resection and primary anastomosis in an elective surgery; 18 (75%) of these cases completed without a need for a diverting stoma, whereas the remaining six (25%) cases owing to bad general condition had a diverting stoma (Table 3, Fig. 1).

All patients with obstructed colon cancer on the right side underwent successful ECS and resection, and primary anastomosis was done in an elective setting with a clinical and technical success rate of 100%. Moreover, this type of patients showed the same

Table 1 Patients' demographic and disease-related data

Data	Strata	ES group (N=30)	ECS group (N=30)	P value
Age		59.6±11.5 (35–68)	60.3±12.2 (33–72)	NS
Sex	Males	18 (60)	20 (66.7)	NS
	Females	12 (40)	10 (33.3)	
Duration of the obstruction	1–3	8 (26.7)	10 (33.3)	NS
	4–5	15 (50)	12 (40)	
	6	7 (23.3)	8 (26.7)	
	Total	4.5±1.4 (1–6)	4.1±1.5 (2–6)	
Location of the tumor	Right colon	5 (16.7)	4 (13.3)	NS
	Left colon	25 (83.3)	26 (86.7)	
Chronic	Diabetes mellitus	11 (36.6)	9 (30)	NS
	Hypertension	6 (20)	7 (22.2)	
	Hepatic disease	5 (16.6)	6 (23.3)	
Comorbidities ^a	Chronic kidney disease	4 (12.3)	2 (6.7)	NS
	Chronic lung disease	2 (6.7)	2 (6.7)	
ASA grade	ASA I	8 (26.7)	10 (33.3)	NS
	ASA II	9 (30)	9 (30)	
	ASA III	13 (43.3)	11 (36.7)	

Data are presented as mean±SD (range) and *n* (%). ASA, American Society of Anesthesiologists; ECS, endoscopic colonic stenting; ES, emergency surgery. ^aSome cases had more than one comorbidity.

Table 2 The distribution of patients in emergency surgery group, according to the surgical process

	Strata	Number	
ES group		30	
Resection and primary anastomosis (N=18)	Without proximal stoma	10 (33.3)	
	With proximal stoma	Temporary (closed)	6 (20)
		Permanent	2 (6.7)
Resection and colostomy (Hartman's operation) (N=8)	Temporary (closed)	5 (16.6)	
	Permanent	3 (10)	
Colostomy only (N=4)	Temporary (tumor resection and closed)	2 (6.7)	
	Permanent	2 (6.7)	

Data are presented as *n* (%). ES, emergency surgery.

Table 3 The distribution of patients in endoscopic colonic stenting group, according to the management process

	Strata	Number	
ECS		30	
Successful decompression (N=25)	Resection and primary anastomosis	Without colostomy	18 (60)
		With colostomy	3 (10)
	Palliative stent	Temporary (closed)	3 (10)
		Permanent	3 (10)
Failed decompression (N=5)	Crossover to ES	1 (3.3)	
		5 (16.7)	

Data are presented as *n* (%). ECS, endoscopic colonic stenting; ES, emergency surgery.

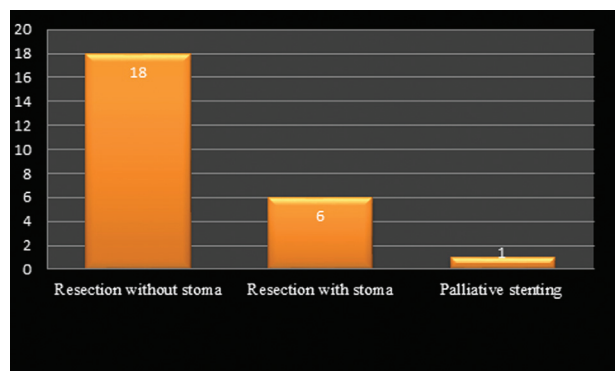
rate of success in the ES group. However, obstructed colon cancer on the left side did not show the same rate of success in ES and ECS group; only 16/28 (57%) patients and 19/27 (70.4%) patients underwent resection and primary anastomosis, respectively. These data revealed significant differences in the outcome of management between patients with obstructed right and left colon cancer (Table 4, Fig. 2).

For immediate postoperative (PO) care, 28 patients were admitted to ICU (18 in the ES group, including two cases of failed decompression, and 10 in the ECS

group), with significantly higher ($P=0.012$) rate of ICU admission among patients of the ES group. The mean total hospital stay days was significantly longer ($P=0.0472$) in the group ES group compared with the ECS group (Table 5).

During the immediate PO period and short-term follow-up, 19 complications were documented (12 in the ES group and seven in the ECS group), with a significantly higher rate ($P=0.0287$) in the ES group compared with the ECS group. There were 11 complications related to surgery and nine nonsurgical

Figure 1



The outcome of patients in the ECS group after successful stenting. ECS, endoscopic colonic stenting.

complications. The types and frequency of these complications are summarized in Table 5.

Discussion

ES for malignant colonic obstruction is difficult and accompanied with significant rates of mortality and morbidity [9]. Furthermore, there are concern about the proficiency of oncological resection as well as the long-range results when matched with the elective surgery results [1]. ECS enables the release of compressing forces of an acute colonic obstruction and to some extent converts the ES to elective one. Moreover, this maneuver has the benefit of raising the chance of laparoscopic resection, with subsequent potential reduction in the stoma rates [10].

Placement of stent has been described as a feasible option, enabling the release of compressing forces of the acute malignant large bowel obstruction, whereas in suitable cases being a bridge to surgery or when patients are classically in bad clinical state [11]. This provides enough time for the patient's clinical condition improve, while correctly staging and informing the patient concerning their actual condition [12]. Moreover, it can spare old-aged patients or those with advanced disease who would be unfit to undergo a major operation. It provides a significant palliative aid with good favorable outcome [13].

In our study that includes 60 patients with acute malignant colonic obstruction, 30 patients were managed with ECS. In this group of patients, the need for ICU admission was less, and also, the frequency of the PO complications was less in comparison with the other group patients who were managed with ES. These findings go with Cirocchi *et al.* [14] who proved that ES is accompanied with considerable higher PO mortality (20 vs. 12.8% elective

surgery). The World Society of Emergency Surgery has determined that in selected cases of malignant acute colonic obstruction, ECS may represent an effective option [15]. The great worry over ECS is the panic of tumor perforation, which could lead to the spread of cancer cells and increase the degree of tumor returning after good resection [16]. However, in our study, we did not record any case of colonic perforation during ECS, and the technical success rate was 100%. Other stent-related issues include pain, bleeding, and stent migration [17]. However, modern studies have showed a clinical and technical success rates of ECS in acute obstructing large bowel tumors of 90.5 and 81%, respectively, with minimum complications [18].

Nowadays, the use of ECS as a bridge to surgery (BTS) in cases of obstructing large bowel tumors is a well-settled strategy for management; however, the data about the oncological outcome are still not well studied. A controlled randomized trial in the Netherlands reported increased rate of mortality and morbidity in patients having ECS, as a BTS and was stopped early [11]. On the contrary, we as well as many other studies reported surgical and survival positive data on those having ECS for obstructing large bowel tumor and continued to elective curative resection.

This study has revealed that the technical favorable outcome rate of ECS is 100%, with minimum major complications in comparison with ES. The instant benefit of ECS placement is well settled in 25/30 in our study, with a success rate of 84.3%. However, a major worry over ECS placement as BTS is the negative effect it may have on oncological end results; however, this parameter was not studied in our research. Some studies showed increased risk of tumor metastasis and progression in those having self expandable metallic stents (SEMS) [19]. Suggested causes for this are the happening of microperforations at the time of stenting that leads to tumor dissemination and seeding [20].

The European Society of Gastrointestinal Endoscopists in 2014 does not advise the use of ECS as a BTS as basic treatment. However, European Society of Gastrointestinal Endoscopists only advises it in selected cases, where patients are tremendously high risk owing to associated morbidity, which makes ES risky and increases death rate [21]. An important article recorded an elevated perforation rate in those who have ECS placement (12.8%), with a higher rate of 30-day mortality [22]. Many other

Table 4 The patients' outcome in both groups according to the site of the cancer

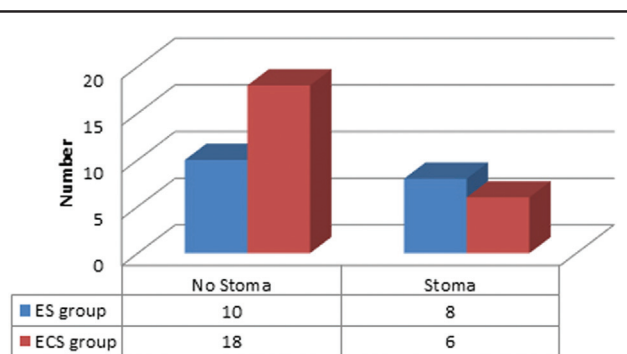
	Right colon (N=5)	Left colon (N=55)	P value
ES group	N=2	N=28	
Resection and primary anastomosis	2 (100)	16 (57)	0.0135
Resection and colostomy (Hartman's operation)	0.0	8 (28.6)	0.0243
Colostomy only	0.0	4 (14.3)	0.0421
ECS group	N=3	N=27	
Resection and primary anastomosis	3 (100)	18 (66.7)	0.0123
Resection and colostomy (Hartman's operation)	0.0	3 (11.1)	0.0511
Palliative stent	0.0	1 (3.7)	NS
Failed decompression	0.0	5 (18.5)	NS

Data are presented as *n* (%). ECS, endoscopic colonic stenting; ES, emergency surgery.

Table 5 Postoperative data

Data	Strata	ES group (N=35)	ECS group (N=25)	P value
ICU admission (days)	Number	18 (51.4)	10 (33.3)	0.012
	1–2	11 (31.4)	6 (20)	
	3–5	3 (8.5)	2 (6.7)	
	>5	4 (11.4)	2 (6.7)	
	Total	3.89±2.9 (1–11)	2.8±1.5 (1–8)	
Hospital stays (days)	<10	7 (20.3)	2 (8)	0.0472
	11–20	14 (40)	15 (60)	
	>20	14 (40)	8 (32)	
	Total	22.6±5 (8–36)	16.7±4.2 (9–31)	
Postoperative complications	Wound infection	5	3	0.028
	Anastomotic leakage	1	0.0	
	Intra-abdominal abscess	1	0.0	
	Intestinal obstruction	1	1	
	Urinary tract infection	0.0	1	
	Lung problems	3	2	
	Acute renal failure	1	0	
	Total	12	7	

Data are presented as *n* (%). ECS, endoscopic colonic stenting; ES, emergency surgery.

Figure 2

The frequency of patients who needed stoma after resection and primary anastomosis in both groups.

articles have recorded an increase of local recurrence rate in patients who have an ECS-related complications, but most studies have not recoded negative oncological end results [21]. Erichsen *et al.* [23] stated a 5-year tumor recurrence of 39% after ECS versus 30% possess ES; however, no difference was reported in long-run survival.

In our study, stoma formation rate was remarkably lower in the ECS group in comparison with the ES group. A large study noticed a decreased formation of stoma in the BTS without a deleterious effect on 1-year survival [24]. A comprehensive meta-analysis study notified no difference in the mortality rates between ECS and ES cohorts (7% each), but it agreed with us and noted remarkable differences in PO rates of complications (37% ECS vs. 54% ES), rates of stoma (25% ECS vs. 46% ES), and rates of wound infection (8% ECS vs. 15%) [25,26]. Alcántara *et al.* [27] reported an increased percentage of anastomotic leak in patients who proceed directly to ES, whereas Öistämö *et al.* [28] reported increased lymph node metastasis in those who possess ECS as a BTS versus those having ES.

Till now, a few research studies have studied the long-run overall survival by using the ECS as a BTS in acute malignant colonic obstruction. Neither Choi *et al.* [29] nor Lee *et al.* [21] noticed differences in survival rates in the ECS versus ES.

Long-term survival of ECS in malignant acute colonic obstruction needs more effort and larger studies.

Conclusion

ECS for chosen patients who have acute right or left colonic malignant obstruction is an effective management and safe procedure with an excellent favorable outcome rate in both technical and clinical aspects. ECS allows the release of obstruction with subsequent significantly higher percentage of resection and primary anastomosis as well as reduced the need for colostomy with a significant decrease of ICU admission and total hospital stay days, without a significant rise in PO morbidity and mortality rates.

Financial support and sponsorship

Nil.

Conflicts of interest

There are no conflicts of interest.

References

- Siegel L, Miller D, Fedewa A, Ahnen J, Meester S, Barzi A, Jemal A. Colorectal cancer statistics. *CA Cancer J Clin* 2017; 67:177–193.
- Shimura T, Joh T. Evidence-based clinical management of acute malignant colorectal obstruction. *J Clin Gastroenterol* 2016; 50:273–285.
- Sanoff K. Best evidence supports annual surveillance for resected colorectal cancer. *JAMA* 2018; 319:2083–2085.
- Amelung J, Draaisma A, Consten J, Siersema D, Ter Borg F. Self-expandable metal stent placement versus emergency resection for malignant proximal colon obstructions. *Surg Endosc* 2017; 31:4532–4541.
- Huang X, Lv B, Zhang S, Meng L. Preoperative colonic stents versus emergency surgery for acute left-sided malignant colonic obstruction: a meta-analysis. *J Gastrointest Surg* 2014; 18:584–591.
- Jeong S, Kim H, Kim J. Surgical outcomes and risk factors in patients who underwent emergency colorectal surgery. *Ann Coloproctol* 2017; 33:239–244.
- Di Saverio S, Birindelli A, Segalini E, Novello M, Larocca A, Ferrara F, *et al.* 'To stent or not to stent?': immediate emergency surgery with laparoscopic radical colectomy with CME and primary anastomosis is feasible for obstructing left colon carcinoma. *Surg Endosc* 2018; 32:2151–2155.
- Furuke H, Komatsu S, Ikeda J, Tanaka S, Kumano T, Imura KI, *et al.* Self-expandable metallic stents contribute to reducing perioperative complications in colorectal cancer patients with acute obstruction. *Anticancer Res* 2018; 38:1749–1753.
- Tekkis P, Kinsman R, Thompson R, Stamatakis D. The Association of Coloproctology of Great Britain and Ireland study of large bowel obstruction caused by colorectal cancer. *Ann Surg* 2004; 240:76–81.
- Hill J, Kay C, Morton D, Magill L, Handley K, Gray G. CREST: randomised phase III study of stenting as a bridge to surgery in obstructing colorectal cancer – results of the UK colorectal endoscopic stenting trial (CREST). *J Clin Oncol* 2016; 34 (Suppl):3507–3507.
- Arezzo A, Balague C, Targarona E, Borghi F, Giraudo G, Ghezzi L, *et al.* Colonic stenting as a bridge to surgery versus emergency surgery for malignant colonic obstruction: results of a multicentre randomized controlled trial (ESCO trial). *Surg Endosc* 2017; 31:3297–3305.
- Lim G, Lee J, Lee S. Preoperative colonoscopy for detection of synchronous neoplasm after self-expandable metallic stent insertion in occlusive colorectal cancer: comparison of covered and uncovered stents. *Gastrointest Endosc* 2013; 77:AB449.
- Kim S, Lee M, Kim W, Kim J, Lim H, Oh T, *et al.* Preoperative colonoscopy through the colonic stent in patients with colorectal cancer obstruction. *World J Gastroenterol* 2014; 20:10570–10576.
- Cirocchi R, Farinella E, Trastulli S, Desiderio J, Listorti C, Boselli C, *et al.* Safety and efficacy of endoscopic colonic stenting as a bridge to surgery in the management of intestinal obstruction due to left colon and rectal cancer: a systematic review and meta-analysis. *Surg Oncol* 2013; 22:14–21.
- Stankiewicz R, Koziel S, Pertkiewicz J, Zieniewicz K. Outcomes and complications of self-expanding metal stent placement for malignant colonic obstruction in a single-center study. *Wideochir Inne Tech Maloinwazyjne* 2018; 13:53–56.
- Small J, Coelho-Prabhu N, Baron H. Endoscopic placement of self-expandable metal stents for malignant colonic obstruction: long-term outcomes and complication factors. *Gastrointest Endosc* 2010; 71:560–572.
- Kim J, Kim W, Park B, Kang H, Choi W, Song J, *et al.* Colonic perforation either during or after stent insertion as a bridge to surgery for malignant colorectal obstruction increases the risk of peritoneal seeding. *Surg Endosc* 2015; 29:3499–3506.
- Han H, Lee H. Colonic stent-related complications and their management. *Clin Endosc* 2014; 47:415–419.
- Verstockt B, Van Driessche A, De Man M, van der Spek P, Hendrickx K, Casneuf V, *et al.* Ten-year survival after endoscopic stent placement as a bridge to surgery in obstructing colon cancer. *Gastrointest Endosc* 2018; 87:705–713.
- Van den Berg W, Sloothaak A, Dijkgraaf G, Van der Zaag S, Bemelman A, Tanis J, *et al.* Bridge-to-surgery stent placement versus emergency surgery for acute malignant colonic obstruction. *Br J Surg* 2014; 101:867–873.
- Lee J, Yoon Y, Park J, Park J, Kim H, Youn H, *et al.* Clinical outcomes and factors related to colonic perforations in patients receiving self-expandable metal stent insertion for malignant colorectal obstruction. *Gastrointest Endosc* 2018; 87:1548–1557.
- Khot P, Lang W, Murali K, Parker C. Systematic review of the efficacy and safety of colorectal. *Br J Surg* 2002; 89:1096–1102.
- Erichsen R, Horváth-Puhó E, Jacobsen B, Nilsson T, Baron A, Sørensen T. Long-term mortality and recurrence after colorectal cancer surgery with preoperative stenting: a Danish nation wide cohort study. *Endoscopy* 2015; 47:517–524.
- Donlon E, Kelly E, Narouz F, McCormick H, Larkin O, Mehigan J. Colonic stenting as a bridge to surgery in malignant large bowel obstruction: oncological outcomes. *Inter J Colorec Dis* 2019; 34:613–619.
- Ribeiro B, de Moura H, Thompson C, de Moura H. Acute abdominal obstruction: colon stent or emergency surgery? An evidence-based review. *World J Gastrointest Endosc* 2019; 11:193–208.
- Allievi N, Ceresoli M, Fugazzola P, Montori G, Coccolini F, Ansaloni L. Endoscopic stenting as bridge to surgery versus emergency resection for left-sided malignant colorectal obstruction: an updated meta-analysis. *Int J Surg Oncol* 2017; 2017:2863272.
- Alcántara M, Serra-Aracil X, Falcó J, Mora L, Bombardó J, Navarro S. Prospective, controlled, randomized study of intraoperative colonic lavage versus stent placement in obstructive left-sided colonic cancer. *World J Surg* 2011; 35:1904–1910.
- Öistämö E, Hjern F, Blomqvist L, Falkén Y, Pekkarinen K, Abraham-Nordling M. Emergency management with resection versus proximal stoma or stent treatment and planned resection in malignant left-sided colon obstruction. *World J Surg Oncol* 2016; 14:232.
- Choi M, Lee C, Han M, Lee M, Choi H, Jang K, *et al.* Long-term oncologic outcomes of endoscopic stenting as a bridge to surgery for malignant colonic obstruction: comparison with emergency surgery. *Surg Endosc* 2014; 28:2649–2655.