

Outcome of pudendal thigh flap in scrotal reconstruction and its effect on testicular function

Mohamed T. Younes, Ahmed M. Nawar, Ahmed A. Shoulah

Department of General Surgery, Faculty of Medicine, Banha University, Banha, Egypt

Correspondence to Ahmed M. Nawar, MD, Department of General Surgery, Faculty of Medicine, Banha University, Banha, Qalubia, 13511, Egypt. Tel: 002 01068077332; e-mail: nowar79@yahoo.com

Received 11 December 2018

Accepted 18 December 2018

The Egyptian Journal of Surgery 2019, 38:399–405

Introduction

Reconstruction of major scrotal defects represent a great challenge for surgeons. Although a lot of therapeutic methods have been established for the reconstruction of these defects, each technique has its own advantages and disadvantages. The pudendal thigh flap is an axial and sensate fasciocutaneous flap based on the terminal branches of the superficial perineal artery, which is a continuation of the internal pudendal artery (below the urogenital diaphragm). The data on the testicular function after reconstruction of cover for the testes have been rarely reported. In this study, follow-up of patients with pudendal thigh flap was done regarding esthetic outcome, functional outcome, and testicular function.

Aim

The aim of this study was to show the versatility and usefulness of posteriorly based pudendal thigh flap for scrotal reconstruction and to evaluate its effect on testicular function.

Patients and methods

A total of 19 flaps in 13 patients with major scrotal defects were subjected to reconstruction using posteriorly based pudendal thigh flap. The cause of scrotal skin loss was Fournier gangrene in nine cases, trauma in three cases, and animal bite in one case. Six patients underwent bilateral flap reconstructions, and seven patients underwent unilateral flap reconstructions.

Results

All 19 flaps survived completely with good color matching. The donor site was closed directly, and the scar was hidden in the inguinal crease. One patient had wound dehiscence in the donor site and required a secondary procedure for healing. Testicular function regarding spermatogenesis and hormonal functions showed nonsignificant changes 6 months and 1 year after flap coverage.

Conclusion

Posteriorly based pudendal thigh flap is a good option for reconstruction of major scrotal defects. This flap gives a wide coverage with excellent esthetic appearance of the scrotum, without any significant effect on testicular function.

Keywords:

Fournier's gangrene, pudendal thigh flap, scrotal reconstruction, spermatogenesis

Egyptian J Surgery 38:399–405
© 2019 The Egyptian Journal of Surgery
1110-1121

Introduction

Scrotal skin loss can occur following many factors, including trauma, tumor excision, Fournier's gangrene, and burn. Fournier gangrene is one of the most common causes of scrotal skin loss. It is a synergistic necrotizing fasciitis spreading deeply along the fascial planes of the perineum, inner thighs, penis, scrotum (or vagina), and lower abdomen. It is usually associated with significant loss of the covering soft tissue. In cases of Fournier gangrene of the scrotum, the testes usually survive and remain exposed, because they have an independent blood supply from the testicular artery [1].

Management and reconstruction of scrotal defects after different types of injuries may present a challenge. In cases with partial scrotal skin loss, it can be managed by debridement and primary closure; however, in cases

with large or total defects of the scrotum, there are different options, including residual scrotal skin mobilization for defects up to 50%, split-thickness skin graft [2], thigh flaps with pouch [3], use of tissue expanders [4], gracilis myocutaneous flap [5], groin island fasciocutaneous flap [6], superomedial thigh flaps [7], and pudendal thigh flaps. The choice of the method of reconstruction depends on many factors, including the defect size, the quality of the surrounding skin, surgeon's preference, and the choice of the patient. The presence of multiple techniques in scrotal reconstruction demonstrates that there is no single ideal reconstructive technique.

This is an open access journal, and articles are distributed under the terms of the Creative Commons Attribution-NonCommercial-ShareAlike 4.0 License, which allows others to remix, tweak, and build upon the work non-commercially, as long as appropriate credit is given and the new creations are licensed under the identical terms.

Reconstruction of the scrotum is important for functional, esthetic, and psychological causes.

To have an ideal reconstruction of the scrotum, it should be a single-staged technique, provide a nonbulky soft tissue coverage of the testis, maintain thermoregulation that does not interfere with spermatogenesis, maintain a natural looking scrotal ptosis and color matching, and be resilient to withstand shearing forces from the thighs with the least donor site morbidity [8].

Local pedicled fasciocutaneous flap is usually the appropriate choice for scrotal reconstruction as it avoids skin graft problems, preserves adequate sensation, is not technically demanding like free flaps or musculocutaneous flaps, and can cover large defects [9].

The pudendal thigh flap is an axial and sensate fasciocutaneous flap that is based on the terminal branches of the superficial perineal artery, which is a continuation of the internal pudendal artery (below the urogenital diaphragm), which is a major branch of the internal iliac artery [10]. This flap was first described by Wee and Joseph [11], and since then, it has been reported several times in vaginal reconstruction by many authors.

The main scrotal function is the local regulation of testicular temperature to keep it within a range of two to eight degrees lower than the abdominal temperature, which is necessary for normal spermatogenesis, so the testicular temperature in the reconstructed location should be maintained as close as possible to that of normal scrotal temperature to allow spermatogenesis [12].

In this study, we aimed at introduction and evaluation of posteriorly based pudendal thigh flap in scrotal reconstruction and studying its effect on testicular functions.

Patients and methods

Thirteen patients with scrotal defects were admitted to our plastic unit in General Surgery Department, Benha University hospital, from 2015 to 2018 for scrotal reconstruction after obtaining approval from the local ethical committee and after fully informed written consent, which was signed by the patient. The cause of the defect was Fournier's gangrene in nine patients, trauma in three patients, and animal bite in one patient. The mean defects area was from 7

to 18 cm². All patients were examined for general condition systematically to evaluate and control any life-threatening conditions, and supportive treatment was given. Then local wound care was done by surgical debridement of all necrotic tissues, and then daily dressing applications were performed using saline irrigation and povidone iodine. Swab was taken from the wound for culture and sensitivity, and the proper antibiotic was initiated.

Inclusion criteria were scrotal defect with major skin loss, whereas exclusion criteria include minor skin loss that can be treated with release and primary closure, and patients with significant co-morbidities (cardiopulmonary problems, advanced liver, or renal diseases) that interfere with surgery.

Of these 13 patients, six need bilateral flaps and seven need unilateral. Eight patients were diabetic, under control with insulin treatment. Six patients were smokers, and we asked them to stop smoking 7 days before surgery. Semen analyses were done in the biochemistry laboratory of our university hospital, with proper semen samples taken from patients before surgery.

Surgical technique

The patient lied in the lithotomy position under general anesthesia or spinal anesthesia, and then we measured the size of the scrotal defect using a large gauze swab. The site of the perforator on the base of the flap was detected using handheld Doppler and marked. The flap was designed being rectangular in shape with its distal end tapering to allow direct closure of the donor area without dog ear formation.

The flap was designed so that the groin crease was located in its midline to allow the donor area scar to be hidden in the groin crease. The measurement of the flap (width and length) was designed based on the size of the defect of the scrotum. The assessment of closing the defect directly is checked by a finger pinch test. The flap was raised from distal to proximal as a fasciocutaneous flap. We stopped dissection once the length of the flap raised is adequate to be wrapped around the testis-spermatic cord complex. The flap was then turned ~90° with the deep part of raised flap facing the testis-spermatic cord complex, with its distal edge subcutaneous tissues sutured to fibroadipose tissues at the other side making one flap cranial and the other caudal to cover the raw area. The two flaps were sutured together with the cranial one sutured to the root of the penis and the caudal one to the lower

border of the defect using vicryl 30. Two drains are inserted one under each flap, and the donor area was closed primarily.

Postoperative care

After surgery, the patients were followed up in bed in the supine position with flexion and internal rotation of the thighs to relieve tension on the flap and donor site for at least 5 days. We allowed the patient to start mobility out of bed 1 day postoperatively. Postoperative antibiotics were given. We removed the drain 2–3 days after surgery. No postoperative anticoagulants were given. On the sixth postoperative day, the patients were discharged and followed up as outpatients. Removal of skin sutures were done after 10–14 days. All patients were followed up for 1 year, and semen analysis was done 6 months and 1 year after surgery.

Statistical analysis

Obtained data were presented as mean±SD, median, interquartile range, numbers, and percentages. Results were analyzed using Mann–Whitney and Wilcoxon tests. Statistical analysis was conducted using the SPSS (Version 20, 2006) for Windows statistical package Version 21 (IBM Corp., Armonk, New York, USA). *P* value less than 0.05 was considered statistically significant.

Table 1 Detailed characteristics of the studied group

Case no.	Age	Cause	Smoking	Concomitant disease	Scrotal defect
1	32	Fournier's gangrene	Yes	Diabetes mellitus	Total
2	46	Fournier's gangrene	No	Diabetes mellitus	Partial (right)
3	50	Fournier's gangrene	Yes	Diabetes mellitus and hypertension	Total
4	22	Trauma	No	No	Partial (Right)
5	37	Fournier's gangrene	Yes	Diabetes mellitus	Total
6	20	Trauma	No	No	Partial (left)
7	55	Fournier's gangrene	No	Diabetes mellitus	Total
8	43	Fournier's gangrene	Yes	Diabetes mellitus	Total
9	29	Animal bite	No	No	Partial (right)
10	33	Fournier's gangrene	Yes	No	Partial (left)
11	35	Trauma	Yes	No	Partial (right)
12	42	Fournier's gangrene	No	Diabetes mellitus	Total
13	58	Fournier's gangrene	No	Diabetes mellitus and hypertension	Partial (left)

Results

The median follow-up period was 13 months (range: 12–14 months). The study included 13 patients with a mean age of 38.6 years (range: 20–58 years). Nineteen pudendal thigh fasciocutaneous flaps were used to cover scrotal defects in 13 patients. Of these patients, bilateral flaps were used in six patients and unilateral flap used in seven patients. The average width of the flap was 8 cm, ranging from 5–12 cm. All flaps survived well, and the scar of the donor site healed primarily, except one case of wound sepsis and disruption that was followed by daily dressing and then grafting. The patients were satisfied of the esthetic results of the flap, as the flap was thin and its texture was the same as that of scrotal skin, and also the scar of the donor site was hidden in the groin crease (Table 1).

Table 1 shows patients' mean age was 38.6 years (range: 20–58 years), and the cause of scrotal skin loss was Fournier gangrene in nine (69.2%) cases, trauma in three (23%) cases, and animal bite in one (7.6%) case. Of the studied groups, there were six (46.15%) smokers, eight (61.53%) diabetics, and two (15.38%) hypertensives. Regarding the scrotal defect, seven (53.85%) cases had total scrotal skin loss, and six (46.15%) cases had partial scrotal skin loss.

Table 2 shows the causative organisms of scrotal wound, which were group A *Streptococci* spp. in six (46.15%) cases, *Pseudomonas* spp. in four (30.77%) cases, and *Proteus* spp. and *Klebsiella* spp. in three (23.08%) cases.

Table 3 shows early postoperative complications, where two cases show flap congestion (15.38%) that was relieved by removing some stiches. Flap necrosis was not detected in any case, and wound disruption was observed in one (7.7%) case, which occurred in the

Table 2 Microbiology results of wound culture

Case no.	Organism	Case no.	Organism
1	Group A: <i>Streptococci</i> spp.	8	Group A: <i>Streptococci</i> spp.
2	Group A: <i>Streptococci</i> spp.	9	<i>Proteus</i> spp. and <i>Klebsiella</i> spp.
3	<i>Pseudomonas</i> spp.	10	Group A: <i>Streptococci</i> spp.
4	Group A: <i>Streptococci</i> spp.	11	<i>Proteus</i> spp. and <i>Klebsiella</i> spp.
5	<i>Proteus</i> spp. and <i>Klebsiella</i> spp.	12	<i>Pseudomonas</i> spp.
6	Group A: <i>Streptococci</i> spp.	13	<i>Pseudomonas</i> spp.
7	<i>Pseudomonas</i> spp.		

Table 3 Early postoperative complications

	Congestion	Flap necrosis	Wound disruption	Hematoma	Wound infection
1	Yes	No	No	No	Yes
2	No	No	No	No	No
3	No	No	Yes	No	No
4	No	No	No	No	No
5	No	No	No	Yes	No
6	No	No	No	No	No
7	No	No	No	No	No
8	No	No	No	No	Yes
9	No	No	No	No	No
10	No	No	No	No	No
11	No	No	No	No	No
12	Yes	No	No	No	No
13	No	No	No	Yes	Yes

Table 4 Long-term outcome

Case no.	Ulcers	Walking	Protective sensation	Sexual function
1	No	Yes	Yes	Yes
2	No	Yes	Yes	Yes
3	No	Yes	Yes	Yes
4	No	Yes	No	Yes
5	No	Yes	Yes	Yes
6	No	Yes	Yes	Yes
7	No	Yes	Yes	Yes
8	No	Yes	Yes	Yes
9	No	Yes	Yes	Yes
10	No	Yes	Yes	Yes
11	No	Yes	No	Yes
12	No	Yes	No	Yes
13	No	Yes	Yes	No

donor wound, and it was managed by daily dressing and then split-thickness skin graft. Hematoma under the flap was observed in two (15.38%) cases. It occurred after removal of the drain and was evacuated by removing a stitch. Regarding wound infection, it was noticed in three cases and was subsided by antibiotics and dressing.

Table 4 shows the long-term outcome of the 13 cases. There was no ulcer formation and no problems with waking. Preserved sensation was seen in 10 (76.9%) cases, whereas three (23.1%) cases showed lost scrotal sensation. Regarding sexual function, there was no affection on sexual function in 12 (92.3%) cases.

Table 5 shows semen analysis regarding sperm volume (ml), sperm count (million/ml), total motility (%), progressive motility (%), vitality (live spermatozoa %), and normal morphology percentage by comparing these parameters before surgery, 6 months after surgery, and 1 year after surgery. There was nonsignificant changes ($P \leq 0.005$) in all parameters.

Table 5 Semen analysis

	Preoperative	6 months postoperative	1 year postoperative
Volume (ml)	1.5±0.44	1.3±0.6	1.4±0.55
Sperm count (million/ml)	34.6±26.53	31.2±28.34	30.4±25.67
Total motility (%)	36.9±10.44	34.5±12.3	33.7±9.67
Progressive motility (%)	28±13.53	22±10.76	21±11.13
Vitality (live spermatozoa %)	58±15.65	55±16.9	53±14.77
Normal morphology percentage	55±14.22	47.8±18.1	46.25±17.33

In our study, we used semen volume (ml), sperm count per milliliter (million/ml), total motility (%), progressive motility (%), and normal morphology criteria.

Table 6 Hormonal analysis

	Preoperative	6 months postoperative	1 year postoperative
Testosterone (ng/ml)	6.2±1.5	5.9±1.2	6.1±1.8
FSH (mIU/ml)	4.6±1.6	5.2±1.9	4.8±2.1
LH (mIU/ml)	3.3±1.1	3.9±1.5	3.6±0.9

FSH, follicle-stimulating hormone; LH, luteinizing hormone.

Table 6 shows hormonal analysis regarding serum testosterone, follicle-stimulating hormone (FSH), and luteinizing hormone (LH). There were nonsignificant changes ($P \leq 0.005$) to the hormonal level 6 months and 1 year after surgery (Figs 1 and 2).

Discussion

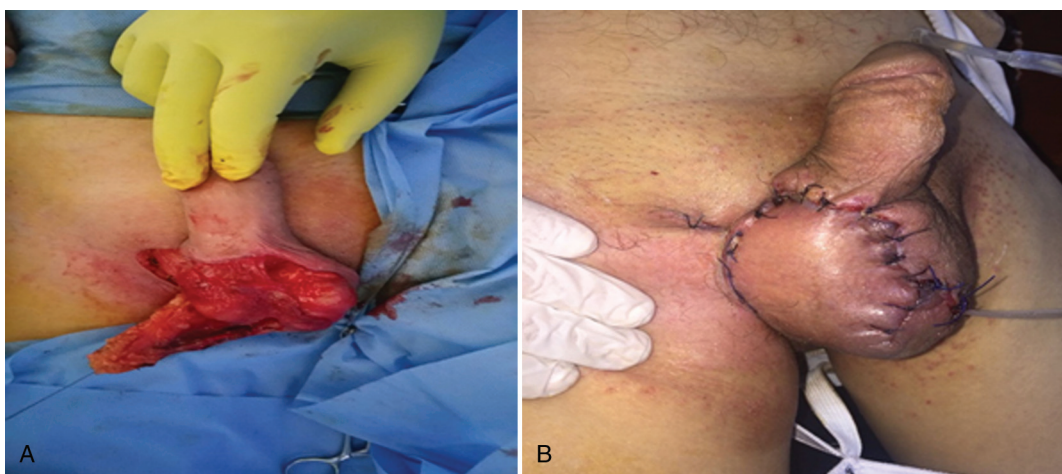
A lot of therapeutic modalities have been used for scrotal reconstruction. Each of which has its own benefits and drawbacks. Of all these techniques, split-thickness skin graft is the simplest technique. It is an effective technique to cover the whole scrotum as well as the surrounding skin defect. The take of the graft is good owing to abundant vascularity of raw surface of testes; however, the take can be poor if there is loss of tunica vaginalis [13]. If the skin grafts are not applied early in such cases, the long-time exposure of the testes and spermatic cord make them rigid and shrink with formation of a thick granulation tissue. When applying the skin grafts in such a condition, this leads to more contraction and distortion. So debridement of the granulation tissue is essential to avoid this problem, but this causes a lot of bleeding, and it is time consuming with high incidence of damage to the structures [7]. In the long-term follow-up, the skin of the reconstructed scrotum becomes dry, contracted, provides little padding, has reduced resilience to the shearing forces of the thigh against the scrotum, and the cosmetic results can be unsatisfactory [14].

Figure 1



(a) Preoperative marking of bilateral flap. (b and c) Intraoperative results after closure of the flap and donor area. (d and e) Postoperative results after 3 months and 1 year of surgery.

Figure 2



(a) Intraoperative dissection of unilateral flap. (b) The flap after closure.

The use of tissue expansion in scrotal reconstruction helps to cover the skin defect, but it has many drawbacks, as it is a staged procedure that needs multiple sessions, with high risk of infection to the expander in this area. Moreover, the surrounding skin may not be available for expansion [4].

The use of medial thigh pouch to place the testes using the laxity of medial thigh skin is an advantage. However, this technique has a bad psychological effect on the patient, as the testes are missing in the medial thigh losing the dependent position of the scrotum between the thighs. Moreover, the presence of testes in the thigh pouch allows the testes to get exposed to core temperature of the body and may interfere with spermatogenesis [15].

Regulation of scrotal temperature is important for spermatogenesis. Bulky thigh fasciocutaneous flaps and musculocutaneous flaps may affect spermatogenesis, as the testis is covered by thick fat or muscle that may elevate the temperatures of the testis in the reconstructed scrotum, which may affect spermatogenesis. However, till now, there are few studies that assess testicular function after scrotal reconstruction, and most of them were subjective [16].

The pudendal thigh flap is an axial and sensate fasciocutaneous flap based on the terminal branches of the superficial perineal artery, which is the continuation of the internal pudendal artery (below the urogenital diaphragm), which is a major branch of internal iliac artery; the superficial perineal artery after giving off the transverse perineal artery continues as the posterior scrotal artery. It anastomoses with the circumflex femoral artery and the pudendal artery interior branches of the obturator artery, thus extending the vascular territory to the femoral triangle; the course of the superficial perineal nerve closely follows the branches of the superficial perineal artery and vein [10]. The neurovascular pudendal thigh flap from this vascular territory was first described by Wee and Joseph for vaginal reconstruction [17].

In the present study, 13 patients had skin loss secondary to Fournier's gangrene, trauma, and animal bite. These patients had been prepared by thorough multiple debridements and daily dressings until the scrotal wound became clean and ready for soft tissue coverage. During this period, wound culture, semen analysis, and hormonal analysis (serum testosterone, FSH, and LH) were done. Then wound coverage was done using bilateral pudendal thigh flap in seven cases and unilateral in six cases.

The early results are excellent with good skin quality and testicular support, with minimal early complications (two cases show flap congestion, no flap necrosis, one case of donor wound disruption, two cases with hematoma, and three cases with wound infection). All complications were controlled and did not affect flap survival. This is in agreement with Iwuagwu *et al.* [8] who stated that the pudendal thigh flap provides a skin of good quality and good support for already inflamed testes. The skin and underlying subcutaneous fat provide a good cushioning effect for the testis that gives an advantage over skin grafts. This may be especially helpful for young active patients [8].

On long-term follow-up, the shape, color, the hang or ptosis of the scrotum, and the patient gate look natural as we had noticed in these patients. All our patients were psychologically satisfied regarding the reconstruction. The donor site was closed primarily with minimal morbidity and hidden scar, and all patients in the present study have regained some protective sensation.

The dependent and external position of the reconstructed scrotum may have similar thermoregulatory effects on the testes as that of normal scrotum, this can be proved by the results of semen analysis before surgery compared with the results 6 months and 1 year after surgery which show nonsignificant changes in all parameters. Moreover, in the assessment of hormonal levels, we noticed nonsignificant changes regarding serum testosterone, FSH, and LH levels before surgery compared with 6 months and 1 year after surgery. This is in agreement with Agarwal [16] who showed normal testicular function by 6 months after implantation of testis in thigh by testicular biopsy, and Wang *et al.* [17] showed that spermatogenesis was not altered in the early stage but was abnormal after 2 years, but he showed in another study that spermatogenesis can be improved by thin trimming of scrotal flap [18]. Murakami *et al.* [19] showed that thin flap or placing the testis just beneath the skin may be a better method for preserving spermatogenesis in these patients. In the present study, we found nonsignificant changes in the semen analysis after 6 months and 1 year of surgery.

Conclusion

Posteriorly based neurovascular pudendal flap provides the following advantages for scrotal reconstruction: it forms a safe, simple, and single-stage technique that

provides constant coverage which is ideal for scrotal defects with good esthetic results; the donor area is closed primarily with minimal morbidity; the scar is hidden in a natural crease; flap dissection is easier and more accessible than with other techniques; and finally, thin skin coverage of the testes does not affect spermatogenesis and hormonal function of the testis.

Financial support and sponsorship

Nil.

Conflicts of interest

There are no conflicts of interest.

References

- 1 Hallock GG. Scrotal reconstruction following Fournier gangrene using the medial circumflex femoral artery perforator flap. *Ann Plast Surg* 2006; 57:333–335.
- 2 Hesselheldt-Nielsen J, Bang-Jensen E, Riegels-Nielsen P. Scrotal reconstruction after Fournier's gangrene. *Ann Plast Surg* 1986; 17:310–316.
- 3 Gudaviciene D, Milonas D. Scrotal reconstruction using thigh pedicled flaps after scrotal skin avulsion. *Urol Int* 2008; 81:122–124.
- 4 Kwon EO, Pareek G, Fracchia JA, Armenakas NA. Scrotal reconstruction using rapid intraoperative tissue expansion: a preliminary report. *J Urol* 2008; 179:207–209.
- 5 Hsu H, Lin CM, Sun TB, Cheng LF, Chien SH. Unilateral gracilis myofasciocutaneous advancement flap for single stage reconstruction of scrotal and perineal defects. *J Plast Reconstr Aesthet Surg* 2007; 60:1055–1059.
- 6 Aydin T, Feyzi K, Tayfun T, Berna T. Reconstruction of wide scrotal defect using groin fasciocutaneous island flap combined with a strip of deep fascia. *J Plast Reconstr Aesthet Surg* 2010; 63:1394–1395.
- 7 Murakami M, Hyakusoku H, Matsuzawa I, Kondo Y, Akimoto M. Scrotal reconstruction with a thinned flap based on both inferior epigastric arteries. Case report. *Scand J Plast Reconstr Surg Hand Surg* 2001; 35:99–101.
- 8 Iwuagwu FC, Mopuri N, Fitzgerald O'Connor E. Scrotal reconstruction with modified pudendal thigh flaps. *Br J Plast Surg* 2015; 63:278–283.
- 9 Hallock GG. Scrotal reconstruction following Fournier's gangrene using the medial thigh fasciocutaneous flap. *Ann Plast Surg* 1990; 24:86–90.
- 10 Cormack GC, Lamberty BGH. External genitalia and perineum in the arterial anatomy of skin flaps, 2nd ed. Edinburgh: Churchill Livingstone; 1994.
- 11 Wee JTK, Joseph VT. New technique in vaginal reconstruction using neurovascular pudendal thigh flap: a preliminary report. *Plast Reconstr Surg* 1998; 83:701–709.
- 12 David AC, William CH. Temperature determination of the thigh with regard to burying the traumatically exposed testis. *J Urol* 1956; 76:436–437.
- 13 Yii NW, Niranjana NS. Lotus petal flaps in vulvo-vaginal reconstruction. *Br J Plast Surg* 1996; 49:547–554.
- 14 Ferreira PC, Reis JC, Amarante JM, Silva AC, Pinho CJ, Oliveira IC, da Silva PN. Fournier's gangrene: a review of 43 reconstructive cases. *Plast Reconstr Surg* 2007; 119:175–184.
- 15 Maharaj D, Naraynsingh V, Perry A, Ramdass M. The scrotal reconstruction using the 'Singapore sling'. *Plast Reconstr Surg* 2002; 110:203–205.
- 16 Agarwal P. Scrotal reconstruction: our experience. *J Surg Pak (Int)* 2012; 17:32–35.
- 17 Wang D, Zheng H, Deng F. Spermatogenesis after scrotal reconstruction. *Br J Plast Surg* 2003; 56:484–488.
- 18 Wang D, Wei Z, Sim G, Luo Z. Thin timing of the scrotal. Reconstruction flap: long term follow-up, shows reversal of spermatogenesis arrest. *J Plast Reconstr Aesthet Surg* 2009; 62:455–456.
- 19 Murakami M, Hyakusoku H, Matsuzawa I, Kondon Y, Akimoto M. Scrotal reconstruction with a thinned flap based on both inferior epigastric arteries. Case report. *Scand J Plast Reconstr Surg Hand Surg* 2001; 35:99–101.