

Is local injection of methylene blue allow safe parathyroid gland preservation during total thyroidectomy?

Ahmed Zidan, Taher H. Elwan, Ahmed M. Nawar

^aDepartment of General Surgery, Faculty of Medicine, Benha University, Benha, Egypt,

^bDepartment of General Surgery, Faculty of Medicine, Al Baha University, Kingdom of Saudi Arabia

Correspondence to Ahmed M. Nawar, MD, Department of General Surgery, Faculty of Medicine, Benha University, Benha, Qalubia, 13511, Egypt. Tel: 002 01068077332; e-mail: nowar79@yahoo.com

Received 11 December 2018

Accepted 7 January 2019

The Egyptian Journal of Surgery 2019, 38:306–312

Objectives

To evaluate surgical and biochemical outcomes of local methylene blue [total thyroidectomy (TT)-MB] injection during subcapsular thyroidectomy in preservation of parathyroid glands (PTGs).

Patients and methods

The study include 88 patients divided into two groups. The study group (GP) included 44 patients assigned to TT-MB and control GP included 44 patients who underwent conventional total thyroidectomy. All patients underwent clinical and radiological workup and estimation of serum parathyroid hormone (PTH) and serum total and ionized calcium. Operative procedure entails injection of 1–3 ml MB (0.8 mg/ml) in thyroid subcapsular layer, and the procedure was repeated till completion of thyroidectomy.

Study outcomes

The study outcomes included frequency of PTG localization, frequency and extent of hypoparathyroidism (HPT) as judged by estimated serum PTH on first and sixth postoperative day (POD1 and POD6) in relation to preoperative level, and the frequency and extent of disturbed serum calcium levels.

The outcomes in the cases with TT-MB were compared with the outcomes of the control group patients, who had TT without the use of MB.

Results

Dissection was easy in 38 (86.36%) cases and more difficult in six (13.63%) cases. One study and five control patients had HPT on POD6, and no study patient but two control patients continued experiencing HPT, with significant difference in favor of study group.

Conclusion

Subcapsular MB injection during subcapsular thyroidectomy facilitates safe thyroid dissection sparing PTG with easy successful dissection rate of 86.36%. Despite decreased serum PTH, its extent was minimal, and only one patient developed transient HPT.

Keywords:

hypocalcemia, hypoparathyroidism, local injection, methylene blue, subcapsular thyroidectomy

Egyptian J Surgery 38:306–312

© 2019 The Egyptian Journal of Surgery

1110-1121

Introduction

Total thyroidectomy (TT) is a worldwide treatment option for multiple thyroid disease states [1] and is the recommended management for thyroid carcinoma [2]. However, the main barriers for short-stay TT are hemorrhage, bilateral recurrent laryngeal nerve palsy causing respiratory compromise, and hypocalcemia [3].

Parathyroid gland (PTG) failure is the most common postoperative (PO) complication after TT [4] and permanent hypoparathyroidism (HPT) is its problematic long-term complication [5] with an incidence varying from 30 to 60%, and this causes significant morbidity and increased costs [6]. Recently, PO subclinical HPT was documented as a more common coincidence, even with the use of harmonic scalpel for dissection instead of classic dissection [7].

Measurements of serum total and ionized calcium were strongly recommended in immediate and long-term follow-up of TT patients, but ionized calcium is more reliable than total calcium measurement in the immediate PO period [8]. Parathyroid hormone (PTH) assay performed 1-h after TT can be helpful in predicting PO hypocalcemia and in decision making for safe discharge of thyroidectomy patients as day-care cases [9], which is the target of modern surgery [4].

Methylene blue (MB) is used for tissue staining for identification or localization during thyroid surgical procedures [10]. MB marking during TT allowed

This is an open access journal, and articles are distributed under the terms of the Creative Commons Attribution-NonCommercial-ShareAlike 4.0 License, which allows others to remix, tweak, and build upon the work non-commercially, as long as appropriate credit is given and the new creations are licensed under the identical terms.

marking of the plane of dissection and better identification of thyroid subcapsular plane. The wash-out time of PTGs was less than 3 min, but for thyroid glands was more than 15 min; the differences in time are owing to the lymphovascular pattern of the tissues. The lymphovascular structure of PTGs is extremely dense. This peculiarity of the tissue is vital for immediate washout of MB staining [11].

Hypothesis

As the position of the PTG is variable, especially the inferior ones, the use of injections in the fascia spaces is important to delineate the thyroid from the parathyroid. Local injection of saline-MB in the interface plane between capsule of the thyroid gland and the expected PTG allows safe dissection without injuring the PTG.

Setting

The study was performed at University Hospital, Benha, Egypt, and King Fahd Hospital, Al Baha, Kingdom of Saudi Arabia.

Patients and methods

The study includes 88 patients divided into two groups. The study GP include 44 patients assigned for TT-MB and control GP include 44 patients who underwent conventional total thyroidectomy (CTT).

The study protocol was approved by the Local Ethical Committee, and only patients who signed written informed consents were enrolled in the study. The current study was conducted from January 2013 till January 2018. Patients prepared for TT without lymph node dissection were enrolled in the study. Exclusion criteria included carcinoma or suspicious of carcinoma, recurrent thyroid enlargement, any condition associated with disturbed serum calcium, and pregnancy. Moreover, patients who had vitamin D insufficiency, with serum level of less than 75 nmol/l [12] were excluded from the study.

All patients eligible for inclusion underwent complete clinical examination, indirect laryngoscopy for assessment of vocal cord mobility, radiological workup, and laboratory investigations including complete blood count, fasting and postprandial blood glucose, liver and kidney function tests, and serum PTH, calcium (total and ionized), and 25-OH vitamin D levels.

Preparation of methylene blue solution

Sterile MB solution 2% was used for preparation of fluid to be injected; 20 ml of 2% solution was diluted in

500 ml of 0.9% normal saline to prepare a solution of 0.8 mg/ml. With the use of a sterile 3-ml syringe with a 26-G needle, 3 ml of the prepared solution will be ready for injection.

Operative procedure

One to three milliliters of MB was injected in the plane between thyroid capsule and the yellow fat enclosing the PTG, which induces swelling in the tissue and spacing between the yellow fatty tissue and the thyroid gland (Fig. 1a–c). Then, dissection was performed with bipolar electrocautery along the margin of the thyroid gland on the marked blue line (Fig. 1d) until the superior PTGs were exposed and visualized. This means that all yellow tissue is separated from the capsule of the gland. The procedure was repeated till completion of subcapsular thyroidectomy, and wound was closed with bilateral suction drain (Fig. 1a–d).

Study outcome

Primary outcome

Frequency of intraoperative PTG localization, frequency and extent of HPT as judged by estimated serum PTH on first and sixth postoperative day (POD1 and POD6) in relation to preoperative level, and frequency and extent of disturbed serum total and ionized calcium were estimated on POD1 and POD6. HPT was defined as serum PTH of less than 10 pg/ml on POD1 or POD2 [13] and was considered transient if normal serum PTH level was regained [14]. The obtained outcomes in the patients with TT-MB were compared with outcome of a similar number of patients who had TT performed conventionally without the use of dye as a guide, as a control group.

Study power

Considering the probability of type-I error (alpha cut-off) at 5%, probability of type-II error (beta cut-off) at 20%, and the incidence of HPT after CTT being 17.5% [15], the calculated number of patients/groups must be 40 [16].

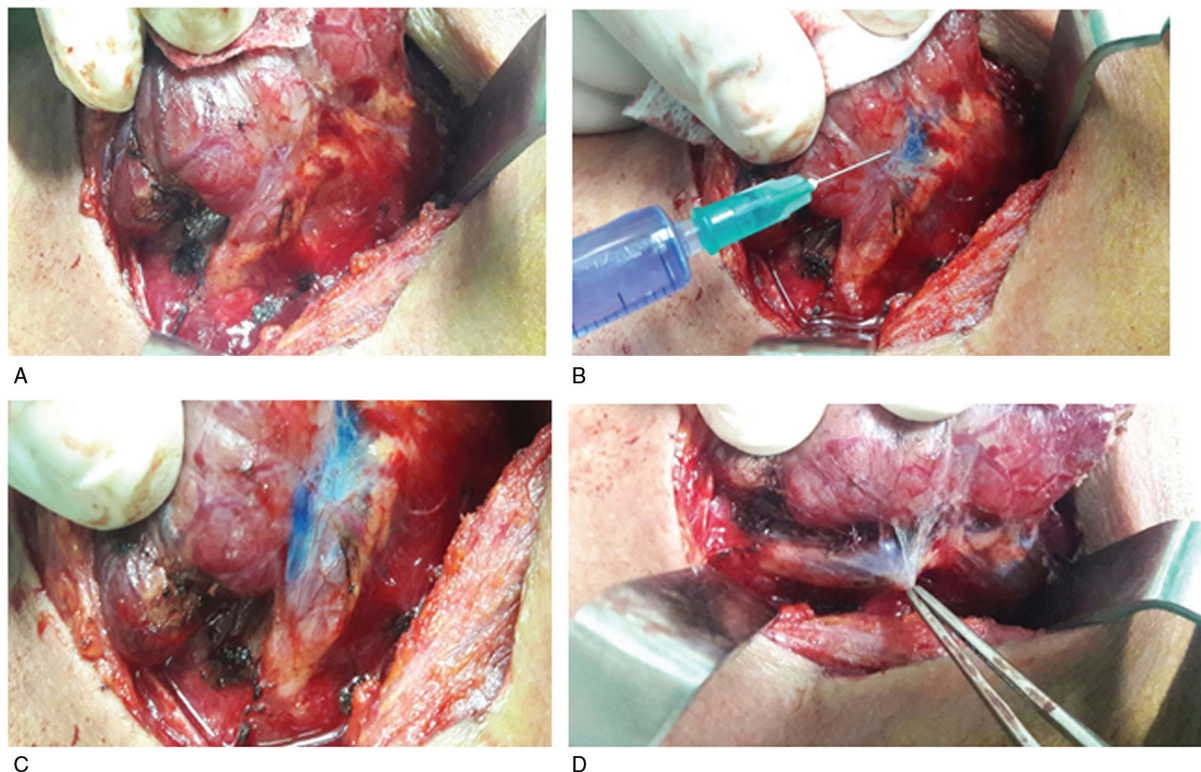
Statistical analysis

Obtained data were presented as mean±SD. Results were analyzed using paired *t* test and one-way analysis of variance test. Statistical analysis was conducted using the IBM SPSS (version 23, 2015, IBM corporation, Chicago, USA) for Windows statistical package. *P* value less than 0.05 was considered statistically significant.

Results

MB injection allowed proper marking of the plane of dissection and identification of the thyroid subcapsular

Figure 1



(a) Mobilization of upper pole of the gland, (b) subcapsular injection of MB dye, (c) identification of the plane between TG and PTG, and (d) completion of dissection with PTG preservation. MB, methylene blue; PTG, parathyroid gland; TG, thyroid gland.

Table 1 Patients' demographic data

Data	Control	Study	<i>P</i> value
Age (years)	59.1±3.5	58.8±3.1	0.711
Sex (male : female)	27 : 17	23 : 21	0.389
BMI (kg/m ²)	27.6±3.6	28.6±2.6	0.167

Data are presented as mean±SD. *P* value indicates the significance of difference between both groups.

plane perfectly, with easy satisfying dissection and PTG localization in 38 (86.1%) cases, whereas dissection was more difficult in six (13.9%) cases. However, PTG localization was more difficult in 13 (29.5%) cases of the control group (Table 1).

Serum total and ionized calcium levels and the ionized/total calcium ratio showed nonsignificant differences between both groups at preoperative, POD1, and POD6 estimations. However, POD1 serum total calcium levels were significantly lower in patients of both control ($P=0.004$) and study ($P=0.032$) groups compared with preoperative levels. At POD6, serum total calcium levels were lower compared with preoperative ($P=0.004$ and 0.084) and POD1 ($P=0.209$ and 0.164) in control and study patients, respectively. Estimated serum ionized calcium level in patients of study group showed nonsignificant difference between the three samples ($P=0.069$ and

0.526 vs. preoperative and $P=0.285$ vs. POD1 level). On the contrary, in the control patients, POD1 levels were significantly lower ($P=0.007$) than preoperative levels, whereas POD6 levels were nonsignificantly lower than preoperative ($P=0.526$) and POD1 ($P=0.285$) estimates. Consequently, ionized/total calcium ratio showed nonsignificant difference between the three samples of patients of each group (Table 2).

Preoperative serum PTH showed nonsignificant ($P=0.344$) difference between patients of both groups. POD1 serum PTH levels significantly ($P<0.001$) decreased in patients of both groups compared with preoperative levels, with significantly ($P=0.014$) lower levels in control versus study patients. Moreover, the percentage of decrease in PTH levels on POD1 was significantly ($P=0.007$) lower in study versus control patients. On POD6, serum PTH levels were reincreased in all patients but were still significantly lower compared with preoperative level ($P<0.001$). POD6 were significantly higher compared with POD1 levels in control ($P<0.001$) and study ($P=0.009$) patients. The percentage of decreased PTH level at POD6, in relation to preoperative level, was significantly lower in patients of control and study groups ($P<0.001$ and 0.007 , respectively),

with significantly lower percentage of decrease in study versus control patients ($P=0.013$) (Table 2 and Fig. 2).

On POD1, estimated serum PTH defined HPT in 13 patients: 11 in the control and two in the study group, with significantly lower frequency in study versus

control group ($P=0.033$). On POD6, six patients were still hypoparathyroid: five in control and only one in study group, with significantly ($P=0.048$) lower frequency in favor of the study group (Fig. 3). Throughout the follow-up period, four of these six hypothyroid patients, one in study and three in control group, regained their serum PTH, whereas the remaining two control patients still experienced hypothyroidism.

Table 2 Laboratory findings of patients of both groups estimated at first postoperative day and sixth postoperative day compared to preoperative estimates

	Control	Study	P value
Total Ca level (mg/dl)			
Preoperative	11.41±2.93	11.63±2.22	0.699
POD1	10.65±3.18*	11.31±2.75*	0.303
POD6	11±2.71	11.53±2.15*	0.311
Ionized Ca level (mg/dl)			
Preoperative	4.75±0.37	4.78±0.42	0.687
POD1	4.65±0.42*	4.7±0.57	0.072
POD6	4.71±0.55	4.77±0.67	0.666
Ionized/total Ca ratio			
Preoperative	0.456±0.171	0.429±0.102	0.368
POD1	0.499±0.227	0.453±0.18	0.291
POD6	0.468±0.183	0.429±0.106	0.221
PTH (pg/dl)			
Preoperative	35.2±9.7	37±8.35	0.344
POD1			
Level	22.93±14.36*	30.12±12.61*	0.014
% of change	36.67±30.53	20.17±25.43	0.007
POD6			
Level	29.14±11.52*†	33.65±8.68*†	0.041
% of change	18.24±20.4*	9.65±9.39*	0.013

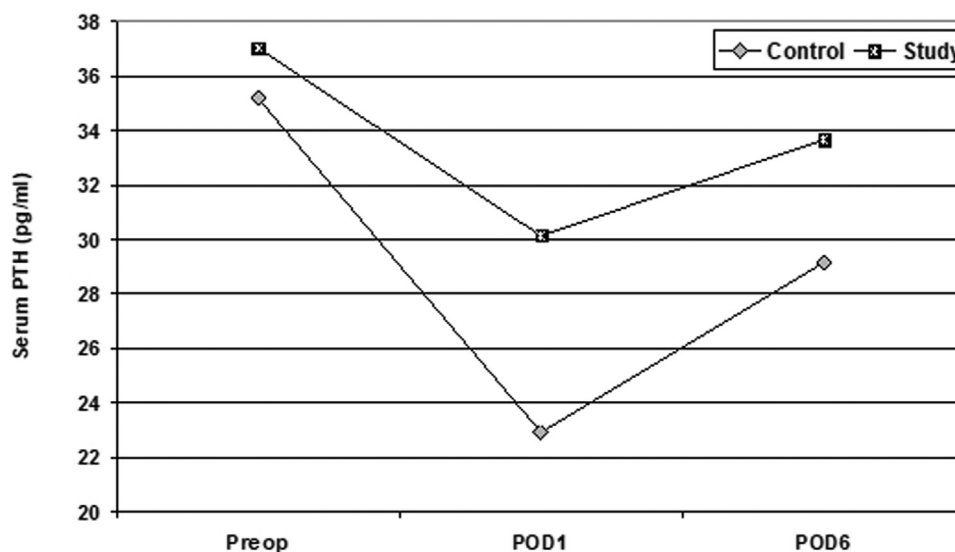
Data are presented as mean±SD. Ca, calcium; POD, postoperative day; PTH, parathyroid hormone. P value indicates the significance of difference between both groups. *Significance of difference versus preoperative value. †Significance of difference versus POD1 value.

Discussion

CTT, when indicated, carries a definite risk for injury of PTG. The outcome of 44 patients who had CTT (control group) showed the development of HPT in 11 (25%) patients, who developed manifest HPT with serum PTH of less than 10 pg/ml on POD1, with concomitant significantly decreased serum total and ionized calcium in relation to preoperative estimates, till POD6 whenever six regained serum PTH of more than 10 pg/ml and were maintained on calcium supplemental therapy (Ca-ST) till regeneration of near normal calcium and PTH levels. Two of the other five patients continued having HPT, comprising 11.8% among patients who developed manifest HPT, whereas three patients had recovered.

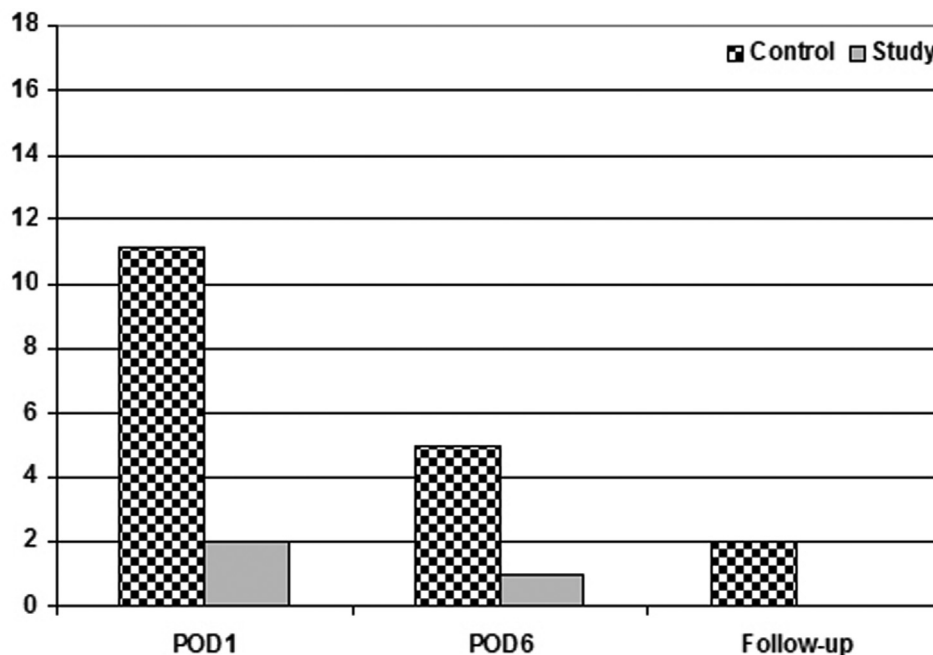
These findings go in hand with that recently documented by Vasileiadis *et al.* [17] who retrospectively studied files of 2556 patients who underwent CTT and reported incidental parathyroidectomy (IP) in 18.3% with significantly higher risk of PO biochemical and symptomatic

Figure 2



Mean POD1 and POD6 serum PTH levels estimated in patients of both groups compared with preoperative levels. POD, postoperative day; PTH, parathyroid hormone.

Figure 3



Frequency of patients who developed HPT. HPT, hypoparathyroidism.

hypocalcemia than non-IP patients and concluded that patients with malignancy especially with tumor more than 10 mm, extrathyroidal extension, and lymph node metastasis are at higher risk of IP and PO symptomatic hypocalcemia, and these patients should be adequately treated.

Moreover, Su *et al.* [18] reported that auto-transplantation is an effective strategy for restoration of PTG function, but transient HPT is positively correlated with the number of auto-transplanted PTG during TT. Moreover, Luo *et al.* [19] retrospectively found PTG remaining *in situ* after CTT was significantly inversely associated with development of transient and/or protracted HPT and PO hypocalcemia and was identified as an independent risk factor for these events. On contrary to Su *et al.* [18], Luo *et al.* [19] reported that auto-transplantation of PTG would not affect serum calcium level in the long term.

All patients developed manifest HPT, control and study, and received Ca-ST started on POD1, in line with early use of Ca-ST. Previous studies have documented that PO calcium supplementation effectively prevents symptomatic [20] and biochemical hypocalcemia [21] after TT and is proved to be a safe and cost-effective method that can be applied without routine laboratory assessment [20–22].

Subcapsular thyroidectomy with TT-MB marking, relied on local injection of diluted MB to provide

0.8 mg/ml normal saline, and only 1–3 ml was injected per site. Moreover, MB injected in the subcapsular space allowed excision of tissues retaining MB with the excised thyroid gland, this minimal dose and local injection of MB had safeguarded against documented complications secondary to MB systemic absorption [23,24], which were documented with the use of larger doses [25] or intravenous route [25,26] and also points to safety of the concentration used, as it coincided with doses documented in literature [27].

TT-MB is associated with acceptable preservation of serum calcium, total and ionized, and PTH, and despite the detected decreased levels in comparison with preoperative levels, the extent of decrease was lower than in patients of the control group. Moreover, two patients developed manifest HPT on POD1, but only one patient failed to restore normal PTH level on POD6 but did not develop permanent HPT, with significant difference compared with control patients. These data point to the possibility of evaluation of outcome of TT using a combination of estimation of serum calcium and PTH. Similarly, Sitges-Serra *et al.* [27] reported that combining both serum calcium and PTH estimations may guide medical treatment and monitoring of post-thyroidectomy prolonged HPT and predicts the likelihood of recovery of the parathyroid function with more than 90% accuracy.

The MB marking during TT allowed marking of the plane of dissection and perfect identification of thyroid subcapsular plane, with easy satisfying dissection in 38 (86.1%) cases and concomitant faster surgery. Such success rate could be attributed to the marking color that allowed easier visualization of the plane of dissection, and to the space-occupying effect of the injected fluid which allowed opening of the plane for dissection.

These data go in hand with studies previously used MB during thyroidectomy, where Sari *et al.* [11] reported different wash-out times for MB after its spraying during thyroidectomy where recurrent laryngeal nerve and arteries were not stained, PTG were washed out of the blue stain within 3 min. Thyroid tissue wash-out time was more than or equal to 15 min, and perithyroid muscles, tendinous, and lipid structures wash-out time was more than or equal to 25 min. It concluded that the differential wash-out time of MB allowed safe preservation of PTG and recurrent laryngeal nerves during dissection for thyroidectomy. Moreover, Candell *et al.* [28] and Hacıyanlı *et al.* [29] found blue dye injection is a safe and effective method of localizing PTG. Moreover, Salman *et al.* [30] documented that preoperative intra-arterial MB infusion appears to be an effective and safe method for localization of ectopic mediastinal parathyroid adenomas and allows rapid identification during thoroscopic resection. Recently, Hillary *et al.* [31] reported that PTG especially enlarged glands fluoresce from MB more intensely than thyroid glands, and this auto-fluorescence may aid PTG detection. In line with the space-occupying effect of injected fluid, Choi *et al.* [32] reported that procedure of subcapsular saline injection effectively spared the PTG during thyroidectomy and compared with non-subcapsular saline injection patients and significantly reduced the frequency of transient and permanent HPT.

Conclusion

Local MB subcapsular injection during TT facilitates safe thyroid dissection sparing PTG with easy successful dissection rate of 86.1%. Despite decreased serum PTH, its extent was minimal, and only two patients developed manifest HPT, but no patient developed permanent HPT.

Financial support and sponsorship

Nil.

Conflicts of interest

There are no conflicts of interest.

References

- Cirocchi R, Trastulli S, Randolph J, Guarino S, Di Rocco G, Arezzo A, *et al.* Total or near-total thyroidectomy versus subtotal thyroidectomy for multinodular non-toxic goitre in adults. *Cochrane Database Syst Rev* 2015; 8:CD010370.
- Macedo FI, Mittal VK. Total thyroidectomy versus lobectomy as initial operation for small unilateral papillary thyroid carcinoma: a meta-analysis. *Surg Oncol* 2015; 24:117–122.
- Perera AH, Patel SD, Law NW. Thyroid surgery as a 23-hour stay procedure. *Ann R Coll Surg Engl* 2014; 96:284–288.
- Lorente-Poch L, Sancho JJ, Ruiz S, Sitges-Serra A. Importance of in situ preservation of parathyroid glands during total thyroidectomy. *Br J Surg* 2015; 102:359–367.
- Ito Y, Kihara M, Kobayashi K, Miya A, Miyauchi A. Permanent hypoparathyroidism after completion total thyroidectomy as a second surgery: How do we avoid it? *Endocr J* 2014; 61:403–408.
- Dedivitis RA, Aires FT, Cernea CR. Hypoparathyroidism after thyroidectomy: prevention, assessment and management. *Curr Opin Otolaryngol Head Neck Surg* 2017; 25:142–146.
- Papavramidis TS, Anastasiou O, Pliakos I, Kotsovolis G, Panidis S, Michalopoulos A. Parathyroid function after total thyroidectomy: a randomized clinical trial concerning the influence of the surgical technique. *Endocr Pract* 2018; 24:150–155.
- Tartaglia F, Giuliani A, Sgueglia M, Patrizi G, Di Rocco G, Blasi S, *et al.* Is ionized calcium a reliable predictor of hypocalcemia after total thyroidectomy? A before and after study. *G Chir* 2014; 35:27–35.
- Riaz U, Shah SA, Zahoor I, Riaz A, Zubair M. Validity of early parathyroid hormone assay as a diagnostic tool for sub-total thyroidectomy related hypocalcaemia. *J Coll Physicians Surg Pak* 2014; 24:459–462.
- Patel HP, Chadwick DR, Harrison BJ, Balasubramanian SP. Systematic review of intravenous methylene blue in parathyroid surgery. *Br J Surg* 2012; 99:1345–1351.
- Sari S, Aysan E, Muslumanoglu M, Ersoy YE, Bektasoglu H, Yardimci E. Safe thyroidectomy with intraoperative methylene blue spraying. *Thyroid Res* 2012; 5:15.
- Stroud ML, Stilgoe S, Stott VE, Alhajian O, Salman K. Vitamin D – a review. *Aust Fam Physician* 2008; 37:1002–1005.
- Lombardi CP, Raffaelli M, Princi P, Santini S, Boscherini M, De Crea C, *et al.* Early prediction of postthyroidectomy hypocalcemia by one single iPTH measurement. *Surgery* 2004; 136:1236–1241.
- Thomusch O, Machens A, Sekulla C, Ukkat J, Lippert H, Gastinger I, Dralle H. Multivariate analysis of risk factors for postoperative complications in benign goiter surgery: prospective multicenter study in Germany. *World J Surg* 2000; 24:1335–1341.
- Bai YC, Cheng RC, Hong WJ, Ma YH, Qian J, Zhang JM. Thyroid lymphography: a new clinical approach for protecting parathyroid in surgery. *Zhonghua Er Bi Yan Hou Tou Jing Wai Ke Za Zhi* 2013; 48:721–725.
- Rosner B. *Fundamentals of biostatistics*. 7th ed. Boston, MA: Brooks/Cole 2011.
- Vasileiadis I, Charitoudis G, Vasileiadis D, Kykalos S, Karatzas T. Clinicopathological characteristics of incidental parathyroidectomy after total thyroidectomy: the effect on hypocalcemia. A retrospective cohort study. *Int J Surg* 2018; 55:167–174.
- Su A, Gong Y, Wu W, Gong R, Li Z, Zhu J. Does the number of parathyroid glands autotransplanted affect the incidence of hypoparathyroidism and recovery of parathyroid function? *Surgery* 2018; S0039-6060:30928–5.
- Luo H, Zhao W, Yang H, Su A, Wang B, Zhu J. In situ preservation fraction of parathyroid gland in thyroidectomy: a cohort retrospective study. *Int J Endocrinol* 2018; 2018:7493143.
- Langner E, Tincani AJ, Negro AD. Use of prophylactic oral calcium after total thyroidectomy: a prospective study. *Arch Endocrinol Metab* 2017; 61:447–454.
- Singer MC, Bhakta D, Seybt MW, Terris DJ. Calcium management after thyroidectomy: a simple and cost-effective method. *Otolaryngol Head Neck Surg* 2012; 146:362–365.
- Fukui S, Endo Y, Hirayama K, Taniyama H, Kadosawa T. Identification and preservation of the parathyroid gland during total thyroidectomy in dogs with bilateral thyroid carcinoma: a report of six cases. *J Vet Med Sci* 2015; 77:747–751.
- Shopes E, Gerard W, Baughman J. Methylene blue encephalopathy: a case report and review of published cases. *AANA J* 2013; 81:215–221.

- 24 Lieberman ED, Thambi R, Pytynia KB. Methylene blue and parathyroid adenoma localization: Three new cases of a rare cutaneous complication. *Ear Nose Throat J* 2016; 95:70–72.
- 25 Kadoya T, Kinoshita Y, Shiraishi M, Uehara H, Yamamoto T, Suetsugu K. Seven cases of parathyroidectomy for secondary hyperparathyroidism using methylene blue: suggestion for the method of methylene blue infusion. *Masui* 2014; 63:862–865.
- 26 Antakia R, Gayet P, Guillermet S, Stephenson TJ, Brown NJ, Harrison BJ, Balasubramanian SP. Near infrared fluorescence imaging of rabbit thyroid and parathyroid glands. *J Surg Res* 2014; 192:480–486.
- 27 Sitges-Serra A, Gómez J, Barczynski M, Lorente-Poch L, Iacobone M, Sancho J. A nomogram to predict the likelihood of permanent hypoparathyroidism after total thyroidectomy based on delayed serum calcium and iPTH measurements. *Gland Surg* 2017; 6(Suppl 1):S11–S19.
- 28 Candell L, Campbell MJ, Shen WT, Gosnell JE, Clark OH, Duh QY. Ultrasound-guided methylene blue dye injection for parathyroid localization in the reoperative neck. *World J Surg* 2014; 38:88–91.
- 29 Hacıyanlı M, Koruyucu MB, Erdogan NK, Dere O, San E, Kumkumoglu Y, *et al.* Successful localization of abnormal parathyroid gland using ultrasound-guided methylene blue dye injection in the reoperative neck. *Indian J Surg* 2015; 77(Suppl 3):1094–1097.
- 30 Salman R, Sebaaly MG, Wehbe MR, Sfeir P, Khalife M, Al-Kutoubi A. Preoperative localization of mediastinal parathyroid adenoma with intra-arterial methylene blue. *Cardiovasc Intervent Radiol* 2017; 40:953–956.
- 31 Hillary SL, Guillermet S, Brown NJ, Balasubramanian SP. Use of methylene blue and near-infrared fluorescence in thyroid and parathyroid surgery. *Langenbecks Arch Surg* 2018; 403:111–118.
- 32 Choi JY, Yu HW, Bae IE, Kim JK, Seong CY, Yi JW, *et al.* Novel method to save the parathyroid gland during thyroidectomy: Subcapsular saline injection. *Head Neck* 2018; 40:801–807.