

# Double mesh technique (mesh plug and onlay) in repair of lumbar incisional hernia: a novel technique

Gamal Osman, Fady M. Habib, Ahmed M. Sallam, Loay M. Gertallah

Department of General Surgery, Faculty of Medicine, Zagazig University, Zagazig, Egypt

Correspondence to Loay M. Gerallah, MD, PhD, Department of General Surgery, Faculty of Medicine, Zagazig University, Zagazig 44519, 4450, Egypt Tel: +20 122 496 3123; e-mail: loayelhady@gmail.com

Received 3 May 2018

Accepted 19 May 2018

The Egyptian Journal of Surgery 2018, 37:562-568

## Background

Patients having lumbar incisional hernia are presented with a mass in the suprailiac region posteriorly at the site of the previous operation and might be associated with occurrence of pain. Repairing such types of hernias is difficult, and it has high rates of recurrence after operation. There is a plethora of surgical techniques that have been described in performing the lumbar incisional hernia open repair, and it is difficult to detect the best technique of management, and no surgical procedure has been proved to be better than the others.

The aim of this study was to provide a novel, efficient, simple and safe technique in the repair of lumbar incisional hernia and then to evaluate the short-term outcome of applying such technique to solve the recurrence problem.

## Patients and methods

In our study, we have included 20 cases having lumbar incisional hernia and were divided into two groups: group 1 contained 10 cases that were managed by double-mesh technique and group 2 contained 10 cases that were managed by single mesh.

## Results

We found that putting two meshes is better than a single mesh in the management of lumbar incisional hernia regarding decreasing incidence of postoperative complications ( $P=0.028$ ) and decreasing incidence of postoperative recurrence ( $P=0.020$ ).

## Conclusion

Our double-mesh technique in the management of lumbar incisional hernia is a novel technique, with no intra-abdominal injuries or collections and provides better results without recurrence.

## Keywords:

Double-mesh technique, lumbar hernia, recurrence

Egyptian J Surgery 37:562-568

© 2018 The Egyptian Journal of Surgery

1110-1121

## Introduction

Lumbar hernia is considered a rare hernia that forms less than 1.5% of total hernia incidence Barbette in 1672 first described lumbar hernia, and till date, only 300 cases have been diagnosed and reported. Lumbar hernias occur in the broad anatomic area bounded superiorly by the 12th rib, inferiorly by the iliac crest, medially by the erector spine muscle and laterally by the external oblique muscle [1]. Lumbar hernias are classified into two groups according to etiology: primary and acquired. Primary lumbar hernias are classified into two subtypes according to their primary site: the petit subtype in the inferior lumbar triangle and Grynfeltt subtype in the superior lumbar triangle, which was first described by Grynfeltt in 1866. Acquired lumbar hernias are caused by infection, lumbar region trauma, or previous surgery, which is named lumbar incisional hernias; it usually happens after flank surgery in nephrectomy, iliac bone graft harvest aortic aneurysm repair or latissimus dorsi myocutaneous flap [2]. Lumbar incisional hernias are uncommon

in healthy persons, and there are many factors that are responsible for their occurrence, that is, older age of the patient, nutritional deficiency, chronic debilitating disease, obesity, chronic cough, previous postoperative wound infection, and sepsis [3].

Muscles of the abdominal wall, which include external oblique muscle and internal oblique muscle, rectus abdominis muscle and transversus abdominis, and their overlying skin are supplied by the seventh to eleventh intercostal and subcostal nerves [4].

Proximal intraoperative nerve injury might lead to a defect in the innervation of the abdominal wall muscles, which will lead to a subtype of lumbar hernia [5].

This is an open access journal, and articles are distributed under the terms of the Creative Commons Attribution-NonCommercial-ShareAlike 4.0 License, which allows others to remix, tweak, and build upon the work non-commercially, as long as appropriate credit is given and the new creations are licensed under the identical terms.

Patients who are diagnosed with lumbar incisional hernia are presented by a bulge that is increasing in size posteriorly in the suprailiac area that is located at the site of the previous surgical incision, and it might be associated with occurrence of pain. It will be difficult to repair these hernias, and they have high recurrence rates after surgery [6]. A plethora of surgical approaches have been described for the open surgical repair of lumbar incisional hernia, for example, simple closure, insertion of various rotational musculofascial flap grafts with fixation to bone to secure defect coverage, fascial strip repair, applying synthetic meshes, for example, polypropylene mesh, with muscle flaps in sandwich fashion and free grafts; it is difficult to detect the best approach of surgical management of those hernias, and no procedure has been shown to have clear benefits over the others with low incidence of postoperative recurrence [2,7].

The aim of the work was to provide a novel, efficient, simple and safe technique in the repair of lumbar incisional hernia and then to evaluate the short-term outcome of applying such technique to solve the recurrence problem.

## Patients and methods

### Study design

- (1) Location: we carried out this study in General Surgery Department, Zagazig University Hospitals, after local ethics committee and Institutional Research Board approval.
- (2) Sample size: a total of 20 cases were included in our study, where 10 cases were managed by the double-mesh technique (mesh plug and onlay) and 10 cases were managed by the traditional single mesh.

### Patient's data

#### Inclusion criteria

The following were the inclusion criteria:

- (1) All male and female patients older than 18 years.
- (2) All patients having completely reducible lumbar incisional hernia regardless of comorbidities.

#### Exclusion criteria

The following were the exclusion criteria:

- (1) Cases with complicated lumbar incisional hernia even if with partial irreducibility.
- (2) Lack of consent.
- (3) Cases with incomplete data and those lost to follow-up.

- (4) Patients who are not fit for surgery.

### Preoperative preparation

All patients were subjected to the following:

- (1) Full history taking regarding onset, course, and duration; previously performed operations in details; pulmonary problems; prostatic manifestation; and associated comorbidity.
- (2) Clinical examination with assurance of complete reducibility by palpating the whole margin of the hernia defect in supine or lateral position after reduction of the hernia contents.
- (3) Preoperative investigations:

Complete blood count ECG	Live functions Coagulation profile	Kidney functions Viral hepatitis markers
Plain radiography of chest		Pelviabdominal ultrasound

All patients discovered by history, clinical examination or investigations to have problems such as anemia, benign prostatic hyperplasia, hepatosplenomegaly or chest troubles were referred to the specialist physician to control or to solve these problems preoperatively and to follow them up postoperatively.

### Operative details

The type of anesthesia: general anesthesia with endotracheal intubation.

Position: at first, the patient lies in lateral recumbent position (flank position) with elevating the bridge of the table to allow hyperextension of the site of operation to open the lumbar region, and then before the insertion of the mesh plug and starting the repair, the bridge was reduced till the degree of mild extension of the site of operation. This is done to avoid repair under tension in hyperextension position, and also to allow normal trunk movement postoperatively without feeling tension.

The operative technique.

All patients were divided into two groups:

Group 1 included 10 cases of lumbar hernia, which were managed by the recent two meshes.

The patients were subjected to the following steps:

- (a) Elliptical incision for the old flank scar and then removal of this scar cautiously keeping the underlying peritoneal sac intact.
- (b) Dissection of the upper skin and subcutaneous flap till the lower ribs and the lower flap till the iliac crest.
- (c) Invagination of the sac and feeling the whole edge of the defect and then grasping this edge all around

with multiple or Kocher's forceps and elevating them up to delineate the defect. At this time, the bridge of the table was ordered to be reduced to allow only mild degree of extension to start the repair.

- (d) Polypropylene mesh 15×15 cm was rolled on itself with breadth of ~3–4 cm, and then sutured by vicryl 2/0 by separate full thickness stitches to be fixed in this plug design.
- (e) The designed mesh plug then introduced from one angle of the defect then repair using polydioxanone suture no. 1 started taking one bite to one edge of the defect (4), then bite through the full thickness of the mesh plug, then bite to the other edge completing the repair in continuous locked manner till the whole defect is closed over the mesh plug.
- (f) If weak areas are felt to be found, plication was done for them using prolene suture no. 1.
- (g) Another 15×15 cm or larger mesh according to the size of the defect was fixed onlay by prolene suture 2/0; above: to the lower ribs, below: to the iliac crest, laterally: away from the angle of the defect by 5 cm, and medially: away from the angle of the defect by 5 cm.
- (h) Insertion of subcutaneous suction drain size 18, and then closure of the subcutaneous layer and then the skin by subcuticular suture with three to four interrupted stitches over the line of closure to secure the wound.

Group 2: included 10 cases of lumbar hernia which were managed by the usual single mesh. The patients were subjected to the following steps:

- (a) Elliptical incision of the old flank scar, and then removal of this scar cautiously keeping the underlying peritoneal sac intact.
- (b) Dissection of the upper skin and subcutaneous flap till the lower ribs and the lower flap till the iliac crest.
- (c) Invagination of the sac and feeling the whole edge of the defect, then grasping this edge all around with multiple or Kocher's forceps and elevating them up to delineate the defect. At this time, the bridge of the table was ordered to be reduced to allow only mild degree of extension to start the repair.
- (d) After closure of the defect by continuous and interrupted sutures, onlay polypropylene mesh 15×15 cm mesh was fixed over the sheath.
- (e) Insertion of subcutaneous suction drain size 18 then closure of the subcutaneous then the skin by subcuticular suture with three to four interrupted stitches over the line of closure to secure the wound.

### Postoperative follow-up

- (1) All patients were followed up in the early postoperative period for the following:
  - (a) Length of hospital stay (1–2 days).
  - (b) Wound seroma or infection.
  - (c) Ischemia of the flaps and wound dehiscence.
  - (d) Deep vein thrombosis and chest condition.
  - (e) Postoperative pain.
- (2) All patients were followed up monthly for 6 months for recurrence.
- (3) Ultrasound over the site of operation by superficial probe was requested for all patients at the third month after operation to detect recurrence.

### Statistical analysis

Data were analyzed using statistical package for the social sciences for windows version 20.0 (SPSS Inc., Chicago, Illinois, USA). Continuous variables were written as mean±SD and the categorical variables were described as a number (percentage). Percentage of categorical variables were compared using  $\chi^2$ -test or Fisher's exact test when appropriate. Mann–Whitney *U*-test was used to compare two groups of non-normally distributed data. All tests were two sided. *P* less than 0.05 was considered statistically significant.

## Results

### Preoperative results

Main features and clinical data of our patients are included in Tables 1 and 2. Group 1 included 10 patients, comprising 80% males and 20% females. Group 2 included 10 patients, comprising 60% males and 40% females. The mean age of the patients included in both groups were 39.73±9.07 and 37.66±7.80 years, respectively.

There were no statistically significant differences between both groups regarding age or sex of the patients, cause of the operation, presence of comorbid conditions, postoperative oral feeding or time of incisional lumbar hernia presentation (Figs 1 and 2).

### Operative findings

The duration of operation in group 1 that was managed by double mesh was longer than the duration of operation in group 2 and that was statistically significant ( $P<0.001$ ). There were no statistically significant differences between both groups regarding duration of postoperative hospital stay (Table 3).

**Table 1 Main features of our patients**

Basic characteristics	Group 1 (N=10) [n (%)]	Group 2 (N=10) [n (%)]	P value
Sex			
Male	8 (80)	6 (60)	0.269 <sup>‡</sup>
Female	2 (20)	4 (40)	
Age (mean±SD) (years)	39.73 ±9.07	37.66 ±7.80	0.466 <sup>●</sup>
Comorbidity	8 (66.7)	6 (60)	0.705 <sup>‡</sup>
Cause of operation			
Stone extraction	5 (50)	6 (60)	0.687 <sup>‡</sup>
Nephrectomy	3 (30)	2 (20)	
Repair of posterior lumbar hernia	2 (20)	2 (20)	
Postoperative oral feeding (mean±SD) (h)	4.86±1.35	5±1.46	0.775 <sup>●</sup>
6 h	1 (10)	2 (20)	0.964 <sup>‡</sup>
8 h	5 (50)	6 (60)	
9 h	2 (20)	1 (10)	
10 h	2 (20)	1 (10)	

●Mann–Whitney U-test. ‡ $\chi^2$ -Test.

**Table 2 Clinical data of our patients**

Clinical data	Group 1 (N=10) [n (%)]	Group 2 (N=10) [n (%)]	P value <sup>‡</sup>
Precipitating factors	6 (60)	6 (60)	1.000
SSI	2 (20)	3 (30)	1.000
Smoking	4 (40)	1 (10)	0.169
BPH	4 (40)	0 (0)	0.100
Chronic cough	2 (20)	2 (20)	0.215
Chronic constipation	4 (40)	2 (20)	0.651
Number of hernia			
≤2	1 (10)	8 (80)	0.003
>2	9 (90)	2 (20)	
Time of incisional lumbar hernia presentation (months)			
<2	5 (50)	8 (80)	0.058
2–4	3 (30)	1 (10)	
>4	2 (20)	1 (10)	

BPH, benign prostatic hyperplasia; SSI, surgical site infection. ‡ $\chi^2$ -test.

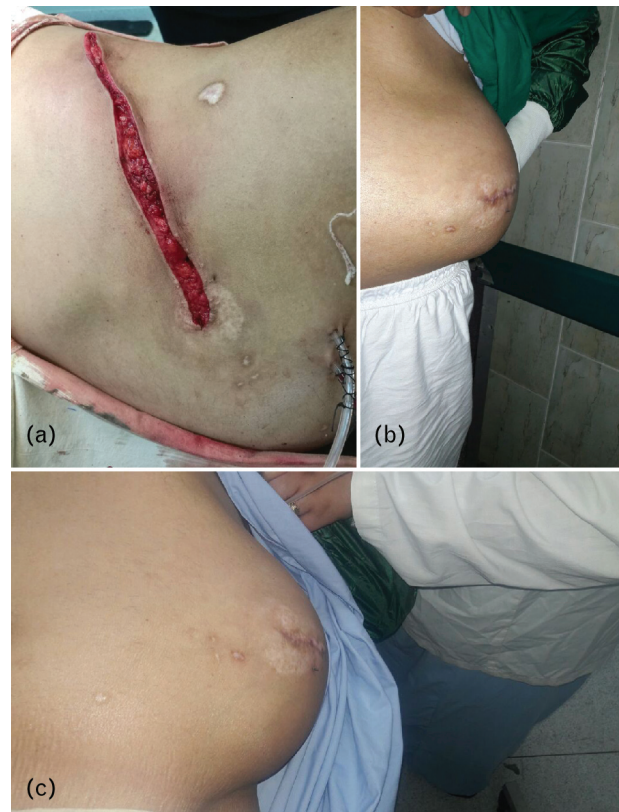**Postoperative results**

We found that putting two meshes is better than single mesh in management of lumbar incisional hernia regarding decreasing incidence of postoperative complications ( $P=0.028$ ) and decreasing incidence of postoperative recurrence ( $P=0.020$ ; Table 4).

**Discussion**

Patients with primary lumbar hernias complain of a palpable swelling that increases in size during coughing, is reducible and becomes absent in the supine position and have abdominal or back pain that is nonspecific. Moreover, lumbar hernias occasionally might lead to intestinal and urinary

**Figure 1**



Preoperative lumbar incisional hernia. (a) A male patient with lumbar incisional hernia; (b) a huge bulge in anterior view; (c) lateral view.

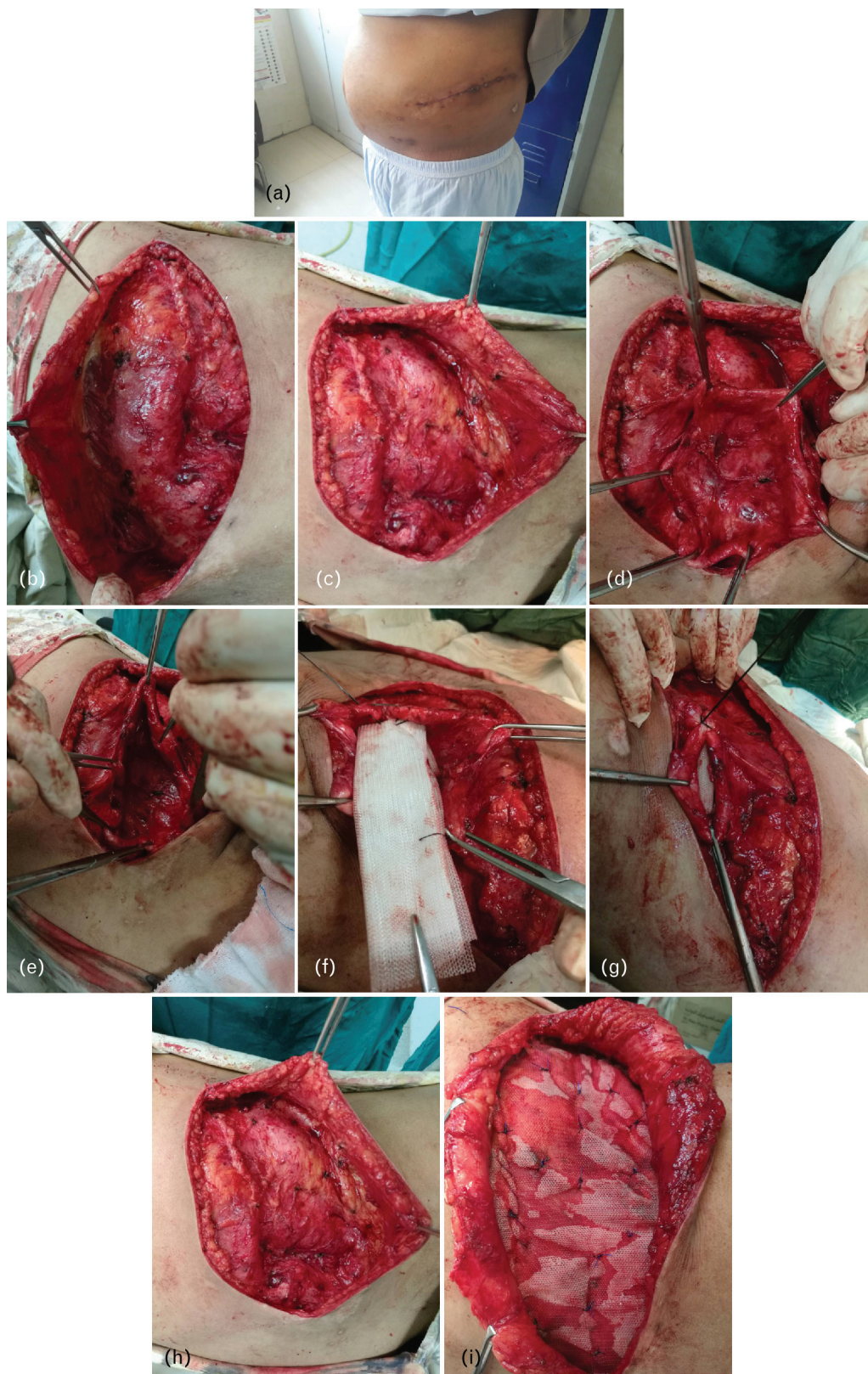
obstruction, which results in hydronephrosis [8]. Most patients are presented as a nonemergency situation, and only 9% are presented with surgical emergencies [9]. Proximal intraoperative nerve injury might lead to a defect in the innervation of the abdominal wall muscles, which will lead to a subtype of lumbar hernia [5].

Surgical management is the only treatment option for such type of hernias, and it is better to be performed early to avoid complications. In the past, majority of lumbar hernias were corrected using muscle flaps that are taken from gluteus maximus, medius and latissimus dorsi muscles and fascia lata [10], but the management has very high recurrence rate because of high tension of the repair and poor facial strength. Later on, the surgeons used the artificial mesh with polypropylene, prolene or Marlex for bridging the defect [11].

The usage of synthetic mesh for repairing hernia had complications like infection, bowel obstruction, and formation of fistula. The use of biosynthetic mesh which is retrieved from human dermis has been used recently and has been producing good results, particularly in unclean wounds [12]. Although there are a plethora of operative techniques that have been



Figure 2



Operative technique. (a) An incision over the old scar and elevation of upper flap; (b) an elevation of the lower flap; (c) identification of edges of muscles defect; (d) approximation of edges; (e) insertion of mesh plug; (f) closure of defect edges over mesh plug with continuous sutures; (g) defect closed completely by adding interrupted sutures; (h) fixation of onlay prolene mesh; and (i) closure of wound in layers with subcutaneous suction drain.

**Table 3 Operative and postoperative findings of our patients**

Operative and postoperative data	Group 1 (N=10) (mean±SD)	Group 2 (N=10) (mean±SD)	P value <sup>●</sup>
Duration of operation (min)	1.93±0.17	1.33±0.40	<0.001
Hospital stay (days)	2.93±2.06	3.06±1.98	0.782

●Mann–Whitney *U*-test.

**Table 4 Postoperative outcome of our patients**

Outcome of treatment	Group 1 (N=10) [n (%)]	Group 2 (N=10) [n (%)]	P value <sup>‡</sup>
Complication			
Absent	8 (80)	1 (10)	0.028
Present	2 (20)	9 (90)	
Complication			
Absent	8 (80)	1 (10)	0.038
Early alone	1 (10)	4 (40)	
Late alone	1 (10)	3 (30)	
Early and late	0 (0)	2 (20)	
Early complication			
Absent	9 (90)	4 (40)	0.136
Present	1 (10)	6 (60)	
Wound infection	1 (10)	2 (20)	0.136
Wound dehiscence	0 (0)	2 (20)	0.136
Serous discharge	0 (0)	1 (10)	0.136
Superficial ischemia	0 (0)	1 (10)	0.269
Late complication			
Absent	9 (90)	5 (50)	0.109
Present	1 (10)	5 (50)	
Painful ugly scar	0 (0)	0 (0)	0.109
Tender swelling	0 (0)	1 (10)	0.136
Recurrence	1 (10)	4 (40)	0.020

‡ $\chi^2$ -test. *P*<0.05, significant.

described, there is no recommended specific approach of management. The most recent management in the meshplasty era is the nonabsorbable mesh, which is preferred for management: it could be inserted onlay, inlay or underlay according to the defect size, and it should cover all the area that is present between the 12th rib and the iliac crest. Traditionally, it is fixed to the floor by interrupted nonabsorbable stitches [13].

Hernia repair using a nonabsorbable mesh has become the recent standard management in the previous years. However, prosthetic implantation aspects are still being under consideration, especially during choosing type of prosthetic material. So, we use different method with addition of another mesh aiming to decrease the recurrence rate.

Our technique uses the same well-described methods for the repair of lumbar hernia with addition of another mesh aiming to decrease the recurrence rate. We found decreased rate of recurrence in group 1 cases in comparison with the traditional technique of

management in group 2 cases. Petersen *et al.* [14] have used the sublay method only, as such technique is well known and evaluated for many passing decades, particularly by French surgeons [15]. Petersen *et al.* [14] used mesh that was ~25×38 cm in size for repairing flank incisional hernias, and they have observed that there is no recurrence of the hernia in their four patients who underwent mesh repair for flank hernia. Therefore, results of Petersen *et al.* [14] proved that mesh repair of hernia could decrease the recurrence rate of hernia up to ~10% [16,17]. However, the disadvantage is that there are a huge number of patients complaining of surgical site discomfort, for example, abdominal stiffness and persistent pain. After repair of incisional flank hernias, most patients complain of discomfort and presence of bulge of muscles at the incisional site postoperatively. So, many questions arise about the benefit of such surgical approach. The answer to these questions is that the patients have reinforcement of their hernia sac, additionally there is improvement in the asymmetry of the abdominal wall and there will be restoration of the abdominal wall integrity. So in our study, we improved patient recovery and decreased the incidence of recurrence by double mesh. In the study by Stoppa [15], modification fixed the mesh only to the roof upon closure of the latissimus dorsi muscle, so did not have to increase the defect, the tissue injury was less, the procedure was quick and we gained the advantages of tension-free mesh repair.

Other possibilities include a mesh plug and a retroperitoneoscopic tension-free mesh repair [18,19]. According to Susmallian *et al.* [20], postoperative seroma detected by ultrasound is reported in most cases of laparoscopic mesh hernia repair, although only one-third was clinically apparent and all resolved after needle aspiration.

As no single technique has been proved to be more beneficial, we carried out this paper and used the double-mesh technique to overcome all the disadvantages of the previous techniques, and our approach has the advantage of decreasing rate of recurrence, postoperative complications, and patient discomfort.

### Summery

Occurrence of lumbar hernias is rare a surgical problem. There is a need to exclude other differential diagnostic surgical problems, which can be reached by a good history and detailed general physical examination. Moreover, it will be important to do a computed tomography scan as a routine investigation before planning surgical approach, as some patient may present with life-threatening complications. The present literature studies have suggested the onlay mesh repair to decrease the recurrence rate of hernia, and we have used the double-mesh onlay and sublay together. Planning and choosing operative approach should be done according to the size, contents, location, and etiology of the hernia, chances of recurrence in addition to the expertise in the hospital and availability of facilities.

Patients who are candidates for this procedure have an evidence of a flank hernia with a palpable edge of the hernia at the abdominal and flank fasciae. In our group of patients, we proved that using double-mesh repair for management of incisional flank hernia can provide reinforcement of the hernia and also it allows restoration of integrity of the abdominal wall. However, a paralyzed flank that has a muscle bulge will remain, and the patients must know that there will be potentially persistent nonspecific pain discomfort.

### Conclusion

Our double-mesh technique in the repair of lumbar incisional hernia is a novel technique, is safe with no intra-abdominal injuries or collections, is easy to be performed in short time without difficulties, is a successful modality in solving the problem of recurrent lumbar incisional hernias and provides better results in short-term follow-up without recurrence; however, long-term follow-up is needed to prove its efficacy.

### Recommendation

Longer follow-ups in future studies are needed to confirm the quality of our novel technique especially in paralytic cases that are caused by postoperative nerve injury.

### Financial support and sponsorship

Nil.

### Conflicts of interest

There are no conflicts of interest.

### References

- Sahoo M, Kumar A. Sandwich technique of closure of lumbar hernia: a novel technique. *IJCRU* 2013; 4:243–247.
- Yavuz N, Ersoy Y, Demirkesen O. Laparoscopic incisional lumbar hernia repair. *Hernia* 2009; 13:281–286.
- Shekarriz B, Graziottin T, Gholamis S. Transperitoneal preperitoneal laparoscopic lumbar incisional herniorrhaphy. *J Urol* 2001; 166:9–1267.
- Gardner GP, Josephs LG, Rosca M, Rich J, Woodson J, Menzoian JO. The retroperitoneal incision. An evaluation of postoperative flank bulge. *Arch Surg* 1994; 129: 753–756.
- LeBlanc KA. Proper mesh overlap is a key determinant in hernia recurrence following laparoscopic ventral and incisional herniarepair. *Hernia* 2016; 20:85–89.
- Meinke A. Totally extraperitoneal laparoendoscopic repair of lumbar hernia. *Surg Endosc* 2003; 17:7–734.
- Moreno-Egea A, Torralba-Martinez J, Morales G. Open vs laparoscopic repair of secondary lumbar hernias. A prospective non randomized study. *Surg Endosc* 2005; 19:184–187.
- Waligamage TB, Ramesh BS, Alsawafi Y. Case report and review of lumbar hernia. *Int J Surg Case Rep* 2015; 6:230–232.
- Alfredo M-E, Enrique GB, Miquel CC, José Antonio TM, José LA. Controversies in the current management of lumbar hernias. *Arch Surg* 2007; 142:82–88.
- Swartz DWT. Lumbar hernia. In: Nyhus LM, Condon RE, *Hernia*. 2nd ed. Philadelphia: Lippincott 1978. 409–426
- Skandalakis LJ, Skandalakis JE, Skandalakis PN. *Surgical anatomy and technique*. 3rd ed. 2008; 3: 2445–2455.
- Beth-Ann S, Victoriya Sara C, Kelly J, Joshua NH, Tomer D. Repair of a traumatic lumbar hernia with biosynthetic mesh: a novel approach and review of the literature. *J Curr Surg* 2012; 2:105–109.
- Al-Ardah AMM, Albsoul N, Younes N. Underlay mesh repair for spontaneous lumbar hernia. *Int J Surg Case Rep* 2013; 4:534–536.
- Petersen S, Schuster F, Steinbach F, Henke G, Hellmich G, Ludwig K. Sublay prosthetic repair for incisional hernia of the flank. *J Urol* 2002; 168:2461–2463.
- Stoppa RE. The treatment of complicated groin and incisional hernias. *World J Surg* 1989; 13:545.
- Luijendijk RW, Hop WC, van den Tol MP, de Lange DC, Braaksma MM, Ijzermans JN, *et al*. A comparison of suture repair with mesh repair for incisional hernia. *N Engl J Med* 2000; 343:392.
- Korenkov M, Paul A, Sauerland S, Neugebauer E, Arndt M, Chevrel JP, *et al*. Classification and surgical treatment of incisional hernia. Results of an expert are meeting. *Langenbecks Arch Surg* 2001; 386:65.
- Losanoff EJ, Kjossev KT. Diagnosis and treatment of primary incarcerated lumbar hernia. *Eur J Surg* 2002; 168:193–195.
- Habib E. Retroperitoneoscopic tension-free repair of lumbar hernia. *Hernia* 2003; 7:150–152.
- Susmallian S, Gewurtz G, Ezri T, Charuzi I. Seroma after laparoscopic repair of hernia with PTFE patch: is it really a complication? *Hernia* 2001; 5:139–141.