

# Onlay hernioplasty versus Rives–Stoppa repair for paraumbilical hernia associated with divarication of recti in diabetics in terms of recurrence and surgical site infection: a prospective randomized controlled trial

Walid M. Abd El Maksoud, Khaled S. Abbas

Colorectal Surgery Unit, Department of General Surgery, Faculty of Medicine, Alexandria University, Alexandria, Egypt

Correspondence to Walid M. Abd El Maksoud, MD, PhD, MRCS, Colorectal Surgery Unit, Department of General Surgery, Faculty of Medicine, Alexandria University, Alexandria 21526, Egypt. Tel: 00201211433351; fax: +20 3591 0720; e-mail: dr.waleedmaksoud@gmail.com

**Received** 14 March 2018

**Accepted** 10 May 2018

**The Egyptian Journal of Surgery**  
2018, 37:453–459

## Purpose

The aim of this study was to compare between onlay hernioplasty and Rives–Stoppa repair (RS) for management of paraumbilical hernia associated with divarication of recti in diabetic patients in terms of recurrence and surgical site infection.

## Patients and methods

A total of 60 diabetic patients with primary paraumbilical hernia and divarication of recti were randomly allocated into two groups: group I included 30 patients (mean age: 49.77±11.15 years) who were subjected to onlay repair and group II included 30 patients (mean age: 51.80±10.84 years) who were subjected to RS.

## Results

Eight (26.7%) patients in group I showed superficial wound infection, of whom three (37.5%) progressed to mesh infection. Three (10%) patients in group II developed superficial wound infection, with no progression to mesh infection. Seroma occurred in five (16.7) cases in group I, compared with one case in group II. All were treated conservatively, except one patient in group I who was infected and later led to mesh infection. Late mesh infection occurred in one patient in group I and one patient in group two. Recurrence was encountered in five patients after onlay repair compared with one patient after RS. All recurrent cases were owing to mesh infection and its removal. After 1 year, visual analog scale showed no significant difference between both groups regarding chronic postoperative pain.

## Conclusion

After 1-year follow-up, RS was favorable to onlay repair for management of diabetic patients with paraumbilical hernia and divarication of recti regarding recurrence and surgical site infection.

## Keywords:

diabetes mellitus, divarication of recti, onlay repair, paraumbilical hernia, Rives–Stoppa repair

Egyptian J Surgery 37:453–459

© 2018 The Egyptian Journal of Surgery

1110-1121

## Introduction

Paraumbilical hernia is one of the common types of hernia. It has a female to male ratio of 5 : 1 [1]. The defect through which paraumbilical hernia occurs is usually above and sometimes below the umbilicus. Obesity, with flabbiness of the abdominal muscles, and repeated pregnancy are important etiological factors. Paraumbilical hernias have great tendency to early irreducibility owing to their relatively narrow neck compared with the size of the hernia sac and adhesions of the omentum to the sac. This usually increases the risk of other more serious complications [2].

Not uncommonly, paraumbilical hernia is associated with divarication of recti, which is the separation of the two rectus abdominis muscles, usually as a result of the linea alba thinning and stretching [3]. The extent of the divarication may be measured by the inter-recti distance [4]. Once separated, the function of the

anterior abdominal wall may become compromised. The association of both paraumbilical hernia and divarication of recti in the same patients may be explained by similar etiological factors, especially multiple pregnancies [3]. Patients with paraumbilical hernia associated with divarication of recti may be handicapped by abdominal wall weakening and bulging, which may appear similar to pregnancy in some cases. In addition, paraumbilical hernia is prone to complicate. So these patients are candidates for surgical repair of their abdominal wall with special challenge owing to their weak abdominal wall [5].

This is an open access journal, and articles are distributed under the terms of the Creative Commons Attribution-NonCommercial-ShareAlike 4.0 License, which allows others to remix, tweak, and build upon the work non-commercially, as long as appropriate credit is given and the new creations are licensed under the identical terms.

There are many surgical procedures for repair of hernia; however, recurrence remains the main expected consequence. There are some factors that affect the recurrence rate, such as obesity, steroid use, increased intra-abdominal pressure, chronic lung diseases, and comorbidities. In addition to other factors, diabetes was identified as a factor that has a negative effect on the healing process, which may impair proper repair of hernia [6]. Terranova [7] noted the effect of diabetes on increasing surgical site infection which may affect the result of hernia repair, especially when using prostheses.

In addition to the recurrence, patients complaining of ventral hernia and rectus diastases may consider cosmetic outcome after hernia repair as an important additional parameter for success [8]. Midline plication for repair of rectus diastases associated with ventral hernias was preferred by many surgeons because of concerns regarding risk of infection [8,9]. Up to 100% recurrence with frustration of the patients after plication of rectus diastases was found by Al-Qattan [10] who questioned the durability of plication alone and suggested that a reinforced mesh repair may be more suitable.

Repairs of the abdominal wall that use permanent prostheses differ based on where the prosthesis is placed anatomically. Onlay repair is one of the commonest repairs used to repair abdominal wall in which mesh is applied superficial to anterior rectus sheaths. Being an easy technique may be the cause of its wide practice. However, onlay techniques have been associated with recurrence rates as high as 23% in cases with weak abdomen. In addition, locating the mesh in the subcutaneous space carries the risk of surgical site infection with subsequent sinus or even recurrence [11].

Rives–Stoppa repair (RS) is a technically difficult repair [12] and involves retro muscular prefascial placement of a large mesh anterior to the posterior rectus sheath and primary closure of the anterior fascia. It has a theoretical advantage of keeping the mesh away from the wound and subsequently less liability of surgical site infection [13].

The aim of this study was to compare between onlay hernioplasty and RS for management of paraumbilical hernia associated with divarication of recti in diabetic patients in terms of recurrence and surgical site infection.

## Patients and methods

This study followed a randomized controlled prospective trial design, using a parallel group two-arm design, monocentric and open label, with allocation ratio of

1 : 1. According to Charan and Biswas [14], a minimal sample size needed for each group was calculated to be 29 for each study group. The calculation was based on  $\alpha$  error of 0.05 and power of 0.80 (based on review of relevant literature, the recurrence rate after paraumbilical hernia repair ranged from 3 to 23%) [11,15].

Eligibility criteria included adult diabetic patients (>18 years old) who had primary paraumbilical hernia with divarication of recti, and they had BMI less than or equal to 35 kg/m<sup>2</sup>. Patients were electively admitted to the General Surgery Department, Alexandria Main University Hospital, during the period from October 2015 to April 2016. Exclusion criteria included patients with incarcerated hernia, previous hernioplasty, patients planned for abdominoplasty, or female patients who were planning to be pregnant within less than 2 years. Patients with BMI greater than 35 kg/m<sup>2</sup> were excluded from the study as they require more advanced surgical techniques and postoperative care. Patients who were receiving steroids for chronic disease were also excluded from the study as we thought they may be more prone to infection and will confuse the results.

### Preoperative workup

Preoperative assessment and treatment of any predisposing factors were performed. Divarication distance was measured. A written informed consent was obtained from all patients regarding undergoing the surgery as well as being included in this study.

A total number of 60 envelopes were divided into 30 onlay repair (OL) (group I) and 30 RS (group II). Envelopes were completely sealed and shuffled. An operative nurse (Ibrahim S.M.) with no involvement in the research and was blinded to the procedure chose an envelope and notified the operating surgeons about the type of repair just before the operation. Patients as well as surgeons who followed the patient in the outpatient clinic were blinded. A dose of ceftriaxone (1 g intravenous) was given to all patients just before induction of anesthesia.

### Operative workup

All patients were operated by the same team of consultants of general surgery with experience in the field of hernia repair. Patients in group I were subjected to standard onlay mesh repair. On the contrary, RS was performed for patients in group II. Polypropylene mesh (PROLENE; Ethicon) was the mesh to be used in both repairs. No drains were inserted after either onlay mesh repair or RS. Pressure dressing was applied and removed 24 h after the operation.

### Operative technique

All patients in both groups were operated upon under general anesthesia in supine position. In the onlay procedure, after skin incision (whether vertical or transverse) and identification of the sac, undermining the skin with the subcutaneous fat was performed laterally to expose the anterior rectus sheet, superiorly till the xyphoid process and inferiorly till below the hernia defect. The sac of the hernia is opened and excised, and contents are reduced. The defect is then closed, the defect of divarication is plicated, and the mesh is applied and fixed on the anterior rectus sheath from the xyphoid process to below the hernia defect extending approximately 5 cm from the edge of the plicated area. In the RS, after skin incision and identification of the sac, a longitudinal incision in the medial part of the anterior rectus sheath is performed in each side to reach the retrorectal space (Fig. 1a). Then the defect is closed and the mesh is designed in an H shape and applied over the posterior rectus sheet beneath the recti muscles with the transverse part of the H lying between the xiphoid process and the umbilicus (Fig. 1b). Dissection of 2 cm is made between rectus muscle and posterior rectus sheath above the level of xyphoid and below the level of the umbilical hernia defect to accommodate for the limbs of the H-shaped mesh. Fixation of the mesh is made in two main points, just below the xyphoid and in the lowermost point in the midline by 0–2 polypropylene sutures. This is followed by closure of anterior rectus sheath.

### Outcomes

#### Primary end points

- (1) Recurrence was checked at 1, 3, 6, and 12 months by examination by surgeons during follow-up visits

in outpatient clinic and if required, was confirmed by radiological study.

- (2) Surgical site infection [16] was checked at 1, 3, 6, and 12 months by examination by the surgeon during follow-up visits in an outpatient clinic and, if required, was confirmed by radiological study and culture sensitivity.

#### Secondary end points

The following were the secondary end points:

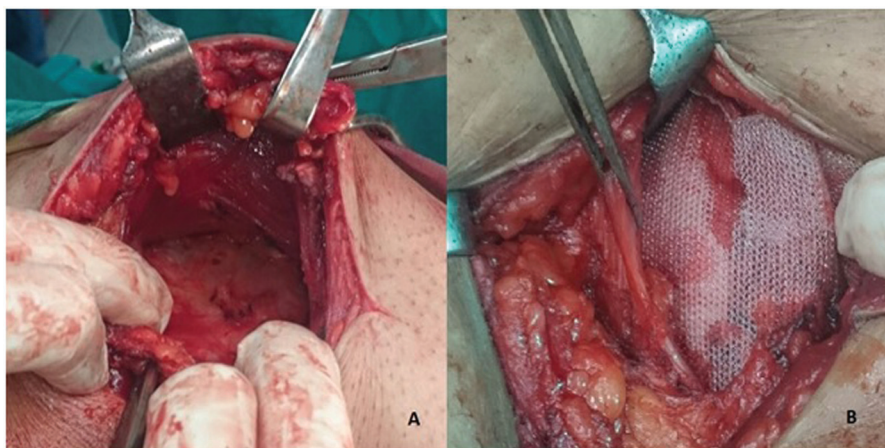
- (1) Operative time (min) measured by operative nurse at the time of operation.
- (2) Early postoperative complications (in the form of superficial infection and seroma) by examination by surgeons during the follow-up visits in the outpatient clinic.
- (3) Time to regain household and work activities (days) reported by the patient and recorded by the surgeon during the first visit of the patient to outpatient clinic on the 14th postoperative day.
- (4) Chronic postoperative pain was measured by modified visual analog scale [17] after 3, 6, and 12 months at rest and with movement by surgeons during follow-up visits in outpatient clinic.

No changes were made to trial outcomes after the trial commenced.

### Statistical analysis

The statistical analysis of the data was done using the statistical package for social sciences (SPSS version 22; SPSS Inc., Chicago, Illinois, USA). Descriptive statistics were applied (frequency and percentage for categorical variables, mean and SD for quantitative variables). To test significance of differences between

Figure 1



Intraoperative figure of Rives–Stoppa repair showing A: dissection of the space under the rectus muscle, B: mesh is applied over the posterior rectus sheet beneath the recti muscles.



both study groups, independent sample *t*-test was applied for quantitative data, whereas the  $\chi^2$ -test was applied for qualitative data (Fisher's exact test was used when appropriate). A statistically significant *P* value was considered at *P* value of less than 0.05.

The manuscript was written in accordance with items of the CONSORT 2010 checklist.

The research was approved by ethical committee of College of Medicine, Alexandria University (IRB 00007555, number of trial registry ACTRN12616000 244404; <http://www.ANZCTR.org.au/ACTRN12616000244404.aspx>).

## Results

No significant differences could be detected between the two groups regarding age, sex, type of diabetes, duration of diabetes, BMI, duration of hernia, percentage of smokers, and comorbidities (pulmonary diseases, hypertension, and renal insufficiency). Demographic and clinical data of the patients are shown in Table 1.

The mean operative time of RS (group II) was significantly longer than that of OL (group I). In addition, the estimated mesh size was significantly larger in RS (group II) than in OL (group I). On the contrary, no significant differences could be detected between the two groups regarding divarication distance, postoperative hospital stay, and time to regain household and work activities. Operative and postoperative data are shown in Table 2.

Regarding early postoperative complications, eight (26.7%) patients in the OL (group I) showed superficial wound infection in the form of wound erythema. They were treated conservatively by local wound care and parenteral antibiotics. Five of them showed complete resolution of the inflammation, whereas the other three showed progression of the infection reaching to the mesh. One of the patients with mesh infection showed sinus formation (Fig. 2). Unfortunately, removal of the mesh was the only solution that was followed by recurrence in the three cases. Three (10.0%) patients in the RS (group II) showed superficial wound infection and were treated successfully by conservative measures (local wound care and parenteral antibiotics). Five (16.7%) patients in OL (group I) developed subcutaneous seroma compared with one (3.3%) patient in the RS (group II). All patients were treated conservatively by repeated aspiration under strictly aseptic conditions. However, one patient in the OL (group I) developed infection and required removal of

**Table 1 Demographic and clinical data of the patients**

|   | Group I (OL)<br>(N=30) | Group II (RS)<br>(N=30) | <i>P</i> value |
|---|------------------------|-------------------------|----------------|
| Age (years)                               |                        |                         |                |
| Range                                     | 36–76                  | 36–74                   | 0.477          |
| Mean                                      | 49.77                  | 51.80                   |                |
| SD  | 11.15                  | 10.84                   |                |
| Sex [ <i>n</i> (%)]                       |                        |                         |                |
| Females                                   | 27 (90)                | 26 (86.7)               | 0.688          |
| Males                                     | 3 (10)                 | 4 (13.3)                |                |
| Type of diabetes mellitus [ <i>n</i> (%)] |                        |                         |                |
| Type II                                   | 26 (86.7)              | 27 (90)                 | 0.688          |
| Type I                                    | 4 (13.3)               | 3 (10)                  |                |
| Duration of diabetes mellitus (years)     |                        |                         |                |
| Range                                     | 1–31                   | 2–33                    | 0.942          |
| Mean                                      | 10.933                 | 10.767                  |                |
| SD  | 8.9324                 | 8.6848                  |                |
| Duration of hernia (months)               |                        |                         |                |
| Range                                     | 12–72                  | 13–75                   | 0.835          |
| Mean                                      | 35.76                  | 36.46                   |                |
| SD  | 15.15                  | 15.87                   |                |
| Smoking [ <i>n</i> (%)]                   |                        |                         |                |
| Smoker                                    | 5 (16.7)               | 6 (20.0)                | 0.739          |
| Ex-smoker                                 | 10 (33.3)              | 12 (40)                 |                |
| Nonsmoker                                 | 15 (50)                | 12 (40)                 |                |
| BMI (kg/m <sup>2</sup> )                  |                        |                         |                |
| Range                                     | 23.83–35.00            | 26.51–34.98             | 0.711          |
| Mean                                      | 31.51                  | 31.21                   |                |
| SD  | 3.49                   | 2.89                    |                |
| Comorbidities [ <i>n</i> (%)]             |                        |                         |                |
| Pulmonary diseases                        | 3 (10.0)               | 2 (6.7)                 | 0.714          |
| Hypertension                              | 3 (10.0)               | 4 (13.3)                |                |
| Renal insufficiency                       | 1 (3.3)                | 0 (0.0)                 |                |

the mesh that was followed by recurrence. The differences in rates of early postoperative complications between the two groups were not statistically significant (Table 3).

Regarding late complications, late mesh infection occurred in one (3.3%) patient 6 months after OL and in one (3.3%) patient 9 months after RS. Both patients were not fully compliant toward control of their diabetes. Drainage of pus was tried but infection was only controlled after removal of the mesh, after which both patients had recurrent hernias. Recurrence occurred in five (16.7%) patients in OL (group I).

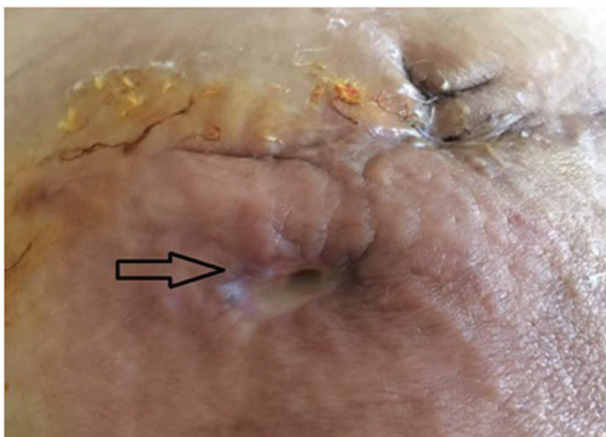Regarding recurrence, five patients in OL (group I) developed recurrence, compared with one patient in RS (group II). Mesh infection and its removal was the predisposing factor for recurrence in all patients in both groups. However, there was no significant difference between both groups regarding recurrence (Table 3).

The visual analog scale was used to assess postoperative chronic pain at rest and with movement after 3, 6, and

**Table 2 Operative and postoperative data**

|  | Group I (OL) (N=30) | Group II (RS) (N=30) | P            |
|--|---------------------|----------------------|--------------|
| Operative time (min)                       |                     |                      |              |
| Range                                      | 50–125              | 65–130               | <b>0.002</b> |
| Mean                                       | 83.03               | 97.03                |              |
| SD   | 18.32               | 14.90                |              |
| Divarication distance (cm)                 |                     |                      |              |
| Range                                      | 10–17               | 9–15                 | 0.429        |
| Mean                                       | 12.70               | 12.33                |              |
| SD   | 1.74                | 1.86                 |              |
| Hernia defect diameter (cm)                |                     |                      |              |
| Range                                      | 3–9                 | 2–10                 | 0.573        |
| Mean                                       | 6.00                | 5.73                 |              |
| SD   | 1.78                | 1.91                 |              |
| Estimated mesh size (cm <sup>2</sup> )     |                     |                      |              |
| Range                                      | 190–715             | 350–735              | <b>0.000</b> |
| Mean                                       | 308.17              | 513.17               |              |
| SD   | 134.97              | 103.43               |              |
| Hospital stay (days)                       |                     |                      |              |
| Range                                      | 4–23                | 4–20                 | 0.182        |
| Mean                                       | 7.63                | 6.40                 |              |
| SD   | 4.2                 | 2.70                 |              |
| Follow-up period (months)                  |                     |                      |              |
| Range                                      | 12–18               | 12–18                | 0.330        |
| Mean                                       | 14.97               | 14.50                |              |
| SD   | 1.94                | 1.74                 |              |
| Time to regain household activities (days) |                     |                      |              |
| Range                                      | 5–30                | 6–14                 | 0.145        |
| Mean                                       | 12.10               | 10.63                |              |
| SD   | 4.90                | 2.37                 |              |
| Time to regain work activities (days)      |                     |                      |              |
| Range                                      | 17–70               | 17–45                | 0.296        |
| Mean                                       | 27.13               | 24.07                |              |
| SD   | 13.85               | 7.88                 |              |

Bold values indicate statistical significance ( $P < 0.05$ ).

**Figure 2**

Postoperative case with mesh infection that resulted into sinus development.

12 months (Table 4). It was found that RS is associated with statistically significant more pain sensation compared with OL during movement after 3 and 6 months. However, there was no significant difference

**Table 3 Postoperative complications**

|                                   | Group I (OL) [n (%)] | Group II (RS) [n (%)] | P value |
|-----------------------------------|----------------------|-----------------------|---------|
| Early postoperative complications |                      |                       |         |
| Superficial wound infection       | 8 (26.7)             | 3 (10.0)              | 0.095   |
| Seroma formation                  | 5 (16.7)             | 1 (3.3)               | 0.085   |
| Mesh infection                    | 3 (10.0)             | 0 (0.0)               | 0.076*  |
| Late postoperative complications  |                      |                       |         |
| Late mesh infection               | 1 (3.3)              | 1 (3.3)               | 0.754*  |
| Recurrence                        | 5 (16.7)             | 1 (3.3)               | 0.085   |

\*P value was calculated by Fisher's exact test.

between the two groups at rest or with movement after 12 months.

## Discussion

The ideal surgical procedure for repairing a ventral hernia should have a low recurrence rate and minimal morbidity [18]. It remains controversial as to whether one method is superior to another. In fact, one repair may not be appropriate for all patients [19]. Furthermore, it is challenging to make controlled clinical study owing to different variables that may influence outcome. If we consider absence of a uniform hernia classification scheme to describe a patient's preoperative state, we will realize how it is difficult to discuss repair technique and prosthetic choice [19].

In our study, we tried to avoid the confusion regarding multiplicity of variables affecting hernia repair outcome by narrowing the inclusion criteria into a specific type of patients with specific criteria (diabetic patients with BMI  $\leq 35$  kg/m<sup>2</sup>, complaining of primary paraumbilical hernia and divarication of recti) to be able to have meaningful outcomes.

All patients included in this study were diabetic with high vulnerability to infection and delayed wound healing. The devastating effect of mesh infection in these patients and its consequences on outcome of ventral hernia repair mandates the proper choice of the surgical technique that carries less risk for these patients. The ever-increasing prevalence of diabetes mellitus (DM) among adults highlights the importance of research into the surgical complications associated with DM [20–22]. Especially that, DM has been shown to be associated with high incidence of postoperative infections and overall complications [23,24].

In our study, patients in group I (OL repair) showed a higher incidence of early postoperative complications

**Table 4 Modified visual analog scale for both groups**

|                     | Group I (OL) (mean±SD) | Group II (RS) (mean±SD) | P            |
|---------------------|------------------------|-------------------------|--------------|
| I: at rest          |                        |                         |              |
| VAS after 3 months  | 23.07±4.71             | 24.60±4.20              | 0.197        |
| VAS after 6 months  | 14.78±5.27             | 16.10±4.28              | 0.300        |
| VAS after 12 months | 6.08±5.86              | 6.38±4.14               | 0.824        |
| II: with movement   |                        |                         |              |
| VAS after 3 months  | 27.68±5.68             | 31.07±4.15              | <b>0.012</b> |
| VAS after 6 months  | 17.54±5.76             | 20.40±4.80              | <b>0.044</b> |
| VAS after 12 months | 6.72±5.76              | 8.10±5.03               | 0.351        |

VAS, visual analog scale. Bold values indicate statistical significance ( $P < 0.05$ ).

(i.e. superficial wound infection, seroma formation, and mesh infection) compared with group II (RS repair). Eight (26.7%) patients in group I (OL repair) showed superficial wound infection, of whom three (37.5%) progressed to mesh infection. On the contrary, in group II (RS repair), three (10%) patients developed superficial wound infection, but with no progression to mesh infection.

The progression of superficial wound infection into mesh infection among patients who underwent the onlay technique and not among those who underwent RS repair may be explained by the fact that the onlay repair requires wide tissue undermining with the location of the mesh in the subcutaneous space, with no barrier to prevent wound infection from spreading to the mesh [25]. On the contrary, the mesh in RS is located within the rectus sheath away from wound infection.

Tissue undermining with existence of the mesh as a foreign body may be the cause of formation of postoperative seromas after onlay repairs, which were encountered in five patients in group I compared with one patient only in group II in our study. In RS, placement of the prosthesis adjacent to the highly vascularized rectus abdominis muscle may minimize infection as well as seroma formation [18]. Treatment of seromas with aspiration was performed to our patients under complete aseptic technique. However, the risk of infection was existent with subsequent mesh infection in one patient in our study who developed infection after repeated aspiration of postoperative seroma. It is noteworthy that being diabetic, the vulnerability of our patients to infection was high. Differences between the two groups regarding early postoperative complications were not statistically significant.

Similar results were found by Abdollahi *et al.* [9], who reported higher incidence of postoperative complications after onlay repair compared with RS in patients with ventral hernia. In addition, de Vries Reilingh *et al.* [26]

reported high incidence of superficial wound infection (69%) and seroma formation (84%) among patients with onlay repair for management of ventral hernia.

Late mesh infection was encountered in two patients in our study, after 6 months (in group I) and 9 months (in group II). Both were associated with a period of uncontrolled diabetes before mesh infection. Mangram *et al.* [16] stated that diabetic patients are more vulnerable to have infections especially in presence of prosthesis that may be considered as a source of surgical site infection for complete 1 postoperative year. Patients' noncompliance toward strict diabetes control despite the strict advice may be considered as a reason for late mesh infection among these two patients in our study.

Postoperative infection in diabetic patients in the presence of prosthesis is extremely difficult to be controlled [6]. In our study, once mesh infection occurred, it was not possible to control either mesh infection or DM without mesh removal. All patients in this study who had mesh infection (five in group I and one in group II) were treated only by mesh removal with subsequent recurrence. Delay in aggressive management of the condition may carry the risk of necrotizing fasciitis [27]. Therefore, mesh infection should be a primary end point rather than a secondary end point in studies including diabetic patients with prosthesis. In our study, postoperative pain was found to be significantly higher among patients who underwent RS after 3 and 6 months. In addition, mesh size used in RS was found to be significantly larger than what was used in onlay repair. This may be owing to the fact that in RS the size of the mesh is almost standardized to be covering the retrorectal space compared with the onlay repair where the mesh is adjusted to be 5 cm beyond the edge of the defect. The idea of mesh repair is to strengthen the weak wall by creation of fibrosynthetic material. The amount of fibrous tissue laid on the mesh is proportionally related to amount of biomaterial of the mesh that acts as a foreign body [28,29]. Profound inflammatory response is generated by the nonabsorbable mesh, resulting in excessive scar

formation, nerve entrapment, increased rigidity and stiffness of the abdominal wall, and shrinkage of the biomaterial with time [30]. In our study, the more pain encountered after RS could be explained by the significant larger size of the mesh. However, after 12 months, there were no significant differences between both groups regarding postoperative pain.

Using a subjective way for measuring magnitude of pain (visual analog scale) and missing to assess the patients' diabetes control during the follow-up period are the main limitations of this study.

## Conclusion

RS seems to be a more favorable technique for the management of diabetic patients with paraumbilical hernia and divarication of recti compared with onlay repair. Mesh infection is a serious complication among these patients that necessitates mesh removal and subsequent recurrence. No difference was seen between both repairs regarding long-term postoperative pain. Conducting further studies comparing different types of mesh materials is suggested.

## Acknowledgements

The researchers would like to acknowledge the professional efforts of Dr Ossama A. Mostafa, Associate Professor, Family and Community Medicine Department, College of Medicine, King Khalid University in revising this study.

Walid M. Abd El Maksoud contributed to the idea of the research, performing the operations, writing of the manuscript, and correspondence. Khaled S. Abbas contributed toward performing the operations supervision of data collection, and revising of the manuscript.

## Financial support and sponsorship

Nil.

## Conflicts of interest

There are no conflicts of interest.

## References

- Dabbas N, Adams K, Pearson K, Royle GT. Frequency of abdominal wall hernias: is classical teaching out of date? *JRSM Short Rep* 2011; 2:1–6.
- Mann CV, Russel RC, William NS. *Hernia in Bailey and Love. Short practice of surgery.* 24th ed, London: Champion Hall; 2004. 1273.
- Hickey F, Finch JG, Khanna A. A systematic review on the outcomes of correction of diastasis of the recti. *Hernia* 2011; 15:607–614.
- Hsia M, Jones S. Natural resolution of rectus abdominis diastasis. Two single case studies. *Aust J Physiother* 2000; 46:301–307.
- Kulhanek J, Mestak O. Treatment of umbilical hernia and recti muscles diastasis without a periumbilical incision. *Hernia* 2013; 17:527–530.
- Vidovic D, Jurišić D, Franjic BD, Glavan E, Ledinsky M, Bekavac-Bešlin M. Factors affecting recurrence after incisional hernia repair. *Hernia* 2006; 10:322–325.
- Terranova A. The effects of diabetes mellitus on wound healing. *Plast Surg Nurs* 1991; 11:20–25.
- Cheesborough JE, Dumanian GA. Simultaneous prosthetic mesh abdominal wall reconstruction with abdominoplasty for ventral hernia and severe rectus diastasis repairs. *Plast Reconstr Surg* 2015; 135:268.
- Abdollahi A, Maddah GH, Mehrabi BM, Jangjoo A, Forghani MN, Sharbaf N. Prosthetic incisional hernioplasty: clinical experience with 354 cases. *Hernia* 2010; 14:569–573.
- Al-Qattan MM. Abdominoplasty in multiparous women with severe musculoaponeurotic laxity. *Br J Plast Surg* 1997; 50:450–455.
- Mehrabi M, Jangjoo A, Tavooosi H, Kahrom M, Kahrom H. Retracted article: long-term outcome of Rives-Stoppa technique in complex ventral incisional hernia repair. *World J Surg* 2010; 34:1696–1701.
- Bauer J, Harris M, Gorfine S, Kreeel I. Rives-Stoppa procedure for repair of large incisional hernias: experience with 57 patients. *Hernia* 2002; 6:120–123.
- Stoppa R, Henry X, Verhaeghe P, Largueche S, Myon Y. Trends in the surgical treatment of chronic dehiscences of the abdominal walls. *Bull Acad Natl Med* 1981; 165:493–501.
- Charan J, Biswas T. How to calculate sample size for different study designs in medical research? *Indian J Psychol Med* 2013; 35:121.
- Kurzer M, Kark A, Selouk S, Belsham P. Open mesh repair of incisional hernia using a sublay technique: long-term follow-up. *World J Surg* 2008; 32:31–36.
- Mangram AJ, Horan TC, Pearson ML, Silver LC, Jarvis WR. Guideline for prevention of surgical site infection. *Am J Infect Control* 1999; 27:97–134.
- Gould D. Information point: visual analogue scale (VAS). *J Clin Nurs* 2001; 10:706.
- Iqbal CW, Pham TH, Joseph A, Mai J, Thompson GB, Sarr MG. Long-term outcome of 254 complex incisional hernia repairs using the modified Rives-Stoppa technique. *World J Surg* 2007; 31:2398–2404.
- Heartsill L, Richards ML, Arafai N, Lee A, Bingener-Casey J, Schwesinger WH, Sirinek KR. Open Rives-Stoppa ventral hernia repair made simple and successful but not for everyone. *Hernia* 2005; 9:162–166.
- American Diabetes Association. National diabetes statistics report, 2014. Estimates of diabetes and its burden in the epidemiologic estimation methods. *Natl Diabetes Stat Rep* 2014; 2014:2009–2012.
- Hart A, Funderburk CD, Chu CK, Pinell-White X, Halgopian T, Manning-Geist B, et al. The impact of diabetes mellitus on wound healing in breast reconstruction. *Ann Plast Surg* 2017; 78:260–263.
- Ursula Mirastschijski AJ, Vogt Peter M. *Skin wound healing: repair biology, wound, and scar treatment, in plastic surgery.* Neligan PC, editor. Seattle: WA: Elsevier; 2012. 281.
- Raikundalia MD, Fang CH, Spinazzi EF, Vazquez A, Park RC, Baredes S, Eloy JA. Impact of diabetes mellitus on head and neck cancer patients undergoing surgery. *Otolaryngol Head Neck Surg* 2016; 154:294–299.
- Valentini V, Cassoni A, Marianetti TM, Mitro V, Gennaro P, Ialongo C, Iannetti G. Diabetes as main risk factor in head and neck reconstructive surgery with free flaps. *J Craniofac Surg* 2008; 19:1080–1084.
- Shell DH, de La Torre J, Andrades P, Vasconez LO. Open repair of ventral incisional hernias. *Surg Clin North Am* 2008; 88:61–83.
- De Vries Reilingh TS, van Geldere D, Langenhorst BL, de Jong D, van der Wilt GJ, van Goor H, Bleichrodt RP. Repair of large midline incisional hernias with polypropylene mesh: comparison of three operative techniques. *Hernia* 2004; 8:56–59.
- Chen KC, Klingel M, McLeod S, Mindra S, Ng VK. Presentation and outcomes of necrotizing soft tissue infections. *Int J Gen Med* 2017; 10:215.
- El Maksoud WA, El Salam MA, Ahmed HH. Comparative study between Lichtenstein procedure and modified darn repair in treating primary inguinal hernia: a prospective randomized controlled trial. *Hernia* 2014; 18:231–236.
- Cobb WS, Kercher KW, Heniford BT. The argument for lightweight polypropylene mesh in hernia repair. *Surg Innov* 2005; 12:63–69.
- Bawahab MA, El Maksoud WM. Evaluation of chronic postoperative pain after hernia repair using self fixing mesh for management of primary inguinal hernia in adult males. *Pak J Surg* 2013; 29:159–164.