

The outcome of using a prosthetic mesh in the repair of emergent abdominal midline incisional hernias: a prospective comparative study

Ashraf M. Abd El-Kader, Hazem E. Ali

General Surgery Department, Faculty of Medicine, Banha University, Banha, Egypt

Correspondence to Ashraf M. Abd El-Kader, MD, MRCS England, General Surgery Department, Faculty of Medicine, Banha University, Fared Nada Street, Banha 13518, Egypt. fax: 00966163640812; e-mail: dr_ashrafmahmoud@yahoo.com

Received 15 August 2017

Accepted 17 September 2017

The Egyptian Journal of Surgery
2018, 37:147–154

Objective

The aim of the study is to evaluate the efficiency and safety of mesh repair in emergent complicated midline incisional hernias as well as the impact on the early postoperative (PO) morbidity and mortality to implement the best patient management procedure.

Patients and methods

The study includes 60 patients with emergent midline incisional hernias. Patients were divided according to the type of closure of hernia defect into two groups, group A (30 patients) was managed with a prosthetic mesh repair and group B (30 patients) was managed by primary suture repair. We used the alternation method as an allocation process. Patients in both groups were monitored during operations and along the PO period. The data collected include the patients' condition at presentation, coexisting disease, operative data and PO complications, length of hospital stay, surgical site infection (SSI) and recurrence rates.

Results

A total of 60 patients underwent operations for emergent midline incisional hernias with ($N=30$) and without ($N=30$) the use of mesh repair. There is no significant difference between mesh and nonmesh groups about the mean operative time ($P>0.05$). Besides, there was no significant difference between both groups concerning the total hospital stay days. The SSI rate in the mesh repair group was 10%, while it was 6.7% in the primary suture repair group. The SSI rate was high among diabetic patients and those with chronic liver illness. The follow-up period ranged between 25 and 48 months with a significant difference between both groups regarding the recurrence rate ($P<0.05$).

Conclusion

Our prospective study offers an evidence that with adequate antiseptic precautions, it is possible and safe to use a nonabsorbable mesh in the repair of emergent abdominal wall midline incisional hernias with a significant decline in the recurrence rate.

Keywords:

emergent hernia, mesh repair, primary suturing, surgical site infection

Egyptian J Surgery 37:147–154
© 2018 The Egyptian Journal of Surgery
1110-1121

Introduction

Abdominal wall hernias were categorized as groin hernias (inguinal and femoral) and ventral hernias (epigastric, umbilical, incisional, port site and spigelian) [1]. A large percentage of abdominal hernias necessitate emergency intervention where operations were accompanied with a greater rate of postoperative (PO) morbidities [2]. An incarcerated hernia is a hernia in which the contents have converted irreducible due to sac adhesions or a narrow defect; it can be complicated by a bowel obstruction [3]. In the strangulated hernia, the blood supply of the hernia contents (gut and/or omentum) becomes compromised and necessitate urgent surgery [3]. It carries a major hazard to emergency hernia repair, as there is a higher incidence of surgical field contamination as well as PO infection [4].

Bacteria colonize all surgical wounds, but only a few of these lead to infection. Host defenses are capable of eradicating microbes at the surgical site. Inserting a foreign material as mesh may lead to a reduced threshold for infection [5,6]. Biologic mesh declines the immune response against the foreign body, as well as declining the incidence of fibrosis, erosion and fistula formation [7].

The first use of mesh for hernia repair was in 1958 by Usher and colleagues, with the debut of polyethylene mesh [8]. The usage of the mesh has considerably

This is an open access journal, and articles are distributed under the terms of the Creative Commons Attribution-NonCommercial-ShareAlike 4.0 License, which allows others to remix, tweak, and build upon the work non-commercially, as long as appropriate credit is given and the new creations are licensed under the identical terms.

diminished hernia recurrence in comparison with primary repair [9]. There has been a higher dependence on the mesh in hernia repair, either for supporting the abdominal wall or bridging the wall defect. Numerous studies display strong advantages of mesh use in elective cases, where the infection is scarce. According to the World Society of Emergency Surgery, limited studies have examined the outcome of mesh repair in an emergency situation [1]. From this point, we performed our present work to evaluate the usage of synthetic mesh in the repair of emergent midline incisional hernias.

Patients and methods

The current study implemented in the General Surgery Department, Banha University Hospital, Egypt and King Saud Hospital in Saudi Arabia since August 2013 till August 2017. Our study included 60 patients with emergent abdominal wall midline incisional hernias after approval of the study protocol by the local ethics committee. Patients were familiar with the potential hazards and benefits of both options (mesh repair and primary suture repair) and obtained fully informed written consent for participation in the study; patients were admitted and were clinically evaluated. An extra consent was taken for the surgical operation. Patients enrolled in the study if they fulfilled our inclusion criteria.

We defined emergent hernia repair as any repair that was done in a nonelective approach, within 24 h of the patient presentation to our emergency department, suffering from acute pain, vomiting, absolute constipation and unable to reduce the hernia manually, as it was previously. Inclusion criteria for our study were: Complicated midline incisional hernias necessitating emergent open surgical repair, age at least 18 years and up to 70 years, BMI less than 35 kg/m², the patient capability to offer informed consent and undergo the study procedure, and American Society of Anesthesiology (ASA) score of I–III. Exclusion criteria include participation in an additional device or drug study, clinically infected hernia site, notable psychiatric disease, ASA score of at least IV, and purulent peritonitis due to gangrenous gut.

Patients were divided into two groups (30 patients in each group) according to the type of closure of hernia defect as either mesh repair (group A) or primary suturing (group B). In our study, we used the 'alternation' method as an allocation process, which is not relying on anyone's individual decision. In this

distribution method, we did mesh repair to the first patient who was involved in the study, then primary suturing to the second patient, then mesh repair to the third patient, and so on. The primary endpoint was the evaluation of procedure time and the early PO complications with secondary endpoint including hernia recurrence within the four years of the study. Data were collected from each participating hospital.

Preoperative preparation

All included patients were examined clinically for demographic data including age, sex, BMI, coexisting morbidities and the type of hernia complications. All patients underwent routine laboratory investigations, ECG, abdominal radiographs in erect and supine positions and abdominal ultrasonography with a duplex study to check hernia contents viability. Patients received prophylactic intravenous antibiotic (metronidazole 500 mg and ceftriaxone 1 g) 1 h before surgery.

Operative technique

Operations were done under general anaesthesia. A long incision was made in the overlying hernial sac with the removal of the old scars. The hernial sac dissected and opened at the neck, with suction of any fluids inside the sac. The deficit widened in strangulated hernias to release the constriction, release of adhesions between the contents and around the hernia defect. The viability of the sac contents was evaluated, suspicious bowel covered with warm wet towels for 15 min while gangrenous contents resected and bowel continuity held. The hernial sac was preserved for a probable need for closure, flaps were raised by separation of the subcutaneous (SC) tissue from the anterior rectus sheath. Irrigation of the SC tissue was done at the surgical sites with 10% povidone iodine solution (1% available iodine) for 60 s, followed by copious amounts of warm normal saline 0.9% to wash out any residual infection or any minute tissue debris before mesh implantation. Change of surgical gloves, towels, drapes and contaminated instruments should be done.

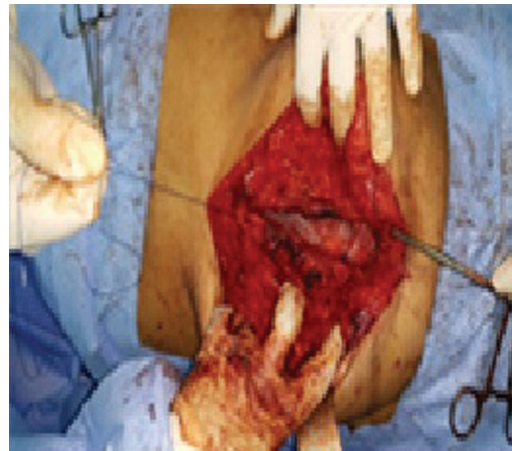
In the mesh repair group, a bilateral tunnel was fashioned in the recuts sheath through dissection of the posterior rectus sheath from the rectus muscles. Edges of the posterior layers of right and left rectus sheaths were sutured to each other's (Fig. 1). A polypropylene mesh was inserted behind both rectus muscles, extended for at least 5 cm on both sides, cranial, and caudal of the suture line. The mesh was fixed to the anterior rectus sheath with interrupted nonabsorbable polypropylene sutures passing through

the rectus muscle (Fig. 2). The anterior layers of the rectus sheath on both sides were sutured to each other with a running nonabsorbable suture (Fig. 3). Hernias with a large defect managed by either bilateral component separation with an approximation of the two recti or by use of the hernial sac medially as an interposition between the polypropylene mesh and bowel loops. Then, an onlay mesh was inserted and fixed in both conditions. The skin closed over SC 18 Fr suction drain (Fig. 4).

In the primary suturing group, after irrigation of the SC tissue at the surgical sites, the two recti were sutured to each other with a running nonabsorbable suture enforced with interrupted sutures. Large hernias (Fig. 5) were managed with bilateral component separation (Fig. 6) to allow closure of the defect with a running nonabsorbable suture enforced with

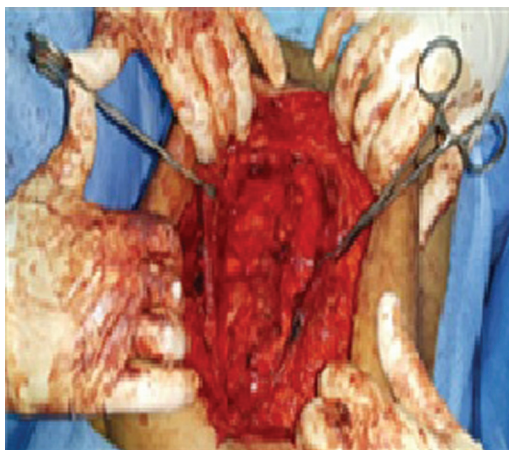
multiple simple sutures without tension. The skin closed over SC 18 Fr suction drain.

Figure 3



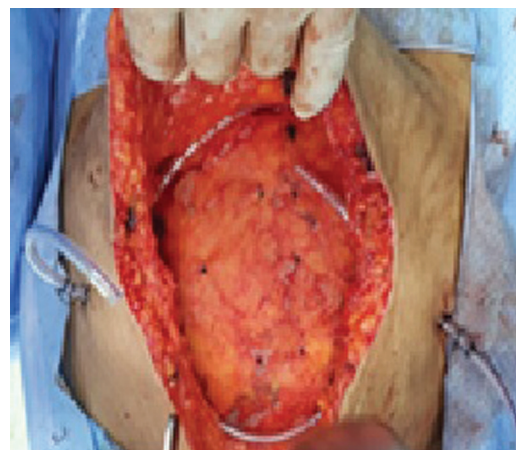
Anterior layers of both rectus sheaths were sutured to each other's.

Figure 1



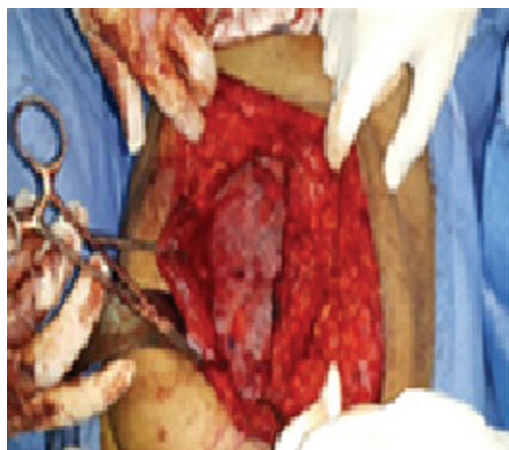
Posterior layers of rectus sheaths were sutured to each other.

Figure 4



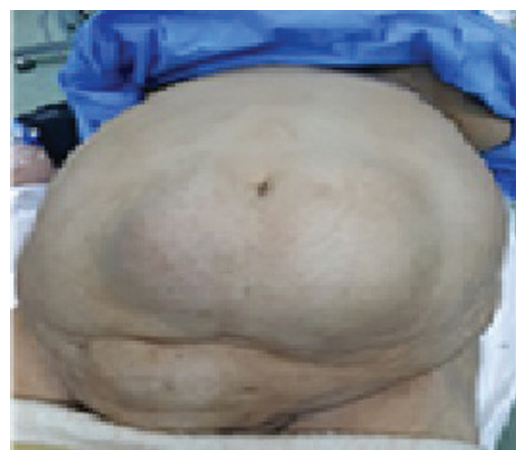An onlay synthetic mesh with 18 Fr suction drains.

Figure 2



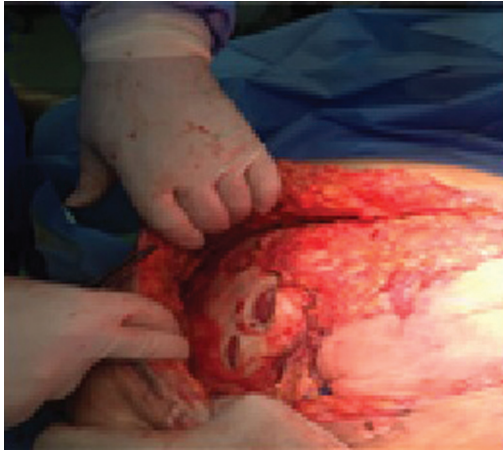
Mesh inserted behind both recti, fixed to anterior rectus sheath with interrupted sutures through rectus muscle.

Figure 5



An obstructed large midline incisional hernia.

Figure 6



Multiple release incisions through the external oblique muscle.

Postoperative follow-up

- (1) Patients were encouraged for early ambulation with a proper abdominal binder.
- (2) The intra-abdominal tension assisted through a urinary bladder catheter if abdominal hypertension was suspected. However, in all cases, we did not record any noticeable increase in the intra-abdominal pressure.
- (3) Drains were removed after 2 days or when it became minimal (<50 ml in 24 h).
- (4) On discharge from the hospital, patients were instructed to avoid lifting heavy objects and rapid treatment of constipation and cough. There was outpatient clinic follow-up every week after discharge for the first month, then every 3 months during the first year.
- (5) Follow-up ranging from 25 to 48 months.
- (6) Wound infection [surgical site infection (SSI)] recognized as a pussy discharge/collection as well as redness related to the operation site and fever or leucocytosis. However, seroma was determined during the outpatient clinic visit when there is a sterile serous fluid collected in the operative field subsequent to drain removal. Abdominal wall ultrasonography was done when there is any swelling related to operation field.
- (7) During the first PO month, three patients of the mesh repair group were readmitted due to fever, leucocytosis and wound infection, which subsided in two patients with IV antibiotics and local dressing. However, the third patient did not respond to conservative management and reoperated 25 days PO for drainage of a deep settled infection, an onlay mesh was removed, the wound was irrigated and kept open for frequent dressing and for secondary suture 2

weeks later. On the other hand, two patients of group B were readmitted due to wound infection, they responded to conservative management.

- (8) Seroma was aspirated in the outpatient clinic by using a 50 ml sterile syringe under aseptic condition with the guidance of ultrasonography.
- (9) Hernia recurrence was confirmed by an abdominal ultrasonography after taking a proper history and clinical examination.

Statistical analysis

Data presented as mean±SD, ranges, numbers, and ratios. Results were analyzed using Wilcoxon's ranked test for unrelated data (Z-test) and χ^2 -test for numerical data. Statistical analysis conducted using the SPSS (version 21) for Windows statistical package (IBM Corp., Armonk, NY, USA). A *P*-value of less than 0.05 is considered statistically significant.

Results

The study comprised 60 patients with emergent midline incisional hernias. Patients were divided into two groups (30 patients in each group) according to the type of closure of hernia defect as either mesh repair (group A) or primary suturing (group B). There were no difference between both groups regarding age, sex, BMI, and ASA score distribution or medical history. Patients' demographic data are clearly shown in Table 1.

The mainstream of patients in both groups passed the operations easily without intraoperative complications. The mean operative time with the mesh repair group was higher 110±20.91 compared with 95±18.07 in the primary suturing group; however, there was no significant difference in operative time between both groups. No significant difference between both groups regarding total ICU admission days and total hospital stay days. The details of the operations and PO period are summarized in Table 2.

Within a mean follow-up period of 35±7.26 months, the total number of PO complications was the same in the two groups. There were no significant differences regarding SSI and seroma formation between both groups. However, there was a significant difference (*P*=0.041) regarding recurrence rate between both groups. The rate of SSI was slightly higher among patients managed with mesh repair than primary suturing repair (10 vs. 6.6%, respectively). Details of PO complications are mentioned in Table 3.

Table 1 Patients' demographic data

Data	Strata	Mesh repair group	Primary suturing group	P-value
<i>n</i> (%)	60	30 (50)	30 (50)	
Age (years)		45.73±13.31 (20–70)	43.70±13.62 (19–69)	0.229
Sex	Males	14 (46.7)	15 (50)	NS
	Females	16 (53.3)	15 (50)	NS
BMI (kg/m ²)		30.33±2.73 (26–35)	31.26±3.09 (25–33)	0.508
ASA score		1.66±0.71 (1–3)	1.60±0.81 (1–3)	0.365
Coexisting disease ^a	Diabetes	9 (30)	8 (26.6)	NS
	Hypertension	8 (26.6)	6 (20)	NS
	IHD	5 (16.6)	4 (13.3)	NS
	Chronic liver disease	9 (30)	7 (23.3)	NS
	Chronic lung disease	6 (20)	8 (26.6)	NS
	CRF	1 (3.3)	1 (3.3)	NS
Type of hernia complications	Irreducible	4 (13.3)	6 (20)	NS
	Incarcerated	6 (20)	5 (16.7)	NS
	Obstructed	11 (36.7)	8 (26.6)	NS
	Strangulated	9 (30)	10 (33.3)	NS

Data are presented as mean±SD and numbers; ranges and percentages are in parentheses; ASA, American Society of Anesthesiologists; CRF, chronic renal failure; IHD, ischemic heart disease; ^aSome cases had more than one coexisting disease.

Table 2 Operative and 30 days postoperative data

Data	Strata	Mesh repair group (<i>n</i> =30)	Primary suturing group (<i>n</i> =30)	P-value
Operative time (min)		110±20.91 (80–190)	95±18.07 (60–150)	0.103
Intraoperative blood loss		148±44.9 (100–250)	139±44.50 (50–250)	0.318
Bowel resection		6 (20)	7 (23.3)	NS
ICU admission (days)	Total (days)	2.00±1.22 (1–4)	4.6±3.05 (1–8)	0.251
Hospital stay (days)	<5	12 (40)	14 (46.7)	
	5–7	10 (33.3)	11 (36.7)	
	8–10	5 (16.7)	3 (10)	
	>10 days	3 (10)	2 (6.6)	
	Total (days)	6.73±4.63 (3–23)	6.00±4.12 (2–20)	0.223
Reoperation	Due to SSI	1 (3.3)	0.0	NS
Readmission	Due to SSI	3 (10)	2 (6.6)	NS
	Due to medical morbidities	1 (3.3)	3 (10)	NS

Data are presented as mean±SD and numbers; ranges and percentages are in parentheses; PO, postoperative; SSI, surgical site infection.

Table 3 Postoperative complications

Strata	Mesh repair group (<i>n</i> =30)	Primary suturing group (<i>n</i> =30)	P-value
Hematoma/bleeding	2 (6.7)	1 (3.3)	NS
SSI	3 (10)	2 (6.6)	NS
Seroma	2 (6.7)	2 (6.7)	NS
Hospital acquired chest infection	0.0	1 (3.3)	NS
Recurrence	2 (6.6)	5 (16.6)	0.041
Total events	13	13	NS

Data are presented as *n* (%) are in parentheses; SSI, surgical site infection.

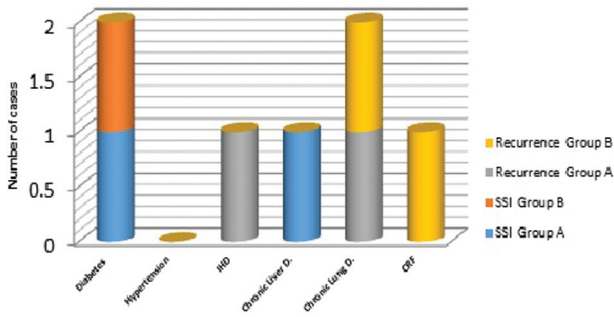
In our study, the SSI appears to be more frequent among diabetic patients, while other PO complications were not related to any of the chronic comorbidities. The frequency of PO complications was related to the chronic coexisting diseases (Fig. 7). The least number of PO complications was recorded among patients with irreducible hernias, there is only one recurrent case. The frequency of PO complications was related to the type of hernia complication (Fig. 8). Besides, we found that the hazard for SSI was slightly higher among cases of

bowel resection in the mesh repair group (two out of six) compared with (one out of seven) cases in the primary suturing group. The frequency of PO complications in relation to bowel resection in strangulated hernias was shown in Fig. 9.

Discussion

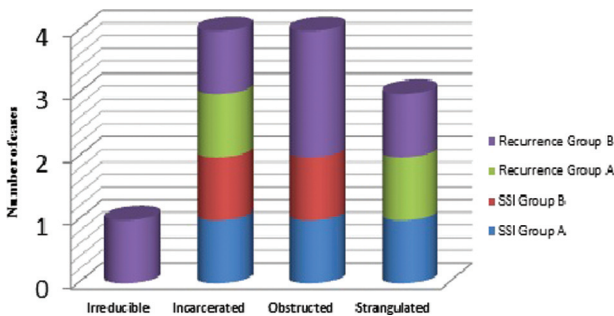
Numerous studies have shown a clear worldwide approval about the benefits of mesh repair in elective

Figure 7



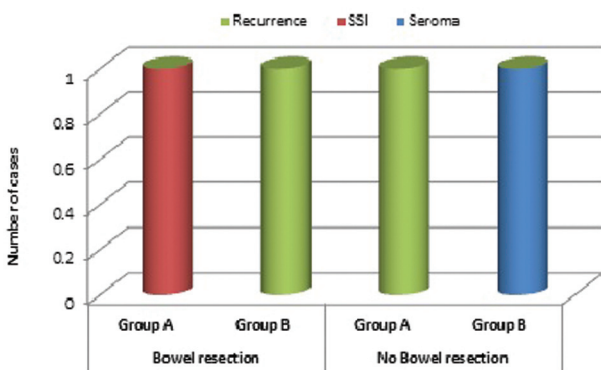
The frequency of postoperative complications in relation to the chronic coexisting diseases. CRF, chronic renal failure; IHD, ischemic heart disease; SSI, surgical site infection.

Figure 8



The frequency of postoperative complications in relation to the type of hernia complication. SSI, surgical site infection.

Figure 9



Distribution of the postoperative complications in strangulated hernias in relation to the bowel resection. SSI, surgical site infection.

cases, where the infection is unusual and mesh significantly decreases the rate of recurrence, yet it has low complication rates [10]. On the reverse, limited researches have studied the outcome of mesh use in an emergency situation, where there is frequently surgical field contamination due to bowel involvement [3]. Approximately 5–15% of all patients with abdominal wall hernias were operated in emergent conditions [11]. Approximately 20% of all patients

with complicated hernias require bowel resection due to gangrene caused by strangulation [12]. Propylene material was selected for the synthesis of surgical meshes due to its property of resistance to infection. It is a monofilamentous structure and wide pores allow infiltration of immune cells and antibiotics [13]. Up to date, the mesh is not habitually used in the repair of emergent hernias and most surgeons depend on primary suture repair for management of such conditions; this may be attributed to the panic of PO wound complications, especially in cases in which bowel is strangulated in the hernial sac and there is a need for resection [14]. For this reason, we aimed to study the consequence of acutely complicated abdominal wall hernias repaired with nonabsorbable mesh.

The rate of SSI in our study was higher among patients managed with mesh repair than the primary suturing repair group (10 vs. 6.6%, respectively). Moreover, we found that the hazard for wound infection was slightly higher among cases of bowel resection in the mesh repair group (two out of six) compared with one out of seven cases in the primary suturing group. In our study, the SSI appears to be more frequent in diabetic patients, while other PO complications were not related to any of the chronic comorbidities. This goes with Cavallaro *et al.* [14] who mentioned that for patients with incarcerated hernia and no signs of bowel strangulation or coexisting bowel resection, the surgical area is maintained clean and the infectious hazard for the inserted synthetic mesh is low. The study justifies this as the lack of bowel ischaemia renders patients less subjected to bacterial translocation, which may lead to contamination of the surgical field. Massimo and colleagues [1,15] also concluded that in patients with bowel strangulation and/or simultaneous bowel resection (potentially contaminated field), the primary suture is suggested when the hernia defect is small (<10 cm). However, the biological mesh repair can be implemented with caution. Xourafas *et al.* [16] studied the influence of mesh use on ventral hernia repairs with concurrent gut resections; they found a significantly greater incidence of PO infection in patients with mesh repair compared with those without mesh. They documented that the use of a mesh was the only significant risk factor regardless of other variables such as defect size, bowel resection or drain use. Besides Choi *et al.* [17] reported that, compared with clean cases, clean-contaminated cases showed a significantly higher chance of SSIs, wound disruption and sepsis. On the reverse, other studies have declared that mesh repair of

abdominal hernias can be securely performed together with simultaneous colonic operations. Antonopoulos *et al.* [18] reported that mesh repair is safe and effective in managing infected or contaminated hernias in kidney transplant patients. This is after taking into consideration wound irrigation with normal saline, repair with primary fascial approximation, prosthetic mesh reinforcement, large-bore drains and PO broad-spectrum antibiotics.

According to Kassem and El-Haddad [19], onlay positions are the favourite mesh positions in complicated ventral hernias. However, we believe that the inlay positioning of a synthetic mesh has many benefits; avoid hazards of intraperitoneal mesh on the bowel, away from possible SC tissue infection and escape the wide SC dissections to raise the flaps. This has also been reported in many other studies. The sequelae of wound infections in the present study are relatively minor. Most wound infections in the mesh repair group responded to conservative management (antibiotics and/or regional wound dressings) and were discharged home in decent clinical condition. Single and infected onlay mesh was removed at the operating theatre 25 days following mesh repair of a strangulated incisional hernia. The comparatively low percentage of infectious complications in our study can be referred to the strict aseptic precaution done before mesh placement, preoperative and PO use of broad-spectrum antibiotics and exclusion of cases with septic peritonitis as well as morbidly obese patients. Also, bowel resection was done in merely 20 and 23.3% of mesh repair and primary suturing group, respectively. Our findings correspond to the report of Hasbahceci and Basak [20], who found the same low rates of wound infections after usage of prosthetic mesh in the repair of acute hernias. On the other hand, 13.3% established different degrees of seroma; aspiration for variable volumes of seroma was performed under complete aseptic conditions in an outpatient clinic, and culture obtained from the aspirated fluid; however, no organism detected in all cases. To diminish the hazard of seroma, we recommend some rules that should be followed including kind dissection, slight use of diathermy, accurate hemostasis and prolonged times of drainage. Inlay and retrorectal mesh positions helped to reduce dissection and this leads to lower incidence of seroma formation in our study since this way creates a potential space in which a seroma can form. Montgomery [7] agree with us and mentioned that seroma was somewhat more with the onlay mesh associated with SC dissection.

Recurrence rates in our study are significant in nonmesh compared with the mesh group ($P=0.041$).

Recurrence rates were 6.7 versus 20% in mesh repair and primary suturing, respectively, after a mean follow-up period of 35 ± 7.26 months. The overall low recurrence rates may be attributed to the low rate of infection and proper surgical techniques. This goes with the results of Sorour [21]; however, they referred low recurrence rate to the adequate overlap of the mesh over the hernia defect for at least 5 cm and low wound infection rates. Lukasiewicz and Drewa [12] suggested that leaving a dead space, incorrect mesh placement and fixation are important factors for recurrence.

Conclusion

This prospective study provides confirmation that it is possible and safe to use a prosthetic mesh in the repair of emergent complicated abdominal wall midline incisional hernias, permitting reinforcement of the abdominal wall, even if the operation is associated with simultaneous bowel resection. The adequate antiseptic precautions and suitable surgical techniques should be taken into consideration.

Financial support and sponsorship
Nil.

Conflicts of interest

There are no conflicts of interest.

References

- Massimo S, Federico C, Gabrielle H, Giampiero C, Vincenzo M, Luca A, *et al.* WSES guidelines for emergency repair of complicated abdominal wall hernias. *World J Emerg Surg* 2013; 8:50.
- Helgstrand F, Rosenberg J, Kehlet H, Bisgaard T. Outcomes after emergency versus elective ventral hernia repair: a prospective nationwide study. *World J Surg* 2013; 37:2273–2279.
- Kulah B, Kulacoglu IH, Oruc T, Duzgun A, Moran M, Ozmen M. Presentation and outcome of incarcerated external hernias in adults. *Am J Surg* 2001; 181:101–104.
- Steven R, Gregory A. Definitive surgical treatment of infected or exposed ventral hernia mesh. *Ann Surg* 2003; 237:437–441.
- Samel S, Keesse M, Kleczka M, *et al.* Microscopy of bacterial translocation during small bowel obstruction and ischemia in vivo: a new animal model. *BMC Surg* 2002; 2:6.
- Rai S, Chandra S, Smile S. A study of the risk of strangulation and obstruction in groin hernias. *Aust N Z J Surg* 1998; 68:650–654.
- Montgomery A. The battle between biological and synthetic meshes in ventral hernia repair. *Hernia* 2013; 17:3–11.
- Wysocki A, Pozniczek M, Krzywon J, Bolt L. Use of polypropylene prostheses for strangulated inguinal and incisional hernias. *Hernia* 2001; 5:105–106.
- Koray A, Sanem G, Abdullah I, Selman S, Sedat K, Seymen B. Prosthetic repair of acutely incarcerated groin hernias: a prospective clinical observational cohort study. *Lang Arch Surg* 2010; 395:563–568.
- Martínez M, Pereira A, Sancho J, Argudo M, Cano G. Specific improvement measures to reduce complications and mortality after urgent surgery in complicated abdominal wall hernia. *Hernia j* 2012; 16:171–177.
- Miserez M, Alexandre H, Campanelli G, Corcione F, Cuccurullo M, Hidalgo A, *et al.* The European hernia society groin hernia classification: simple and easy to remember. *Hernia* 2007; 11:113–116.

- 12 Lukasiewicz A, Drewa T. Synthetic implants in hernia surgery. *Adv Clin Exp Med* 2014; 23:135–142.
- 13 Nieuwenhuizen J, van Ramshorst G, ten Brinke T, de Wit T, van der Harst E, Hop J, *et al.* The use of mesh in acute hernia: frequency and outcome in 99 cases. *Hernia* 2011; 15:297–300.
- 14 Cavallaro G, Campanile FC, Rizzello M, Greco F. Lightweight polypropylene mesh fixation in laparoscopic incisional hernia repair. *Minim Invasive Ther Allied Technol* 2013; 22:283–287.
- 15 Birolini C, Utiyama E, Rodrigues A, Birolini D. Elective colonic operation and prosthetic repair of incisional hernia: does contamination contraindicate abdominal wall prosthesis use? *J Am Coll Surg* 2000; 191: 366–372.
- 16 Xourafas D, Lipsitz S, Negro P. Impact of mesh use on morbidity following ventral hernia repair with a simultaneous bowel resection. *Arch Surg* 2010; 145:739–744.
- 17 Choi J, Palaniappa N, Dallas KB, Tamara B, Modesto J, Celia M. Use of mesh during ventral hernia repair in clean-contaminated and contaminated cases: outcomes of 33,832 cases. *Ann Surg* 2012; 255:176–180.
- 18 Antonopoulos I, Nahas W, Mazzucchi E, Celso A, Birolini C, Lucon A. *et al.* Is polypropylene mesh safe and effective for repairing infected incisional hernia in renal transplant recipients? *Urology* 2005; 66:874–877.
- 19 Kassem M, El-Haddad H. Polypropylene-based composite mesh versus standard polypropylene mesh in the reconstruction of complicated large abdominal wall hernias: a prospective randomized study. *Hernia* 2016; 20:691–700.
- 20 Hasbahceci M, Basak F. Interposition of the hernia sac as a protective layer in repair of giant incisional hernia with polypropylene mesh. *Surg Today* 2014; 44:227–232.
- 21 Sorour M. Interposition of the omentum and/or the peritoneum in the emergency repair of large ventral hernias with polypropylene mesh. *Int J Surg* 2014; 12:578–586.