

Efficacy of endovenous laser ablation (endovenous laser ablation) versus conventional stripping in the treatment of great saphenous vein reflux

El-Sayed A. Abd El-Mabood, Refaat S. Salama

Departments of General Surgery, Benha University, Benha, Egypt

Correspondence to El-Sayed A. Abd El-Mabood, MD, Department of General and Vascular Surgery, Benha University Hospital, Benha, 13516, Egypt; Mobile: 01065351802; e-mail: elsayedafifi@yahoo.com

Received 4 January 2017

Accepted 2 February 2017

The Egyptian Journal of Surgery

2017, 36:222–232

Purpose

The purpose of this study was to find out the advantages and efficacy of endovenous laser ablation (EVLA) versus conventional stripping in the treatment of great saphenous vein (GSV) reflux.

Background

Varicose vein treatment places a considerable strain on the medical system, with long waiting time for operation in the public hospital system. EVLA allows efficient treatment of many patients on an outpatient basis.

Patients and methods

This prospective study included 44 patients with primary varicose veins. Patients were randomly allocated into two groups according to the intervention performed – group A: conventional surgical stripping of the GSV [22 (50%)], and group B: EVLA ablation [22 (50%)]. All patients underwent clinical evaluation, routine hematological tests, and venous duplex of both lower limbs. The follow-up period was 6 months.

Results

There were satisfactory results in the EVLA group (group B); in about 20 (90.8%) cases of this group the procedure was performed under tumescent anesthesia with less mean postoperative time, 69.1±3 min, less postoperative pain rate, 4.05±1.23, less 1-week complications limited to Bruising and Ecchymosis in five (23.8%) cases, superficial phlebitis in three (14.28%) cases, developed thrombosis in two (9.52%) cases, or skin burn in one (4.76%) case. Rapid return to normal activity (5.8 ±1.5) and overall results were better in group B, 19 (90.47%), compared with group A, 14 (66.66%), with a *P*-value of 0.001.

Conclusion

EVLA of GSV, being simple to perform and well accepted by patients, is a safe and effective method with low rate of complications, one-day hospitalization, short recovery time, and quick return to professional activities. For these reasons, this method is considered a very promising technique especially in female patients for cosmetic reasons as compared with surgical stripping.

Keywords:

efficacy, endovenous laser ablation, great saphenous vein reflux, stripping

Egyptian J Surgery 36:222–232

© 2017 The Egyptian Journal of Surgery

1110-1121

Introduction

There is no universally accepted definition of a varicose vein; however, the following definition incorporates the important element – a superficial vein of the lower limb, which has permanently lost its valvular efficiency and as a product of the resultant venous hypertension in the standing position becomes dilated, tortuous, and thickened. This definition excludes the muscular veins in thin patients who simply have prominent but normally functioning veins without venous reflux [1].

Common symptoms include aching, heaviness, ankle swelling, pruritus, and, sometimes, muscle cramps. These symptoms are often made worse by prolonged standing or warm weather; an increase in referrals for varicose vein treatment has been noted in summer months [2].

Varicose veins are a common problem and cause disfigurement, disability, and impairment in the quality of life. The advent of endovenous ablation techniques has expanded the surgical options for patients requiring treatment [3].

Definitive treatment of varicose veins aims at abolishing sources of venous reflux, and removing long refluxing segments and varicose reservoirs can be achieved by conventional surgery or by endovenous ablation techniques [4].

This is an open access article distributed under the terms of the Creative Commons Attribution-NonCommercial-ShareAlike 3.0 License, which allows others to remix, tweak, and build upon the work noncommercially, as long as the author is credited and the new creations are licensed under the identical terms.

Fortunately, the pathophysiology of venous disease may lend itself to surgical treatment, which historically has centered on high ligation of the sapheno–femoral junction (SFJ) and/or stripping of the great saphenous vein (GSV). High ligation alone leads to unacceptably high recurrence rates; the addition of GSV stripping decreases recurrence, but with additional morbidity [5,6].

The cooperation between physics and phlebology has opened doors that one alone never could even have unlocked. If the already proven ‘fruitful’ cooperation between doctor and physicist continues, this already good therapy can reach the status of excellence [7].

Endovenous laser ablation (EVLA) is a minimally invasive percutaneous technique using laser energy to ablate incompetent superficial veins. EVLA is used primarily to treat venous insufficiency of the axial veins (i.e. great, small, or accessory saphenous veins) [8,9].

Boné, 1999, first reported on the delivery of endoluminal laser energy. Since then, an EVLA method for treating the entire incompetent GSV segment has been described. EVLA with a 980 nm diode laser system is clinically safe, feasible, and well-tolerated technique without scar and allows people to return to their normal daily activities rapidly. EVLA, which received approval from the United State Food and Drug Administration in January 2002, allows delivery of laser energy directly into the blood vessel lumen [10–12].

EVLA can be carried out under local or general anesthesia. EVLA involves delivery of laser energy into the blood vessel lumen. Non-thrombotic vein occlusion is achieved by heating the vein wall. Different wavelength, different energies, and pulsed or continuous light have been used; there is no feedback control as with radiofrequency ablation, and thus energy is delivered at a predetermined rate with sufficient heating of the vein wall where there is endothelial denudation and collagen contraction [13].

Endovenous procedures allow more efficient management of large numbers of patients with outpatient treatment. EVLA is simple to perform, well accepted by patients, and relatively a traumatic and safe procedure [8,9].

The current prospective selective study aimed to find out safety, efficacy, benefits, advantages, and outcomes of EVLA as compared with conventional venous stripping of incompetent GSV.

Patients and methods

After approval from the local ethics committee of Benha University and obtaining written fully informed patient consent, the current study was conducted at the Vascular Unit, General Surgery Department, Benha University and a private hospital from September 2015 until January 2017, so as to allow a 6-month follow-up period for the last case operated on. This prospective randomized controlled study was conducted on 44 patients with primary varicose veins. Patients were randomly allocated by using a computer-generated random number table into two groups according to the intervention performed – group A: conventional surgical stripping of GSV [22 (50%)], and group B: EVLA [22 (50%)].

Patients included in this study were suffering from symptomatic GSV incompetence, pain (44, 100%), visible varicose vein [42 (95.4%)], night cramps [two (4.5%)], restless leg [38 (86.4%)], bleeding [four (9.1%)], and skin discoloration [eight (18.2%)], and patients were having GSV with reflux more than 1 s on duplex ultrasound (US), GSV incompetence along its whole length with or without active ulcer, and Clinical, Etiological, Anatomical, Pathological (CEAP) C₂, C₃, C₄, C₅ grade (Clinical, Etiological, Anatomical, Pathological classification). All were fit for regional/general anesthesia. However, patients who were suffering from current deep vein thrombosis or acute superficial vein thrombosis, post-thrombotic syndrome, GSV or Short Saphenous Vein (SSV) less than 3 mm or greater than 15 mm in diameter, tortuous veins that were considered to be unsuitable for EVLA, coagulation disorder, peripheral arterial diseases, pregnant woman, those who were unable to ambulate, and those with extreme obesity were excluded from this study.

All patients presenting were admitted at the Vascular Unit, General Surgery ward, for clinical evaluation, routine hematological tests, and venous duplex of both lower limbs. After this, the patient was posted for intervention.

Interventions

In both groups, patients were operated under general, regional, or local anesthesia on a morning list. Preoperative marking of the patient in the standing position with an indelible marker was important in any case in which stab phlebectomy or direct perforator ligation was contemplated in group A and foam injection sclerotherapy was done in group B. Such marking was essential because visualization of varicose tributaries may be impossible once the patient was

prepared and the leg elevated. Patients were to be shaved immediately preoperatively with a clipper, and the leg was cleansed with an appropriate surgical preparation – i.e. aqueous povidone iodine 10% solution – and draped with the entire leg exposed from above the groin to just above the ankle. After gaining the GSV either in group A by venostripper or in group B by laser fiber and catheter, tumescent anesthesia was used (200–500 ml) to fully surround the saphenous vein. A combination of 25–40 ml of 1–2% lidocaine with 1 ml of epinephrine (1 : 100 000), 10 ml of sodium bicarbonate, and 450 ml of cold (4C°) normal saline in the tumescent mixture was administered perivenously under duplex scanning using an infusion pump until collapse of the GSV and nonechogenic halo of fluids were observed around the main trunk of GSV. Most of the interventions in group B were performed under local tumescent anesthesia; however, light intravenous sedation or spinal anesthesia might be used in some of the patients who could not tolerate pain, especially in group A [14,15].

Technique of surgical stripping

The GSV was most easily approached through an oblique incision 1 cm above and parallel to the groin crease. This location provided the best cosmetic results and the most reliable access to the SFJ. The incision started over the palpable femoral artery and extended medially to balance the better cosmesis of limited incisions with the necessity to ensure appropriate visualization of the SFJ and its tributaries to be ligated. High double ligation of the GSV was performed close to the femoral vein, with the second ligation being a suture ligature. Care was taken to avoid narrowing the femoral vein and to avoid leaving a long stump with a risk for thrombus formation and potential embolism [16,17].

Next, GSV stripping was performed using wire strippers or disposable plastic strippers to strip the vein from the knee to the groin by performing another incision; this standard stripping was the central component of the classic operation for varicose veins. Recurrence rates were markedly reduced when the GSV was stripped as opposed to when high ligation was performed alone. Associated varicosities if present were removed by multiple phlebectomies through small incisions. All legs were dressed postoperatively (PO) with cotton padding applied externally over the length of the GSV track, which was secured using a crepe bandage [18,19].

Technique of endovenous laser ablation

The patients were placed in antitrendelenburg position to minimize shrinkage of the vein, and EVLA was performed with FOX Diode ARC Laser system

(Fox™, Cherolase™ of ARC Laser Systems, Germany) and protective eye glasses. Laser 980 nm bare fiber was performed under tumescent anesthesia for all 22 patients. Mapping of GSV was mandatory by preoperative duplex US examination from SFJ until below the knee. Next, GSV was accessed using direct US guidance and micropuncture technique. If vasospasm occurred before successful cannulation, application of tourniquet proximal to the access site in conjunction with dependent positioning of the leg could be helpful or finally direct cut-down over GSV could present itself; in these techniques, lidocaine 1% was infiltrated over the site, a 1 cm small skin incision was made over the GSV, and then cannulation was proceeded under direct visualization. The ideal point of entry was caudal to most caudal point of reflux but not more than 10–15 cm below the knee (below which point saphenous nerve lies in close proximity to the vein) [20,21].

Then, a calibrated 40-cm-long vascular sheath 6 Fr was introduced to extend from the venotomy site to 5 cm below SFJ over the 0.35 j-tip 55 cm guide wire. This calibrated marking on the sheath was useful during laser fiber pullback under US guidance and was used to aid the passage of the bare-tipped laser fiber inside A 4-Fr guide catheter over the wire. The distal tip of the laser fiber was positioned 2–3 cm below SFJ, before inserting the laser fiber and catheter into the vein, the optimal laser fiber length was determined outside the body, the laser fiber was introduced into the catheter and positioned so as to protrude 2.5 cm from the distal end of the catheter, the stopper at the proximal end of the catheter was firmly tightened onto the fiber, and the fiber (with properly positioned and secured stopper) was removed from the catheter; this step ensures that the fiber protrudes correctly from the catheter inside the vein. The laser fiber tip was positioned caudal to the SFJ just caudal to the epigastric vein before activation to minimize the risk of developed thrombosis (DVT) or injury to the central veins [22].

Once the device is appropriately placed for ablation, the patient is placed in Trendelenburg position to facilitate vein emptying and perivenous tumescent anesthesia that was administered along the entire length of the GSV, as described before. After tumescent anesthetic had been administered, the entire course of the GSV was evaluated with US to confirm that it was completely surrounded by anesthetic fluid at all levels but was not occluded completely, as it is desirable and necessary with laser treatment to maintain a small volume of blood within the lumen of the vein, as blood is the chromophore for the

absorption of the laser energy to transfer heat to the vein wall and cause injury to the vein wall. Next, correct positioning of the laser fiber tip was again verified and adjusted as necessary. The catheter fiber was then energized in a continuous manner and was slowly withdrawn in wide sections of the vein at a velocity of 1 mm/s and faster in narrow sections at a velocity of 3 mm/s under US guidance until it reaches a distance of 2/2.5 cm from the puncture site of GSV; this is done with manual pressure, which assists vein wall apposition. The pullback rate is monitored by assessing the calibrated marks on the sheath. The rate of pullback was adjusted to maintain an energy transfer of 60–90 J/cm² at 12–14 W within the vein. The linear endovenous energy density values were used to calculate the laser energy based on the GSV diameter 1.5–2 cm distal to SFJ. For GSV diameters between 4.5 and 6.9 mm 60/70 J/cm² of energy was used and for GSV diameter between 7 and 10 mm 80/90 J/cm² energy was used [23].

After the catheter or fiber has been withdrawn to the venotomy site, the saphenous vein is again evaluated with US. Typically, one identifies vessel wall thickening, concentric narrowing, and absence of flow, indicating a successful endovenous saphenous vein obliteration procedure. The common femoral vein is also evaluated for compressibility and the absence of thrombus. The laser unit was turned off and sheath and laser fiber was then removed and hemostasis was obtained with manual compression over the access site. Simultaneously, the leg is elevated to achieve 90° hip flexion. Thigh and knee were wrapped with an elastic compression bandage for 3 days, and then thigh high class II graduated compression stocking was applied for 2 weeks to facilitate GSV closure and minimize post-procedure bruising [24,25].

Postintervention follow-up

PO pain was assisted for both groups by using The '0–10 Numeric Pain Rating Scale' and relating doses of analgesic drug. The patient was asked to make three pain ratings, corresponding to current, best, and worst pain experienced over the past 24 h. The average of the 3 ratings was used to represent the patient's level of pain over the previous 24 h (0=no pain, 1–3=mild pain, 4–6=moderate pain, and 7–10=severe pain).

Patients were discharged 1–3 days PO. Both groups were followed up for 1 week for bleeding, hematoma in the subcutaneous tissue along the stripped vein or in the groin, bruising and ecchymosis, wound infection, nerve injury (manifesting as numbness, decreased, or altered

sensation or paresthesia), superficial thrombophlebitis, DVT, and skin burn, and at 3 and 6 months for skin discoloration or pigmentation, residual varicosities, scarring and recanalization to assess PO outcome. Duplex US examination was performed to confirm a successful obliteration procedure and to rule out any potential DVT or extension of thrombus from the saphenous vein into the femoral vein especially in group B. Bruising was assessed in the thigh along the stripping or ablation line and not in the calf where any bruising would be related to the avulsions (Fig. 1a–f).

Statistical analysis

Analysis of data was done by using statistical package for the social sciences version 16 (SPSS; SPSS Inc., Chicago, Illinois, USA). Quantitative data were presented as mean and SD and were analyzed by using one-way unpaired *t*-test to compare quantitative variables, in parametric data (SD<50% mean). Qualitative data were presented as numbers and percentages and were analyzed by using χ^2 and Fisher's exact tests. *P*-value less than 0.05 was considered significant, whereas *P*-value less than 0.01 was considered highly significant. However, *P*-value greater than 0.05 was considered insignificant.

These data are shown in Fig. 1a–f.

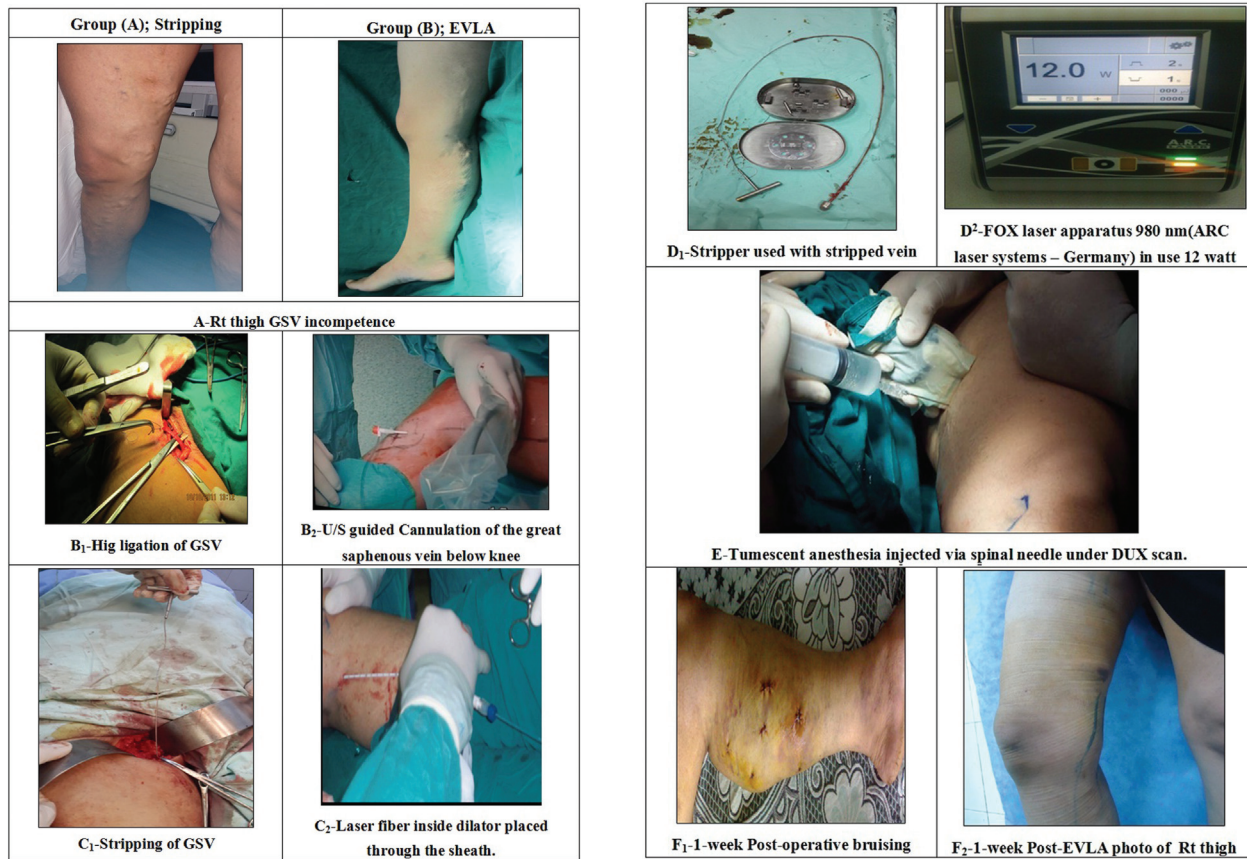
Results

This prospective study included 44 patients with duplex US features of GSV reflux more than 1 s along its whole length, who were divided into two groups according to the intervention performed – group A: conventional surgical stripping of GSV [22 (50%)], and group B: EVLA [22 (50%)]. The age of studied cases ranged from 24 to 59 years; mean age in group A was 32.6 years and in the group B it was 34.2 years. There were 13 female patients and nine male patients in group A, whereas in group B there were 14 female and eight male patients. There was no statistical difference between both groups in demographic data (Table 1 and Figure 2).

The presenting symptoms of GSV reflux were pain [44 (100%)], visible varicose vein [42 (95.4%)], night cramps [two (4.5%)], restless leg [38 (86.4%)], bleeding [four (9.1%)], and skin discoloration [eight (18.2%)] (Table 2 and Figure 3).

As regards the type of anesthesia used in this study in the surgical group spinal and general anesthesia were used in 15 (68.1%) and five (22.7%) patients, respectively, and tumescent anesthesia combined

Figure 1



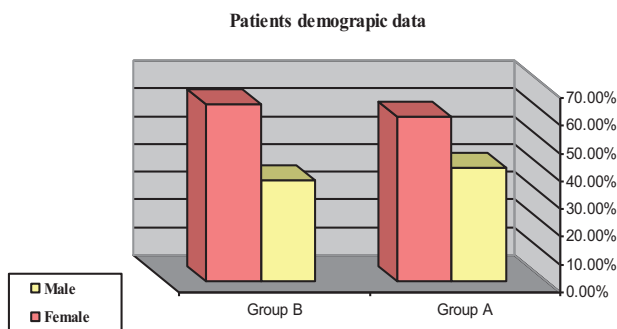
Steps of great saphenous vein stripping and endovenous laser ablation for right lower limb great saphenous vein incompetence. EVLA, endovenous laser ablation; GSV, great saphenous vein; US, ultrasound

Table 1 Patients' demographic data

Variables	Group A [22 (50%)]	Group B [22 (50%)]	P-value
Age (years)	32.6±3	34.2±2.5	0.44 (NS)
Sex			
Male	9 (40.9)	8 (36.4)	0.23 (NS)
Female	13 (59.1)	14 (63.6)	

Data are presented as numbers and mean±SD; percentages and ranges are given in parentheses.

Figure 2



Patients' demographic data

with spinal or general anesthesia was tried in two (9.2%) cases, whereas in the EVLA group tumescent anesthesia was used in all cases (100%) besides general

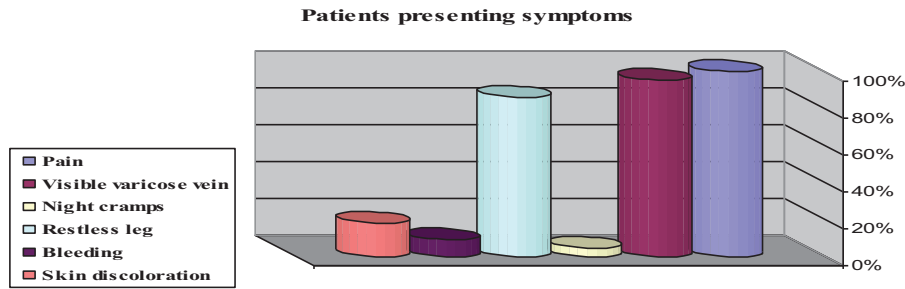
Table 2 Patients' presenting symptoms

Variables	Findings
Presenting symptoms [n (%)]	
Pain	44 (100)
Visible varicose vein	42 (95.4)
Night cramps	2 (4.5)
Restless leg	38 (86.4)
Bleeding	4 (9.1)
Skin discoloration	8 (18.2)
Duration of symptoms [mean±SD (range) (years)]	1.6±0.2 (0.5–3)

Data are presented as numbers and mean±SD; percentages and ranges are given in parentheses.

or spinal anesthesia. There was a statistically significant difference between both groups; a P-value of 0.001 was considered highly significant (Table 3 and Figure 4).

Figure 3



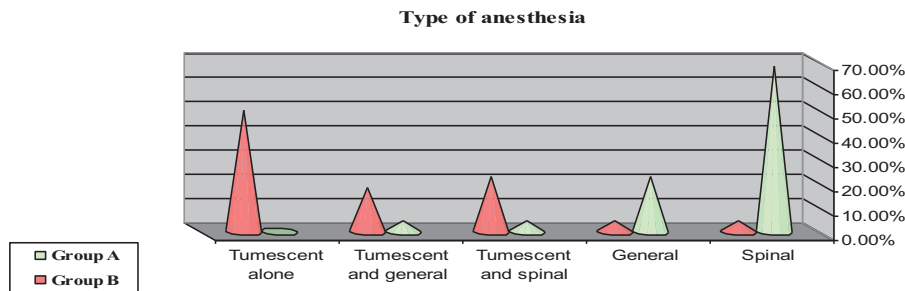
Patients' presenting symptoms

Table 3 Types of anesthesia

Variables	Group A [22 (50)]	Group B [22 (50)]	χ^2	P-value
Spinal	15 (68.1)	0	25	0.001 (HS)
General	5 (22.7)	0		
Tumescent and spinal	1 (4.6)	6 (27.3)		
Tumescent and general	1 (4.6)	5 (22.7)		
Tumescent alone	0	11 (50)		

Data are presented as percentages and by using χ^2 -test. HS, highly significant.

Figure 4



Type of anesthesia

All patients passed uneventful intraoperative course without complications, except one case with femoral vein injury and bleeding. Mean operative time was 76.8 ±4, ranging from 60 to 91 min, in group A and 69.1±3, ranging from 53 to 79 min, in group B. Mean intraoperative blood loss was 56±5.5, ranging from 50 to 60 ml, in group A and 47.2±5.1, ranging from 40–50 ml, in group B. Patients in group A were discharged 1–3 days PO, but patients in group B were discharged 1–2 days PO (Table 4 and Figure 5).

Upon review of the results in this study, PO pain was assisted for both groups by using the (0–10) Numeric Pain Rating Scale and relating doses of analgesic drugs; a highly significant difference between both groups was noticed: in group A the average dose was 12.3±1.9 and pain rate was 6.05±1.099 and in group B the average dose was 5.4±2.1 and pain rate was 4.05 ±1.23, with $t=10.9$ and $t=4.5$, respectively, and a P-value of 0.001; surgical stripping had moderate to

severe pain and received more analgesic drugs than EVLA patients who had mild to moderate pain (Table 5 and Figure 6).

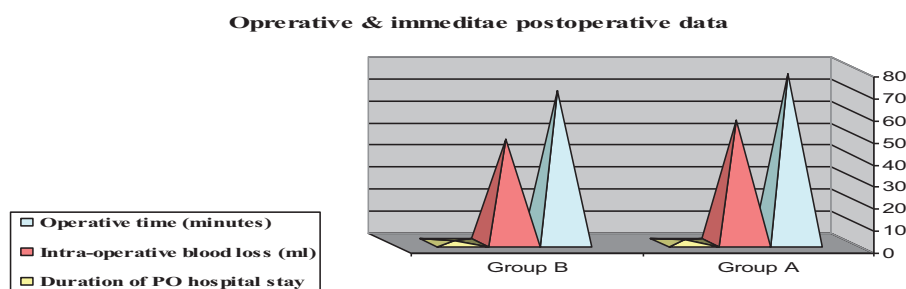
No mortality was recorded, but two patients did not come for follow-up, and data collection was applied on 42/44 patients only, 21/22 in each group. At 1 week PO, in group A, there was bleeding due to femoral vein injury at the SFJ during surgery, which was due to slipped ligature by retractor and discovered intraoperatively in one (4.76%) case, and the vein was repaired by continuous prolene 6/0; hematoma was noticed in the subcutaneous tissue along the stripped vein and in the groin in six (28.57%) cases; bruising and ecchymosis in seven (33.33%) cases; and wound infection and nerve injury in two (9.52%) cases (but there were no superficial thrombophlebitis, DVT or skin burn). In group B, there were complications limited to bruising and ecchymosis in five (23.8%) cases, superficial thrombophlebitis in three (14.28%)

Table 4 Operative and immediate postoperative data

Variables	Group A [22 (50)]	Group B [22 (50)]	t	P-value
Operative time (min)				
Mean±SD	76.8±4	69.1±3	3.5	0.000 (HS)
Range	60–91	53–79		
Intraoperative blood loss (ml)				
Mean±SD	56±5.5	47.2±5.1	8	0.001 (HS)
Range	50–60	40–50		
Duration of postoperative hospital stay (days)				
Mean±SD	1.8±0.5	1.2±0.4	4.1	0.001 (HS)
Range	1–3	1–2		

Data are presented as numbers and mean±SD; ranges are in parentheses and statistically significant difference by using unpaired t-test. HS, highly significant.

Figure 5



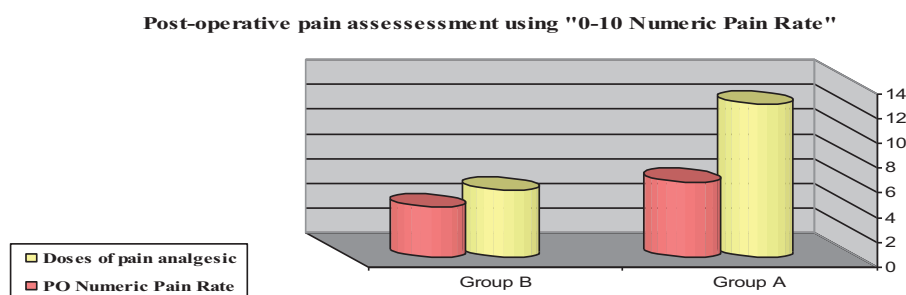
Operative and immediate postoperative data. PO, postoperative

Table 5 Postoperative pain assessment using '0–10 Numeric Pain Rate'

Variables	Group A [22 (50)]	Group B [22 (50)]	t	P-value
Doses of pain analgesic (mean±SD)	12.3±1.9	5.4±2.1	10.9	0.001 (HS)
Postoperative numeric pain rate (mean±SD)	6.05±1.099	4.05±1.23	5.4	0.001 (HS)

Data are presented as numbers and mean±SD; ranges are in parentheses and statistically significant difference by using unpaired t-test. HS, highly significant.

Figure 6



Postoperative pain assessment using '0–10 Numeric Pain Rate'. PO, postoperative

cases, DVT in two (9.52%) cases, or skin burn in one (4.76%) case. Residual varicosities that appeared in both groups were treated by foam sclerotherapy (Table 6 and Figure 7).

As regards returning back to normal activity, the mean time to return to normal activity in the surgical group was 8.5±2.4, which is higher than in the EVLA group, in which the mean time to return to normal activity was

5.8±1.5; therefore, there is a statistically significant difference between both groups (P=0.001) (Table 7 and Figure 8).

At the 3- and 6-month PO follow-up, there was skin discoloration (pigmentation) noticed in seven (33.33%) cases of group A and in only in one (4.76%) case of group B. Scarring was noticed only in group A in six (28.57%) cases and recurrence (recanalization) was

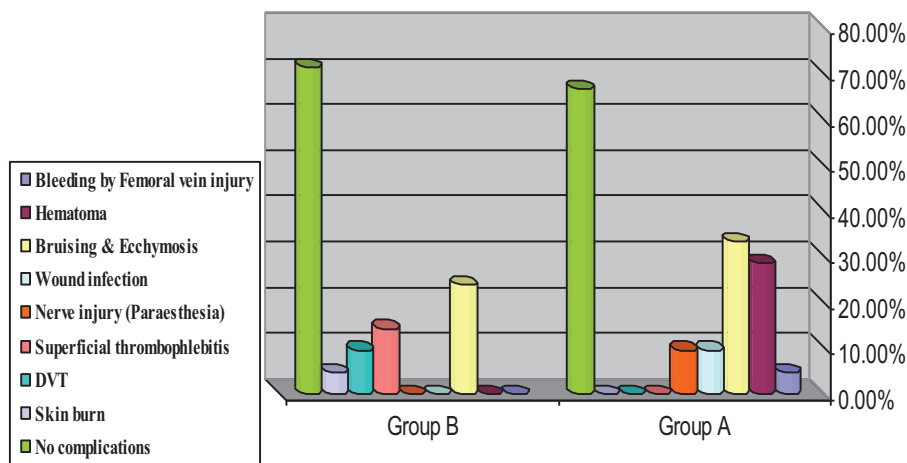
Table 6 Distribution of postoperative 1-week complications

Variables	Group A [21 (50)]	Group B [21 (50)]	χ^2	P-value
Bleeding by femoral vein injury	1 (4.76)	0	23	0.01 (significant)
Hematoma	6 (28.57)	0		
Bruising and ecchymosis	7 (33.33)	5 (23.8)		
Wound infection	2 (9.52)	0		
Nerve injury (paresthesia)	2 (9.52)	0		
Superficial thrombophlebitis	0	3 (14.28)		
DVT	0	2 (9.52)		
Skin burn	0	1 (4.76)		
No complications	14 (66.66)	15 (71.42)		

Data are presented as percentages and by using χ^2 -test. DVT, developed thrombosis.

Figure 7

Distribution of post-operative 1-week complications



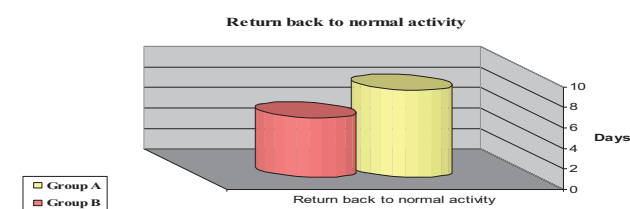
Distribution of postoperative 1-week complications. DVT, developed thrombosis

Table 7 Return back to normal activity

Variables	Group A [21 (50)]	Group B [21 (50)]	t	P-value
Mean \pm SD	8.5 \pm 2.4	5.8 \pm 1.5	5.2	0.001 (HS)
Range	7–14	4–7		

Data are presented as numbers and mean \pm SD; ranges are in parenthesis and statistically significant difference by using unpaired t-test. HS, highly significant.

Figure 8



Return back to normal activity

noticed only in group B in two (9.52%) cases. The overall results were better in group B: 19 (90.47%) (Table 8 and Figure 9).

Discussion

Vein stripping and high ligation has been the standard of care for superficial venous insufficiency for many decades. Efficacy assessment of stripping and ligation was often performed by using varicose vein recurrence as the primary end point. Because of the wide availability of duplex US scanning has the significance of recurrent reflux been recognized. The prevalence of recurrent reflux increases over time, with a 28.8% incidence at 5 years and 60% at a mean follow-up of 34 years [26].

During the past decade, new less invasive methods have been developed as alternatives to conventional high ligation/excision (HL/S) in the treatment of GSV incompetence, including radiofrequency ablation, EVLA, and foam sclerotherapy. In the not so distant past, physicians did not perceive venous disease as a serious health risk. Typically, a patient would be treated with extremity elevation and compression for long periods, remaining severely debilitated [6].

This study was on the utilization of 'FOX' 980 nm diode laser system EVLA in the treatment of primary varicose veins group B compared with the stripping group A, which included 44 patients, and the mean follow-up period was 6 months, as regards the EVLA group (group B) that included 22 patients; this was smaller than recent studies conducted by Shi *et al.* [3], who studied 132 patients (156 limbs) with EVLA among a total of 311 patients (376 limbs) for a duration of 12 months, and Brittenden *et al.* [9], who treated 212 out of 798 patients in a long-term follow-up of 5 years duration.

The presenting symptoms of GSV reflux were pain [44 (100%)], visible varicose vein [42 (95.4%)], night cramps [two (4.5%)], restless leg [38 (86.4%)], bleeding [four (9.1%)], and skin discoloration [eight (18.2%)]. This was comparable to the study by Campbell *et al.* [27], who conducted a study on 151 limbs of 100 patients; the main presenting symptom was aching pain, which was present in 97 (64%) limbs, and the other symptoms included skin changes in 40 (26%) limbs, disfigurement in 32 (21%) limbs, heaviness in 18 (12%) limbs, phlebitis in 10 (7%) limbs, and bleeding in one (7%) limb. It is noteworthy that many patients reported more than one main symptom, and thus the total percentage exceeds 100% [27].

In this study, tumescent local anesthetic solution was used in all cases (100%) besides general or spinal anesthesia in group B and tried in combination with

spinal or general anesthesia in two cases of group A. This technique provided excellent anesthesia and allowed, in group A, vein stripping to be performed under straight local anesthesia. In addition, the vasoconstriction from the epinephrine and the direct compressive effects of the instilled volume resulted in rapid hemostasis from the avulsed tributaries and a marked decrease in PO ecchymosis and pain and allowed, in group B, separation of the superficial aspect of the GSV by at least 1.0 cm deep to the skin surface along its entire length to reduce the likelihood of skin burns and collapse of GSV to improve the transfer of thermal energy to the vein wall, and the vasoconstriction from the epinephrine reduced incidence of hematoma and hyperpigmentation. The ability to perform the procedure under tumescent local anesthesia allows for an immediate return to daily activities with optimal medical and cosmetic results, as well as high patient satisfaction [14,15].

In the present study, mean operative time was 76.8±4, ranging from 60 to 91 min, in group A and 69.1±3, ranging from 53 to 79 min, in group B. This is in contrast to the study by De Maeseneer *et al.* [28], who mentioned that the total theater time (between entry into and exit from the theater suite) was significantly longer for EVLA than for conventional surgery, owing to time consumed during marking the course of the GSV under duplex guidance in EVLA.

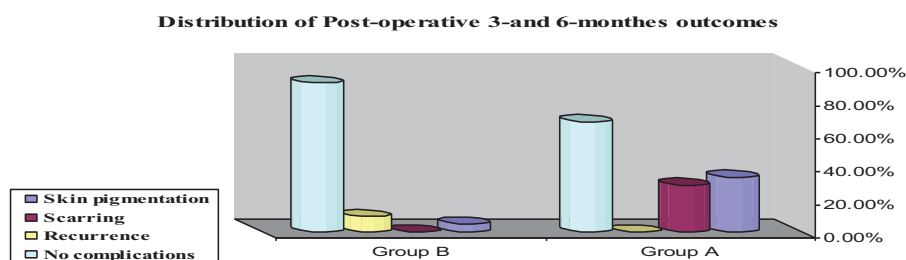
Upon review of the results in this study regarding PO pain, surgical stripping patients had moderate to severe pain and received more doses of analgesic drugs than EVLA patients who had mild to moderate pain - *P*-value of 0.001—and in EVLA patients there were no multiple skin incisions. Sharif and colleagues had reported that pain felt by patients occurred 5–8 days after the procedure and was related to the inflammation resulting from successful endovenous ablation but not related to ecchymosis nor damage to perivenous tissue [28,29].

Table 8 Distribution of postoperative 3- and 6-month outcomes

Variables	Group A [21 (50)]	Group B [21 (50)]	χ^2	<i>P</i> -value
Skin pigmentation	7 (33.33)	1 (4.76)	26	0.001 (HS)
Scarring	6 (28.57)	0		
Recurrence	0	2 (9.52)		
No complications	14 (66.66)	19 (90.47)		

Data are presented as percentages and by using χ^2 -test. HS, highly significant.

Figure 9



Distribution of postoperative 3- and 6-month outcomes

At 1 week PO, in group A, there was bleeding due to femoral vein injury during surgery in one (4.76%) case and the vein was repaired by prolene 6/0; hematoma was noticed in the subcutaneous tissue along the stripped vein and in the groin in six (28.57%) cases; bruising and ecchymosis in seven (33.33%) cases; and wound infection (due to skin incision) and nerve injury (especially in cases with reflux of GSV >15 cm below knee stripping) in two (9.52%) cases (but there was no superficial thrombophlebitis, DVT, or skin burn) [28]. In group B, there were complications limited to bruising (occurred at the sites where the tumescent anesthesia has been instilled) and ecchymosis (most likely caused by laser-induced perforation of the vein wall, could be observed in every patient at the inner thigh and knee region from the next day to ~2 weeks later) in five (23.8%) cases, which improved spontaneously in the follow-up. There were three (14.28%) cases of superficial thrombophlebitis in the form of skin redness (topical anti-inflammatory was prescribed and rapid improvement was noticed in one case in the follow-up for this phlebitis) and the other two (9.52%) cases DVT, which was due to extension from superficial thrombophlebitis: in one case it was because of late ambulation and in the other case it was because the laser fiber was too close to the deep vein; these two cases were managed conservatively without sequelae or skin burn (most probably from inadequate administration of tumescent anesthesia), in one (4.76%) case. This was similar to Proebstle *et al.* [25] and Gibson *et al.* [30].

The mean time to return to normal activity in the surgical group was 8.5 days; this is higher than in the EVLA group, in which the mean time to return to normal activity was 5.8 days. Similar results were mentioned by De Maeseneer *et al.* [28], who reported that patients returned to their full level of normal household activities for driving and for work significantly more quickly after EVLA than after conventional surgery.

At the 3- and 6-month PO follow-up, there was skin discoloration (pigmentation) noticed in seven (33.33%) cases of group A and in only in one (4.76%) case of group B because the thrombotically occluded GSV was still present. Scarring was noticed only in group A because of skin incision, six (28.57%) cases, and recurrence (recanalization) was noticed only in group B, two (9.52%) cases. Recurrence of reflux at the SFJ is often blamed on operator failure during the first intervention, but it cannot always be explained by such technical inadequacy. Its development can be attributed to neovascularization in the granulation

tissue around the ligated saphenous stump, as mentioned by Proebstle and colleagues [25,28].

The overall results were better in group B, 19 (90.47%), which is similar to promising results published by Shi *et al.* [3], as the technical success rate of EVLA was 100% in their evaluation of the Effect of EVLA of incompetent GSV in patients with primary venous disease.

Conclusion

EVLA of GSV, being simple to perform and well accepted by patients, is a safe and effective method with low rate of complications, requires one day of hospitalization, short recovery time, and quick return to professional activities. Therefore, this method is a very promising technique especially in female patients for cosmetic reason as compared with surgical stripping.

Acknowledgement

Author acknowledge Prof, Dr. Atef Abd-Elghani Youssef.

Financial support and sponsorship

Nil.

Conflicts of interest

There are no conflicts of interest.

References

- 1 Darwood R, Theivacumar N, Dellagrammatic D, Gough M. Randomized clinical trial comparing endovascular laser ablation with surgery for the treatment of primary great saphenous vein. *Br J Surg* 2008; 95:294–301.
- 2 Cook TA, Michael JA, Gallan RB. Varicose vein clinics: modeling effects of seasonal variation in referrals. *J R Coll Surg Edinb* 2003; 42:400–402.
- 3 Shi H, Liu X, Lu M, Jiang M, Yin M. Effect of endovenous laser ablation of incompetent perforating veins and the great saphenous vein in patients with primary venous disease. *Eur J Vasc Endovasc Surg* 2015; 49:574–580.
- 4 Alberto Caggiati C. The venous valves of lower limbs. *Phlebology* 2013; 20:87–95.
- 5 MacKenzie RK, Paisley AA, Allan PL. The effect of long saphenous vein stripping on quality of life. *J Vasc Surg* 2002; 35:1197–1203.
- 6 Perkowski P, Ravi R, Gowda R, Rodriguez-Lopez J. Endovenous laser ablation of the saphenous vein for treatment of venous insufficiency and varicose veins: early results from a large single-center experience. *J Endovasc Ther* 2004; 11:132–138.
- 7 Neumann HM, Van Gemert MC. Ins and outs of the endovenous laser ablation: afterthoughts. *Lasers Med Sci* 2014; 29:513–518.
- 8 Heger MV, Golen RF, Broekgaarden MR, van den Bos RR, Neumann HM, Van Gemert MC. The role of thermal coagula, thrombosis, cell death, and vascular wall damage in the removal of varicose veins following endovenous laser therapy. *Lasers Med Sci* 2014; 29:513–518.
- 9 Brittenden J, Cotton S, Elders A, Tassie E, Scotland G. Clinical effectiveness and cost-effectiveness of foam sclerotherapy, endovenous laser ablation and surgery for varicose veins: results from the comparison of LASER, surgery and foam sclerotherapy (CLASS) randomised controlled trial. *Health Technol Assess* 2015; 19:1–342.
- 10 Min R, Khilnani N, Zimmet S. Endovenous laser treatment of saphenous vein reflux: long term results. *J Vasc Interv Radiol* 2003; 14:991–996.
- 11 Navarro L, Min R, Boné C. Endovenous laser: a new minimally invasive method of treatment for varicose veins-preliminary observations using an 810 nm diode laser. *Dermatol Surg* 2002; 27:117–122.

- 12 Min RJ, Khilnani NM. Endovenous laser ablation of varicose veins. *J Cardiovasc Surg (Torino)* 2005; 46:395–405.
- 13 Rasmussen H, Bjoern L, Lawetz M. Randomized trial comparing endovenous laser ablation of great saphenous vein with high ligation and stripping in patients with varicose vein: short term results. *J Vasc Surg* 2004; 39:88–94.
- 14 Mark DI, Thomas FO, O'Donnell JR. Varicose veins: surgical treatment. In: Jack LC, Wayne KJ. *Rutherford's vascular surgery*. Vol. 1 (57), 8th ed. China; 2014. pp. 869–884.
- 15 Disselhoff BC, der Kinderen DJ, Kelder JC, Moll FL. Five-year results of a randomized clinical trial comparing endovenous laser ablation with cryostripping for great saphenous varicose veins. *Br J Surg* 2011; 98:1107–1111.
- 16 Michaels J, Brazier J, Campbell W, MacIntyre J, Palfreyman S, Ratcliffe J. Randomized clinical trial comparing surgery with conservative treatment for uncomplicated varicose veins. *Br J Surg* 2006; 93:175–181.
- 17 Kalteis M, Berger I, Messie-Werndl S, Pistrich R, Schimetta W, Pölz W. High ligation combined with stripping and endovenous laser ablation of the great saphenous vein: early results of a randomized controlled study. *J Vasc Surg* 2008; 47:822–829.
- 18 Kostas T, Ioannou CV, Touloupakis E, Daskalaki E, Giannoukas AD, Tsetis D, Katsamouris AN. The appropriate length of great saphenous vein stripping should be based on the extent of reflux and not on the intent to avoid saphenous nerve injury. *J Vasc Surg* 2007; 46:1234–1241.
- 19 Gloviczki P, Jeffrey MR, Delis KT, Wennberg PW, Rooke TW, Driscoll DJ. The care of patients with varicose veins and associated chronic venous diseases: clinical practice guidelines of the Society for Vascular Surgery and the American Venous Forum. *J Vasc Surg* 2011; 53:2s–48s.
- 20 Nedzad R, Alemko C, Alija A. Outcome of endovenous laser ablation of varicose veins. *Acta Inform Med* 2014; 22:329–332.
- 21 Theivacumar NS, Gough MG. Endovenous laser ablation (EVLA) to treat recurrent varicose veins. *Eur J Vasc Endovasc Surg* 2011; 41:691–696.
- 22 Timperman P, Sichlau M, Ryu R. Greater energy delivery improves treatment success of endovenous laser treatment of incompetent saphenous veins. *J Vasc Interv Radiol* 2004; 15:1061–1063.
- 23 Pronk P, Gauw S, Gaastra M, Lawson J, van Goethem A. Randomised controlled trial comparing sapheno-femoral ligation and stripping of the GSV with endovenous laser ablation (980 nm) using local tumescent anesthesia: one year results. *Eur J Vasc Endovasc Surg* 2010; 40: 649–656.
- 24 Proebstle T, Gul D, Lehr H, Kargl A, Knop J. Infrequent early recanalization of greater saphenous vein after endovenous laser treatment. *J Vasc Surg* 2003; 38:511–516.
- 25 Proebstle T, Krummenauer F, Gul D, Knop J. Non-occlusion and early reopening of the great saphenous vein after endovenous laser treatment is fluence dependent. *Dermatol Surg* 2004; 30:174–178.
- 26 Fischer R, Linde N, Duff C, Jeanneret C, Chandler J, Seeber P. Late recurrent saphenofemoral junction reflux after ligation and stripping of the greater saphenous vein. *J Vasc Surg* 2001; 34:236–240.
- 27 Campbell WB, Vijay Kumar AS, Collin TW, Allington KL, Michaels JA. The outcome of varicose vein surgery at 10 years: clinical findings, symptoms and patient satisfaction. *Ann R Coll Surg Engl* 2003; 85:52–57.
- 28 De Maeseneer MG, van Schil PE, Philippe MM, Vanmaele RG, Eyskens EJ. Is recurrence of varicose veins after surgery unavailable. *Acta Chir Belg* 2006; 95:21–26.
- 29 Sharif MA, Soong CV, Lau LL, Hannon RJ. Endovenous laser treatment for long saphenous vein incompetence. *Br J Surg* 2006; 93:831–835.
- 30 Gibson KD, Ferris BL, Neradilek BW, Pepper DA. Endovenous laser treatment of the small saphenous vein: efficacy and complications. *J Vasc Surg* 2007; 45:795–803.